

# Gastritides: Diagnostic Evaluation of Multifaceted Conditions

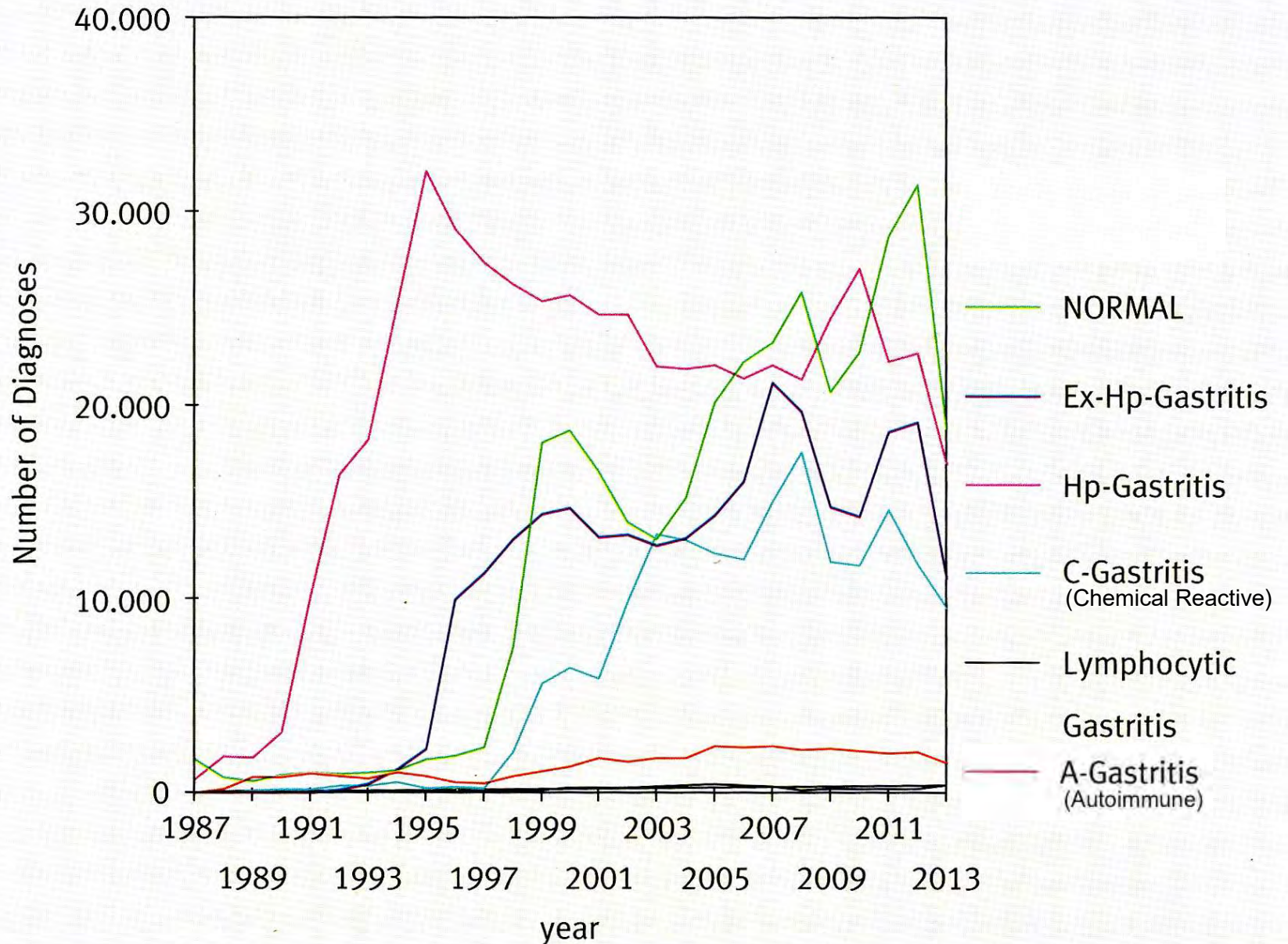
**Gregory Y. Lauwers, MD**

*Senior Member*

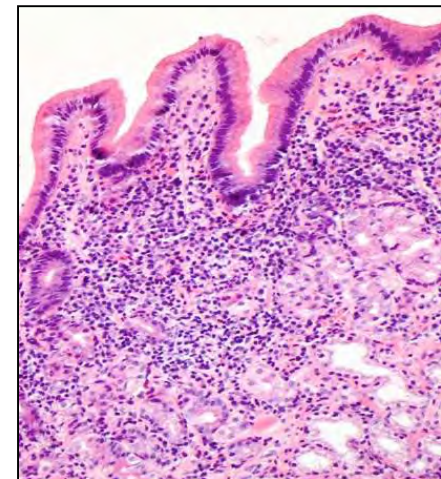
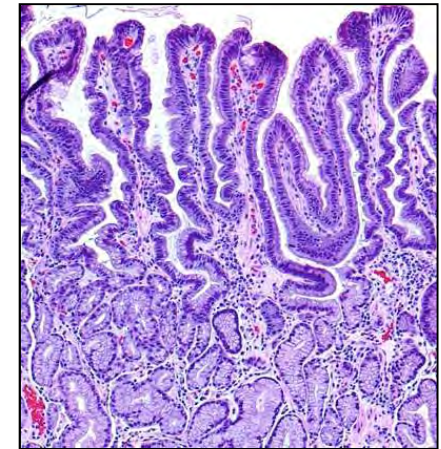
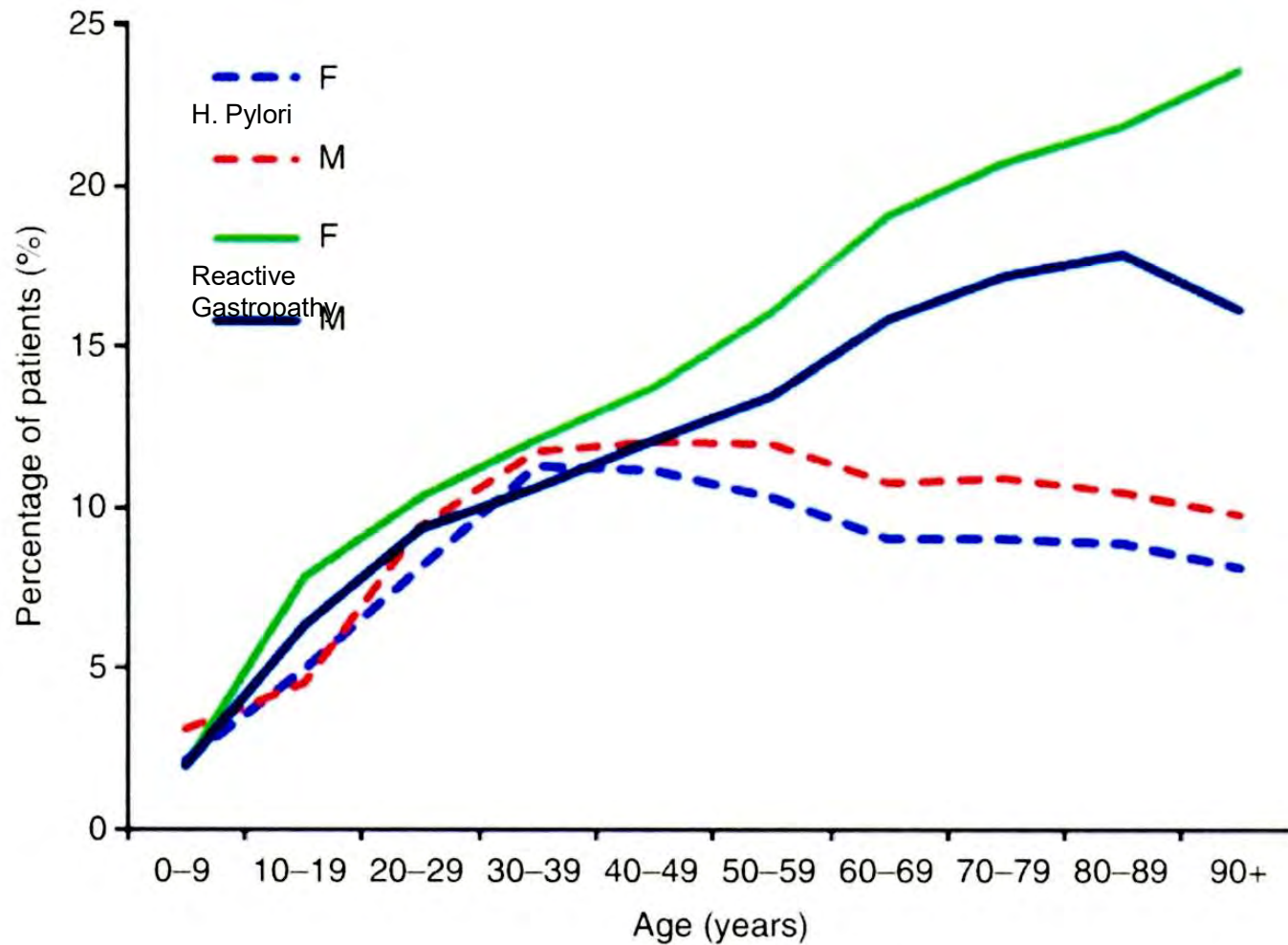
*H. Lee Moffitt Cancer Center & Research Institute  
Tampa, FL*

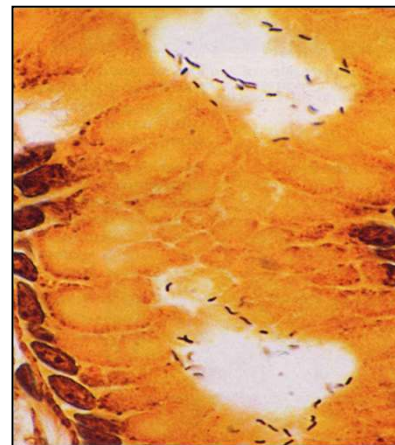
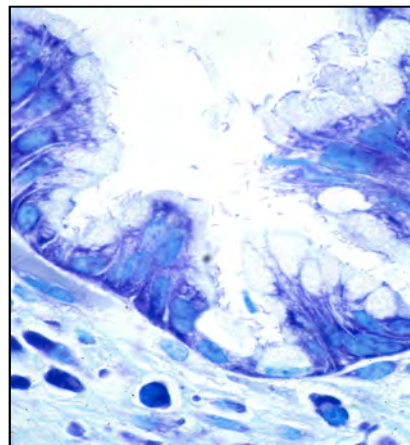
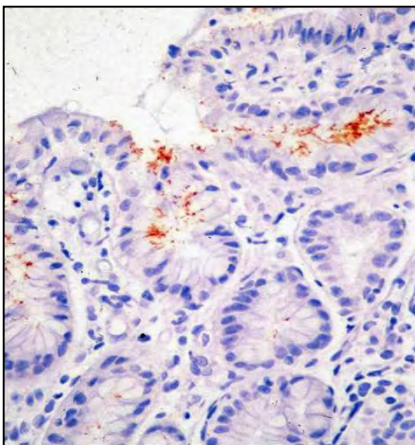
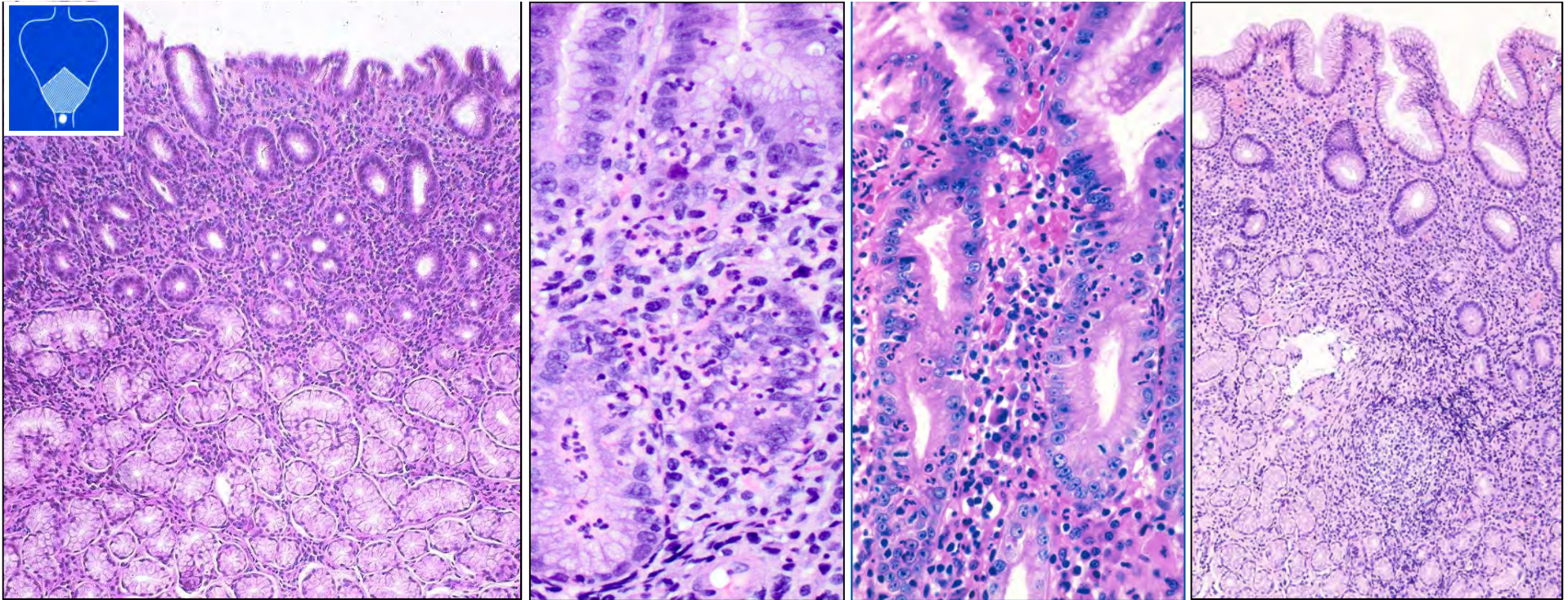
***[gregory.lauwers@moffitt.org](mailto:gregory.lauwers@moffitt.org)***

# Changing epidemiology of gastritis



# Prevalence of Reactive Gastropathy and *H. Pylori* Gastritis



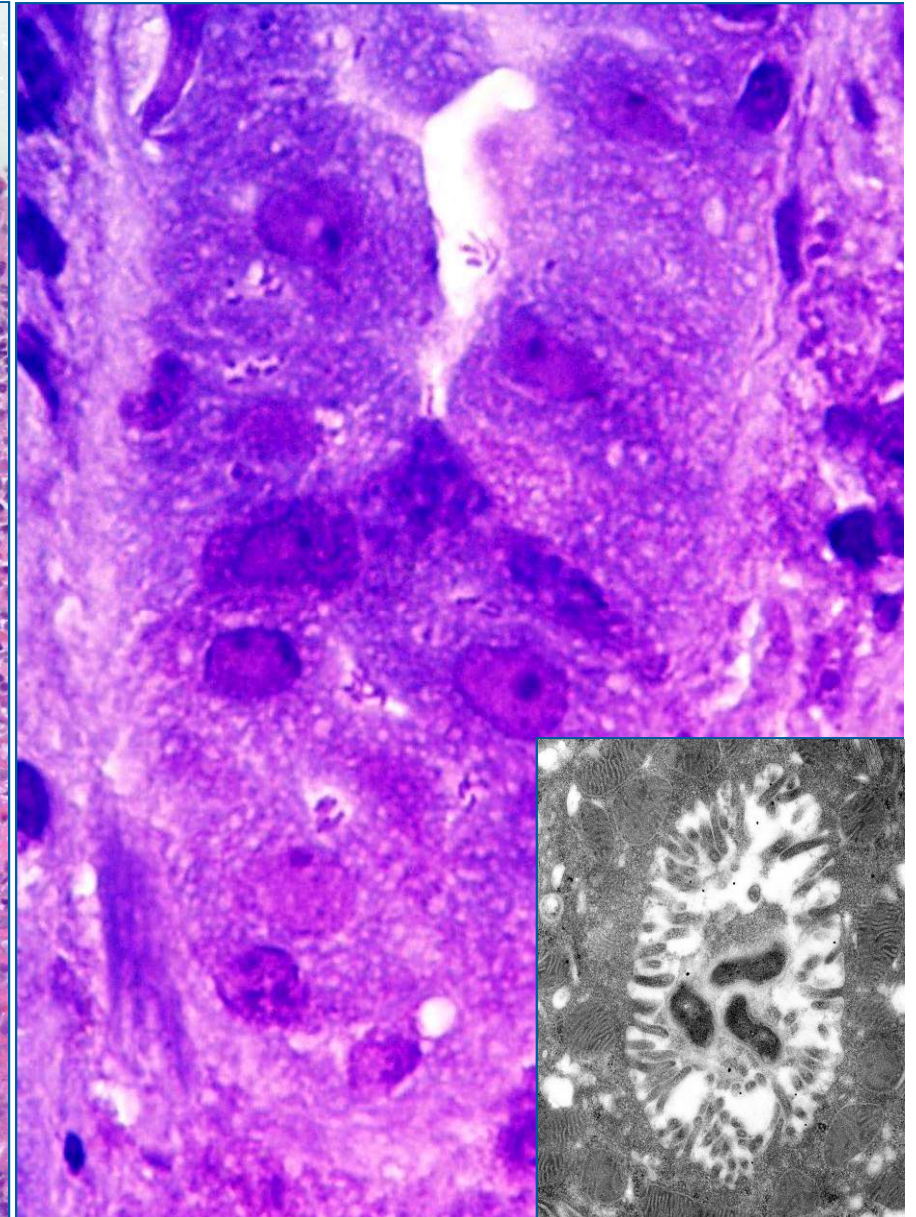
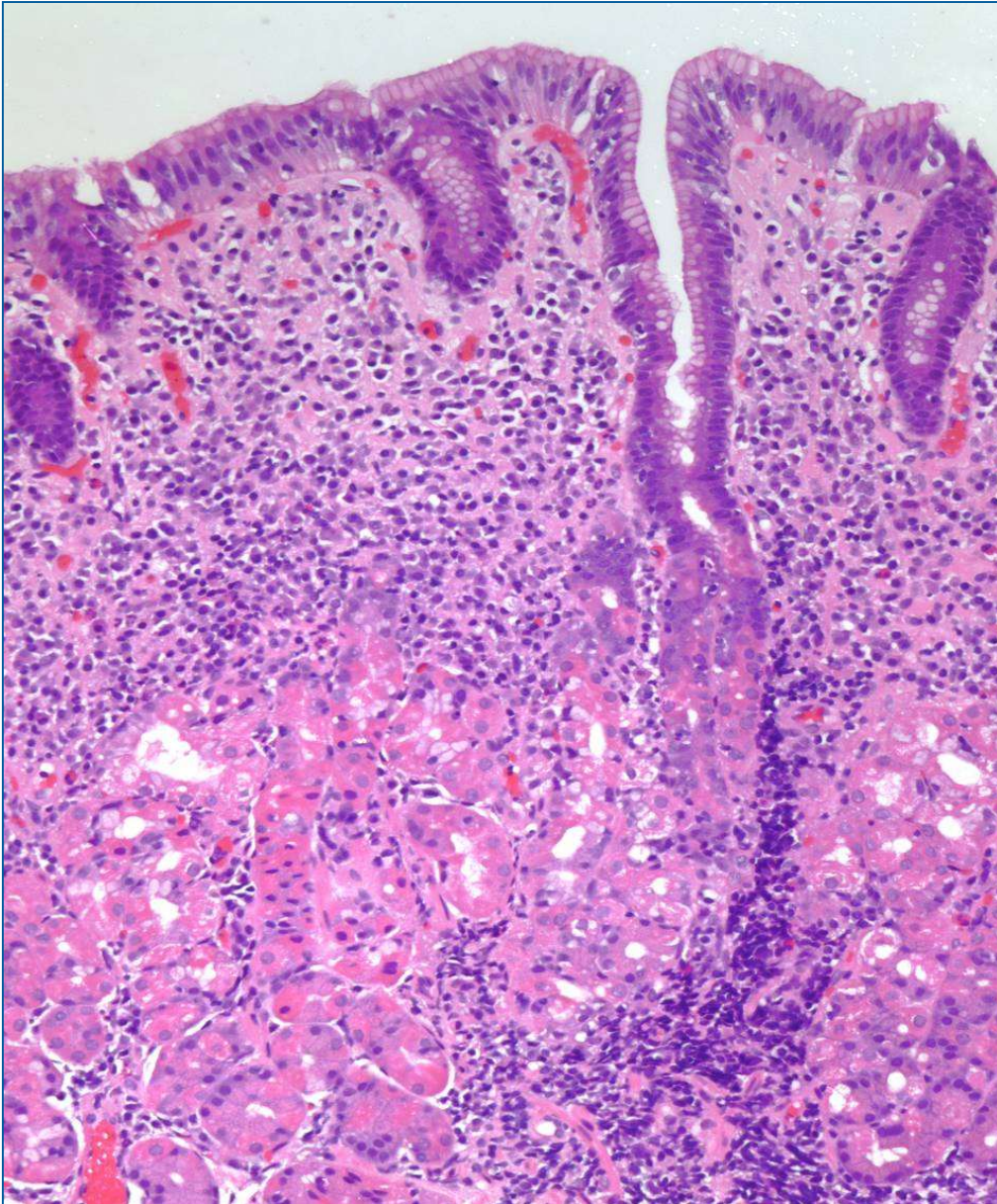


- Urease activity:
  - ① Biopsies (CLO-test)
  - ② breath test
- Serology
- Stool antigen

## IF NEGATIVE

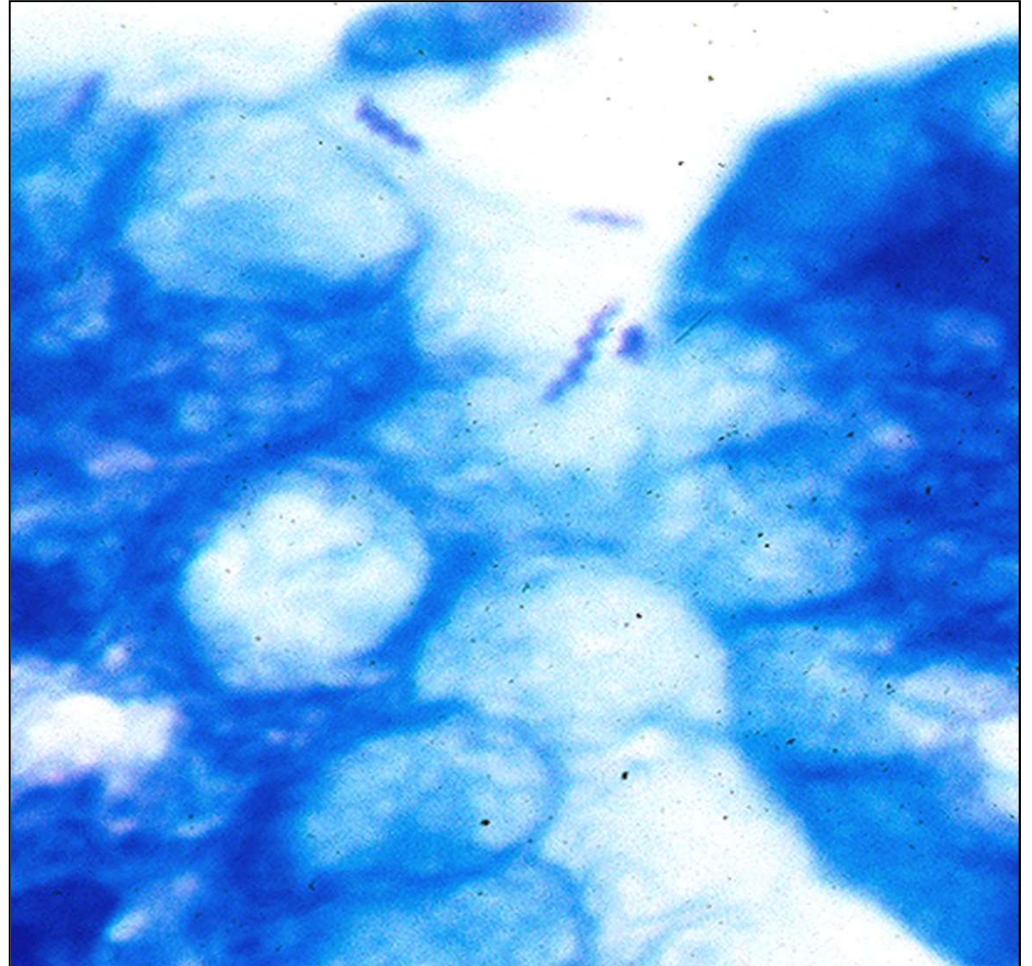
- **Sampling error** -- **Antibiotic monotherapy** (e.g., other infections)
- **PPI** (decreased # of bacteria; shift from antrum to prox. stomach)
- **Focally Enhanced Gastritis** (IBD)

# Treated *H. pylori* gastritis

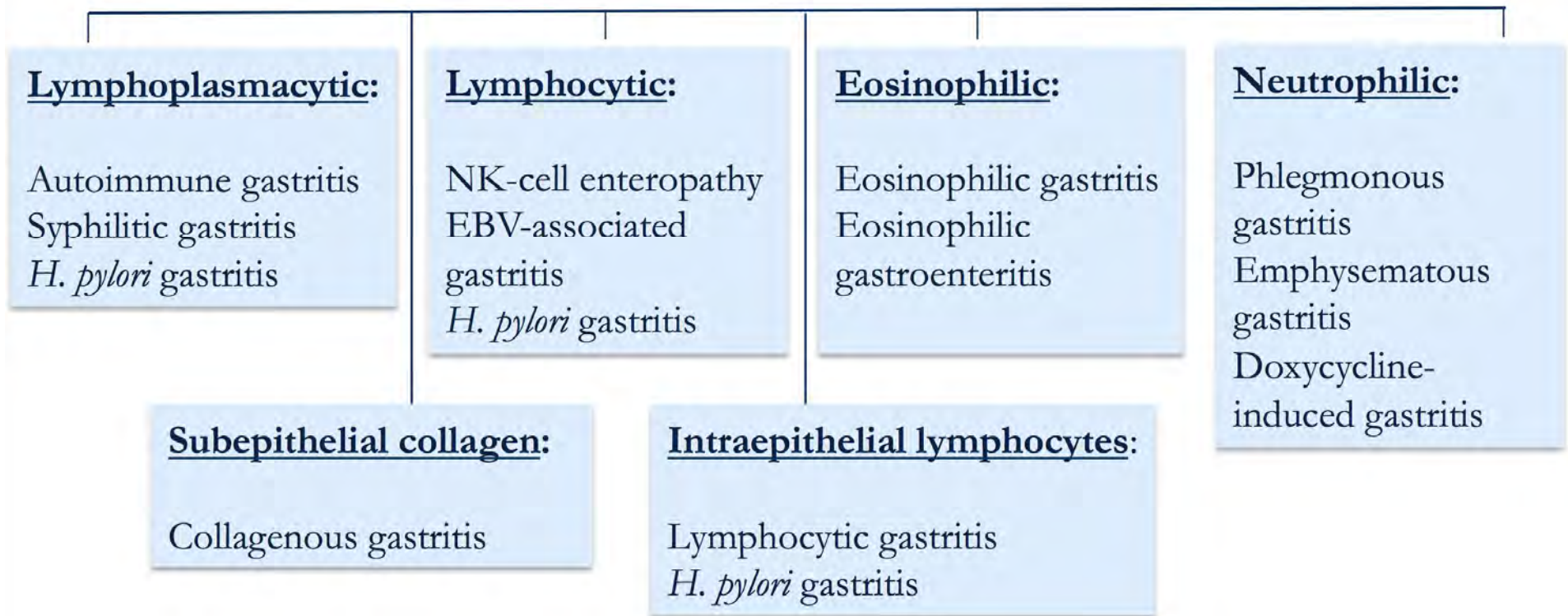


# H. Heilmannii

- Low prevalence
  - (0.3-0.7% in dev<sup>ped</sup> countries)
- Household pets
- Mild inflammation
- *H. felis*:
  - severe chronic active gastritis



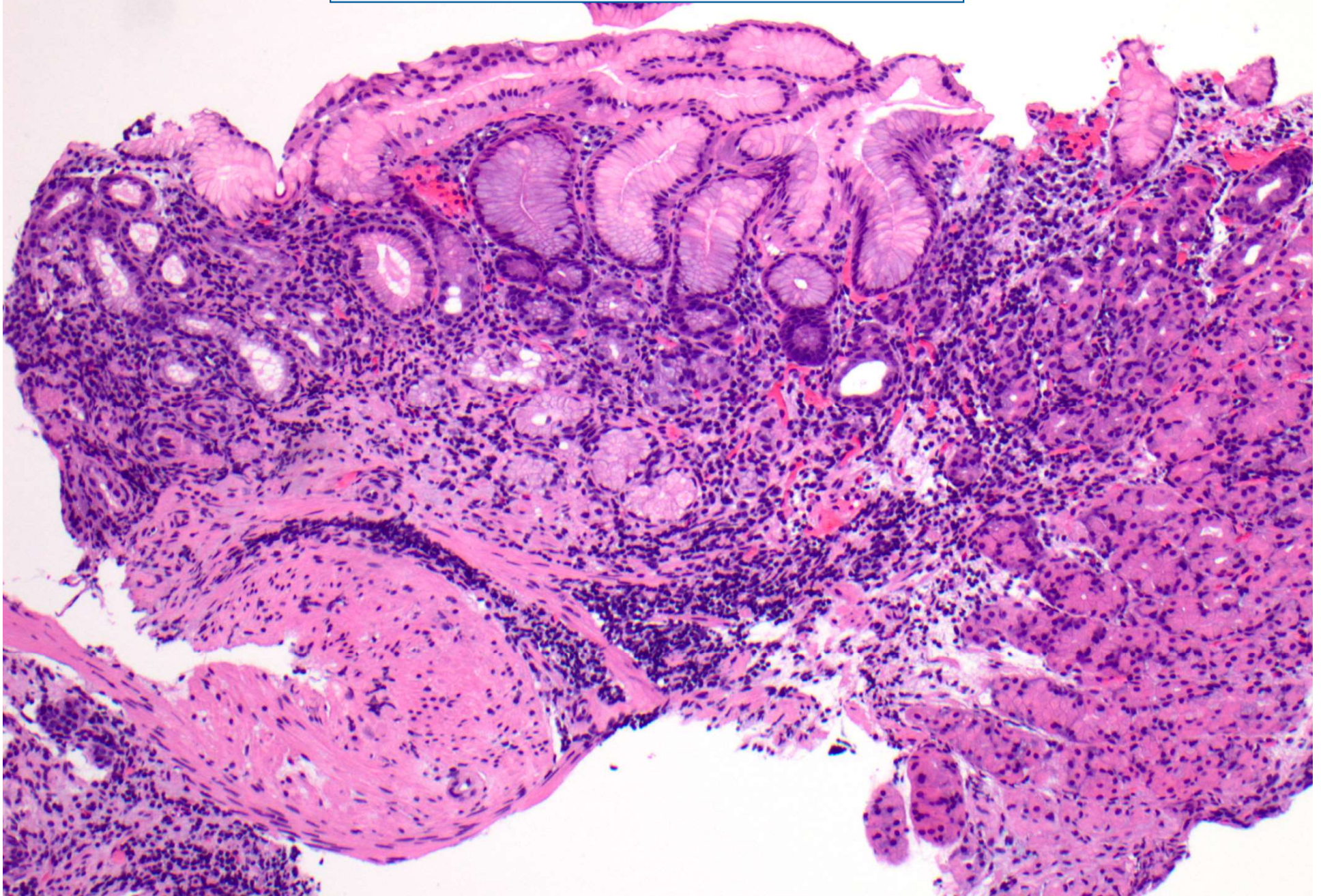
**GASTRITIS WITH PROMINENT INFLAMMATORY INFILTRATE OF THE LAMINA PROPRIA**

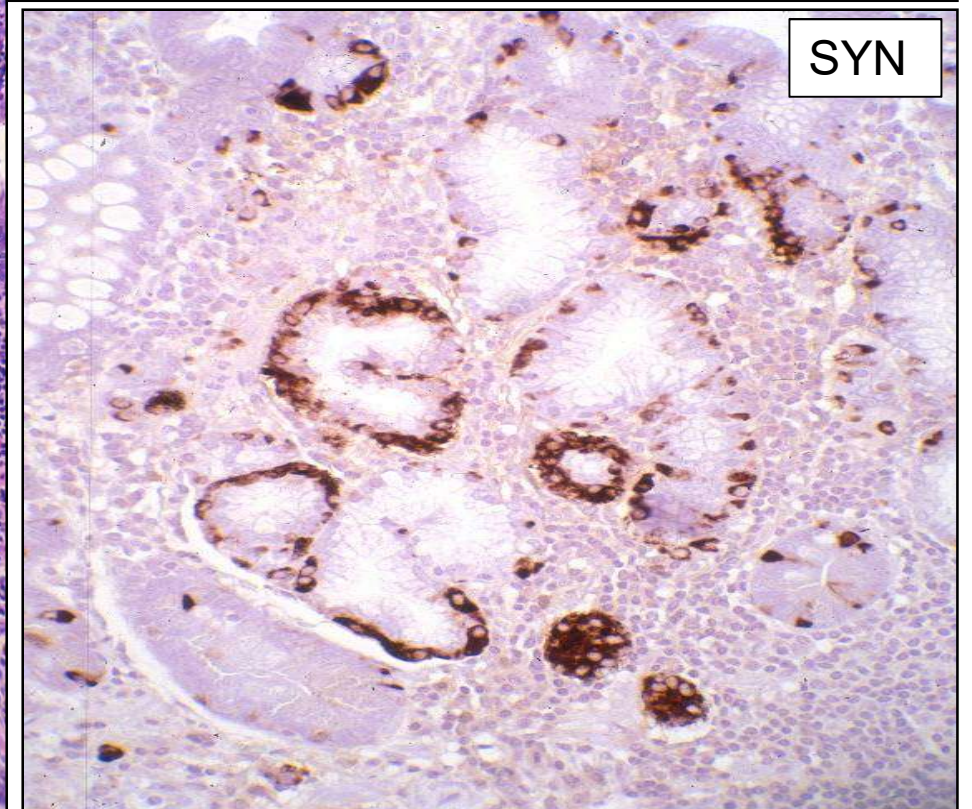
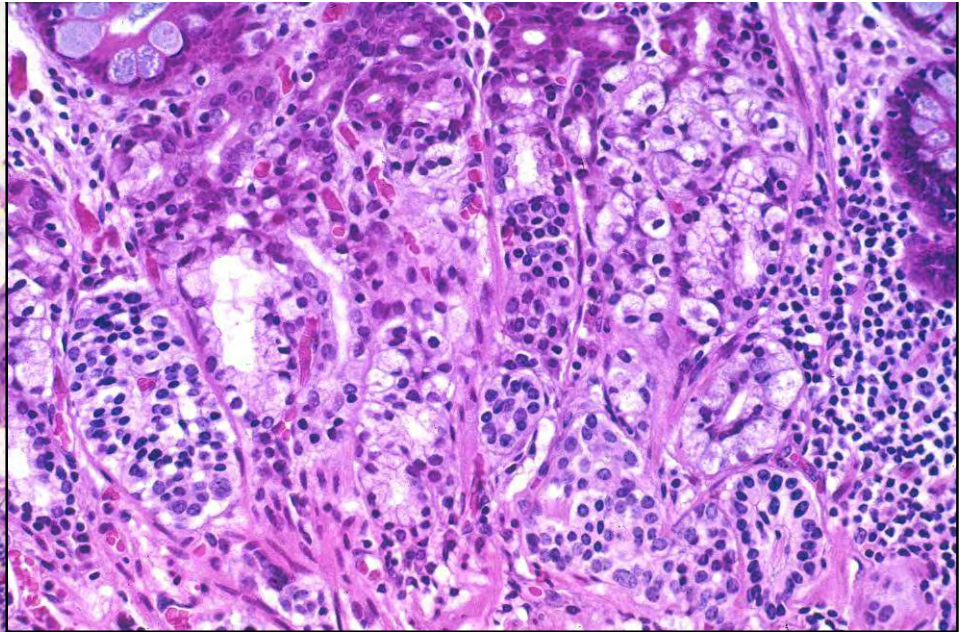
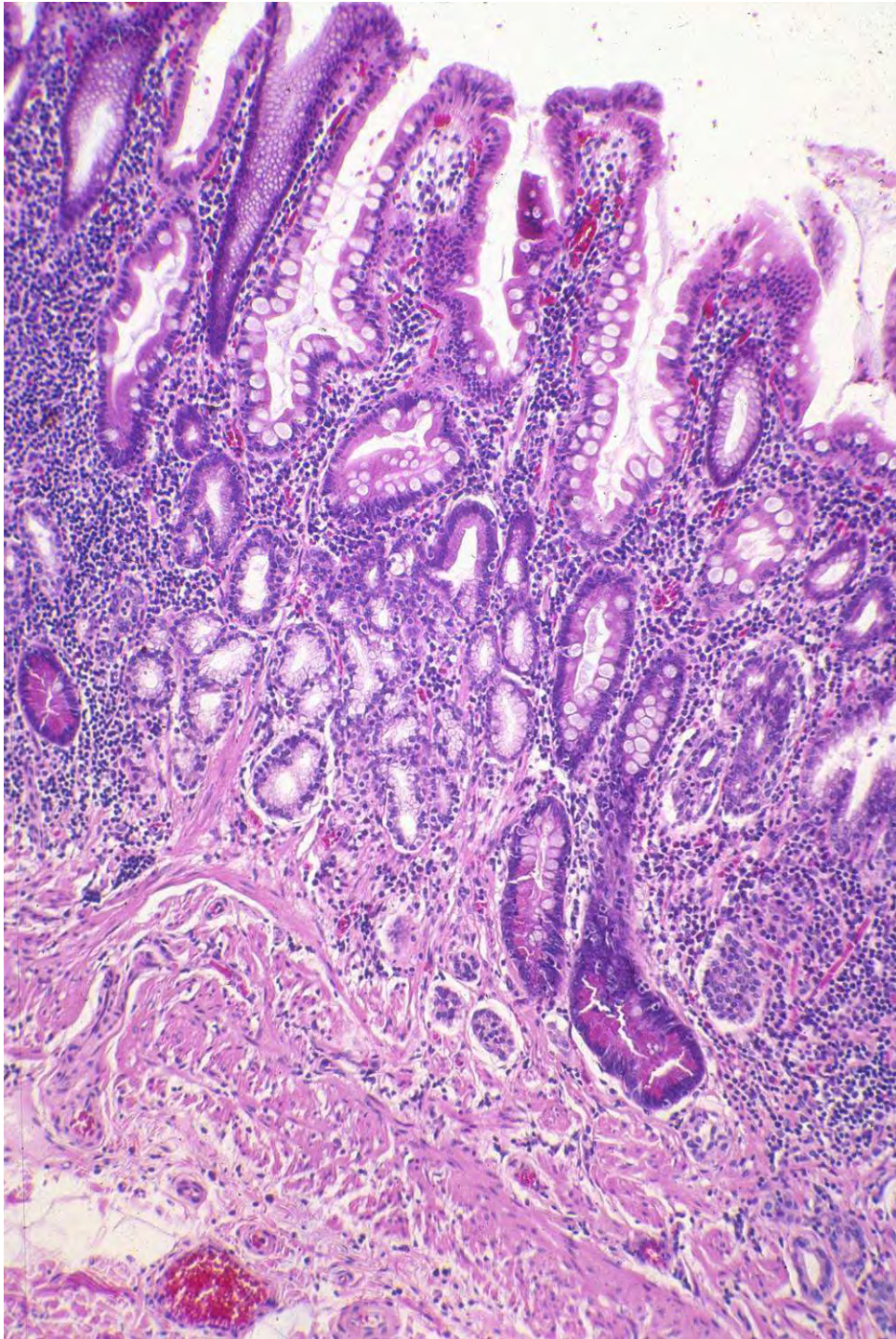


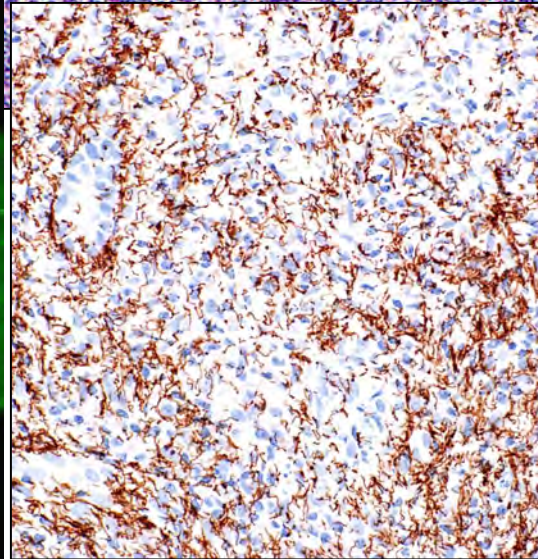
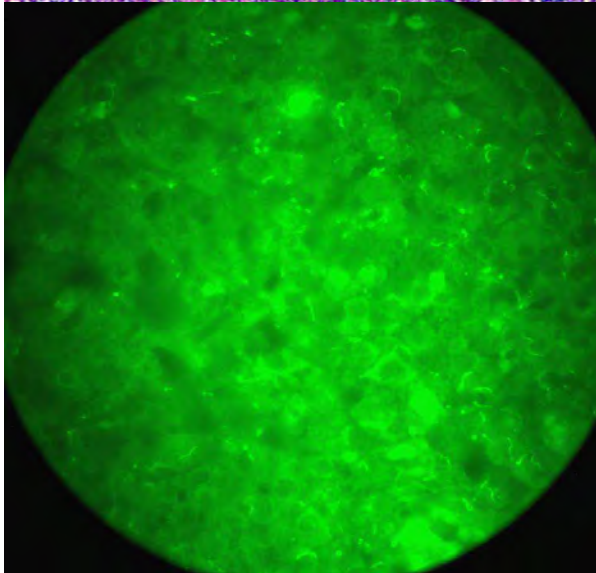
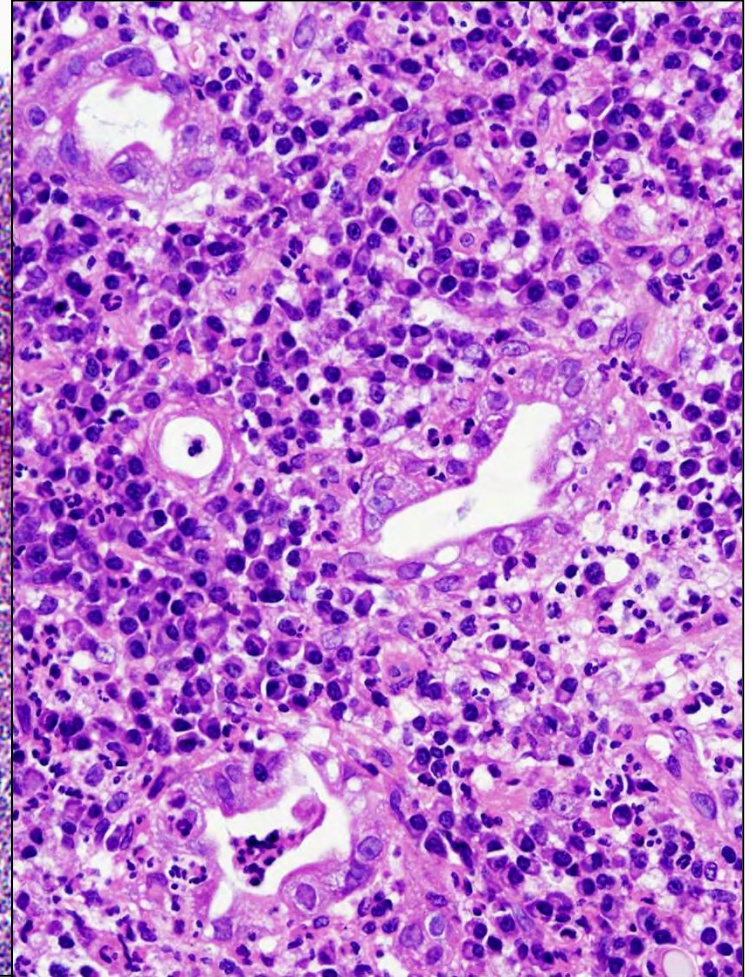
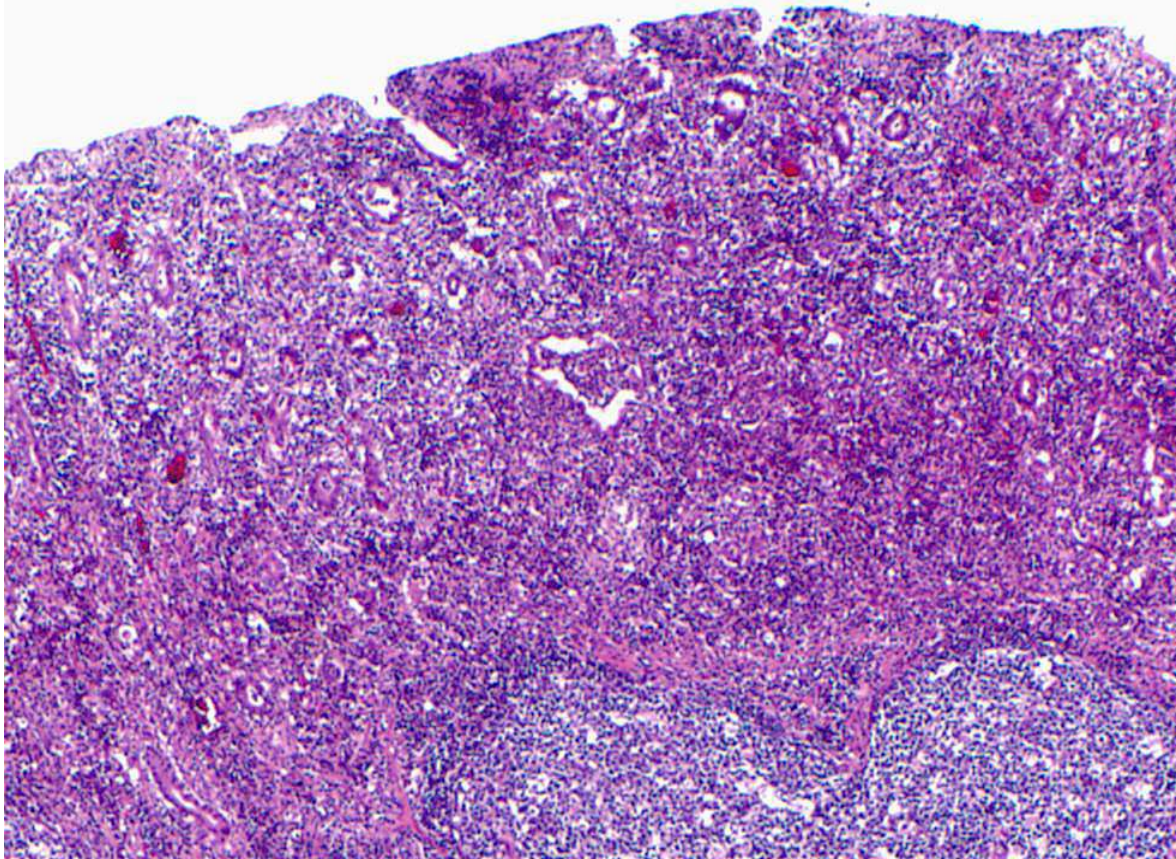
# Autoimmune Atrophic Gastritis

- Autosomal dominant inheritance
- Confined to corpus and fundus
- Immune – mediated injury (autoantibodies)
  - Loss of parietal cells
  - Gland atrophy
  - Metaplasia: **pseudopyloric** and intestinal types

## Autoimmune Gastritis

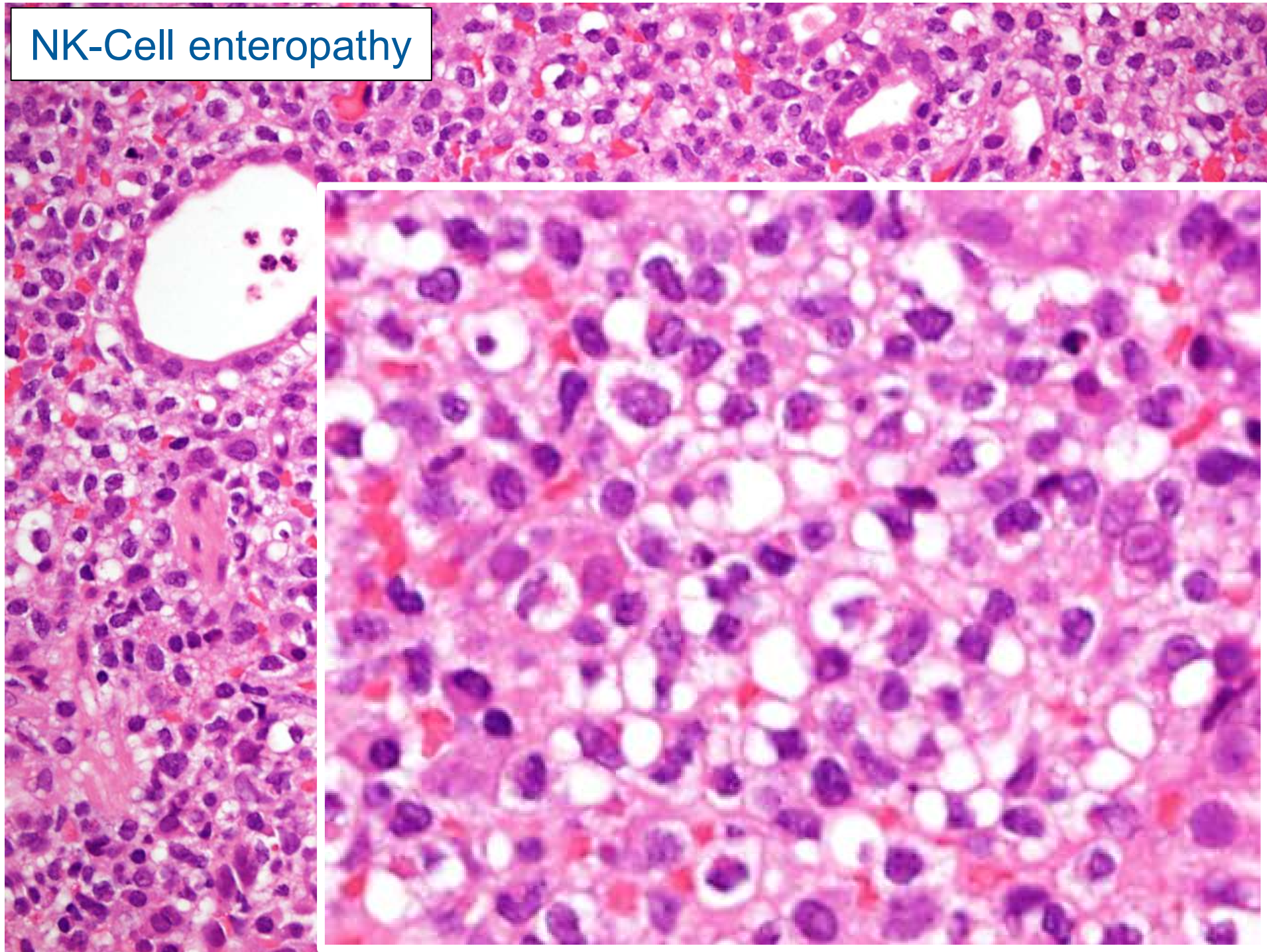




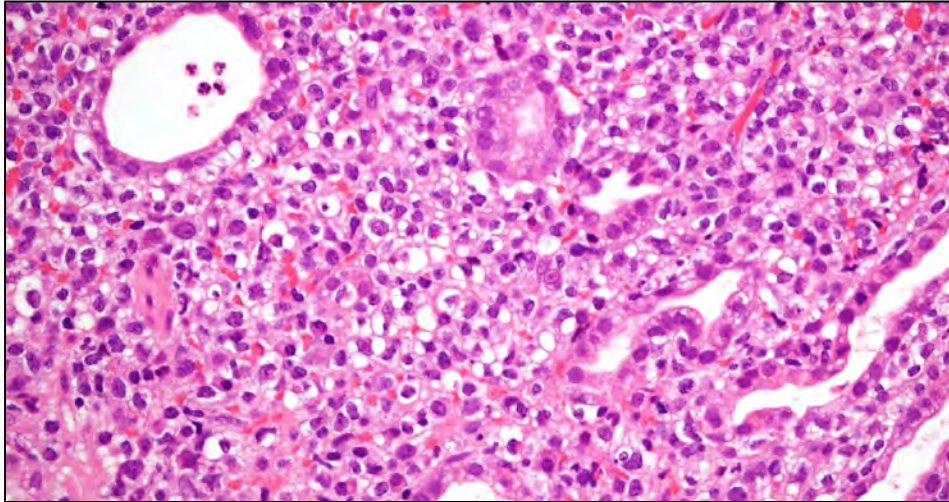


**Treponema pallidum**

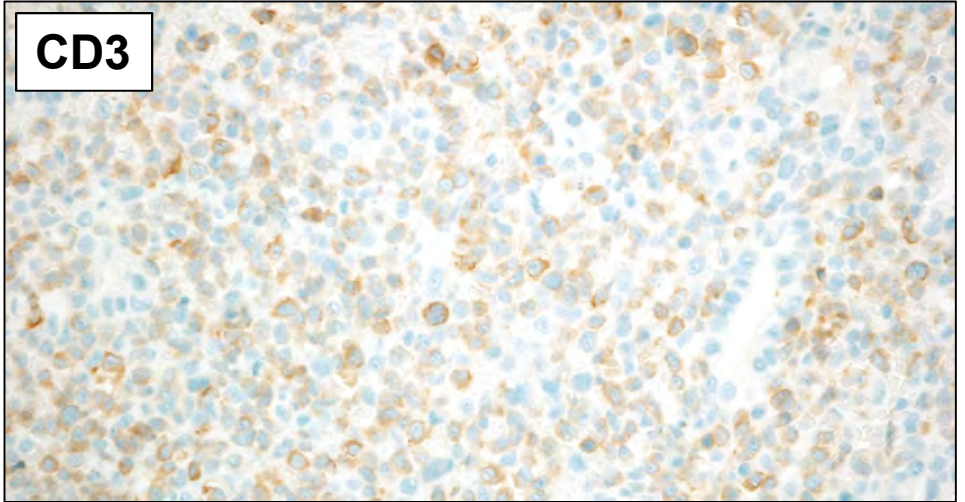
NK-Cell enteropathy



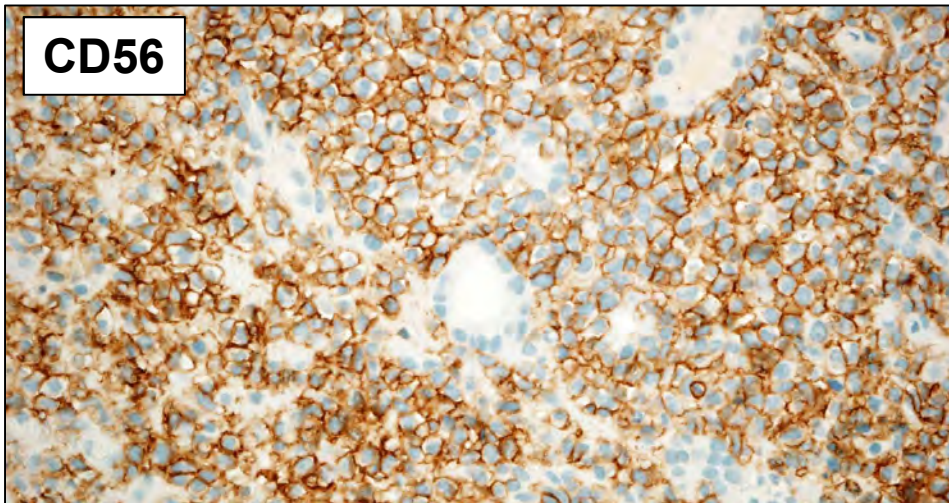
# NK-Cell enteropathy



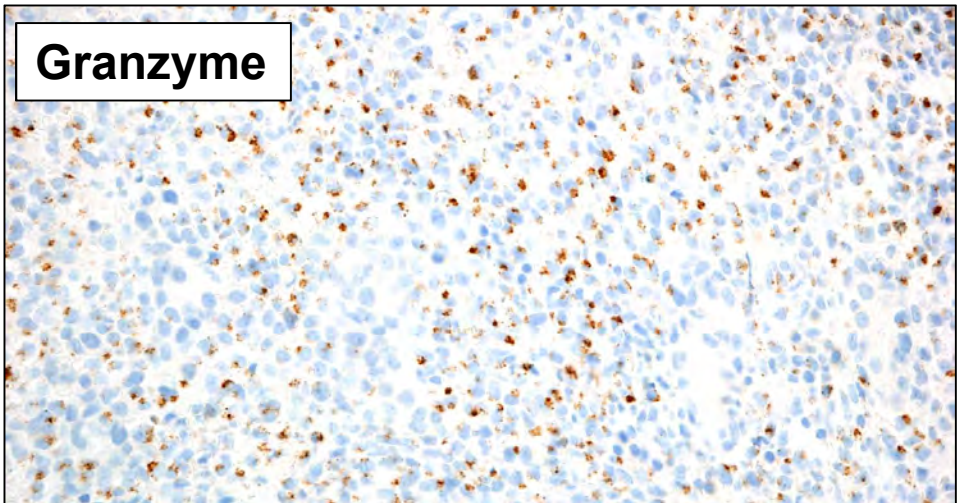
CD3

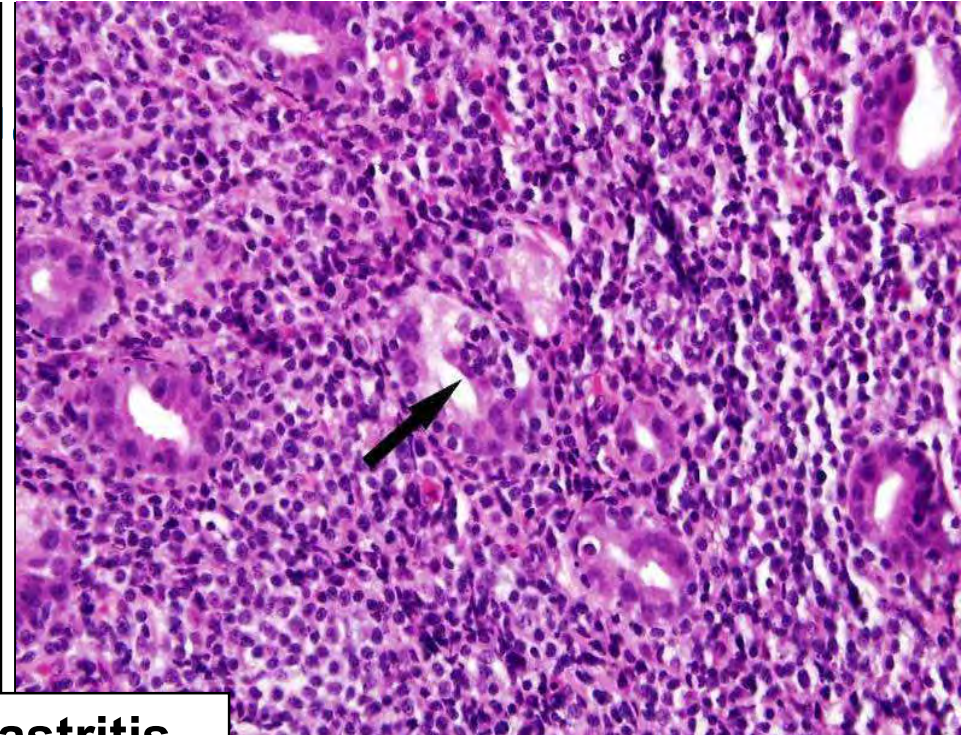
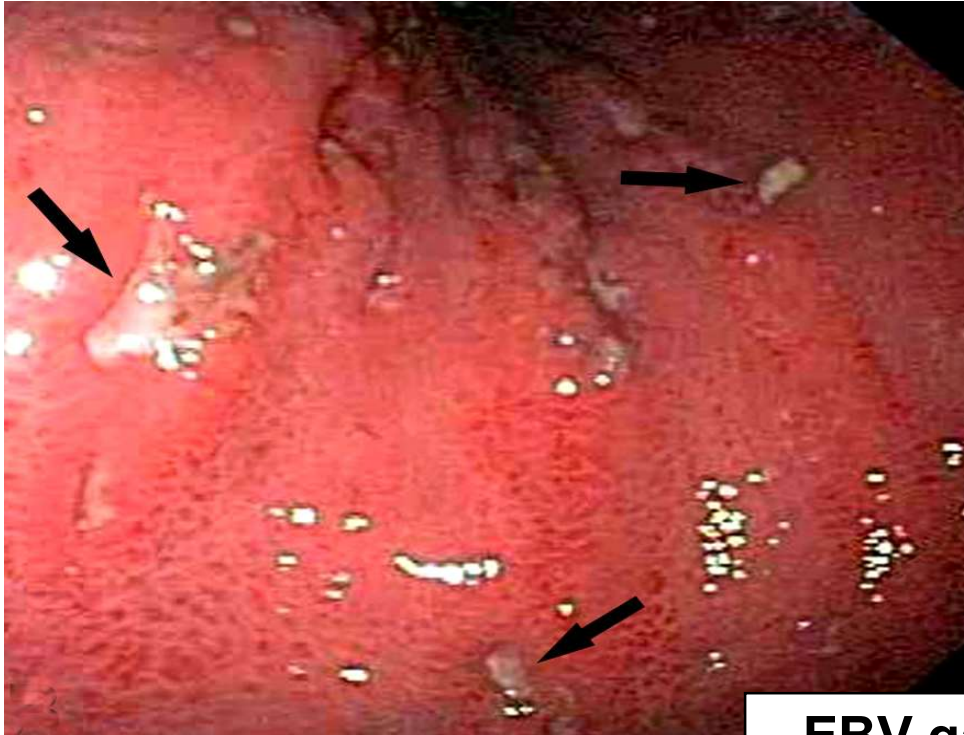


CD56

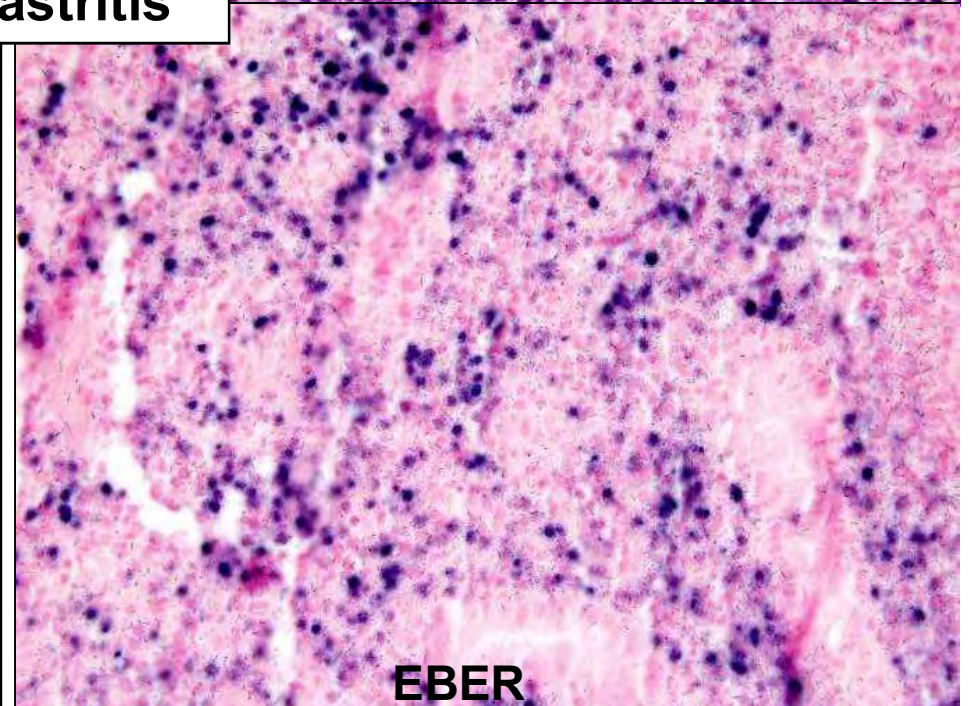
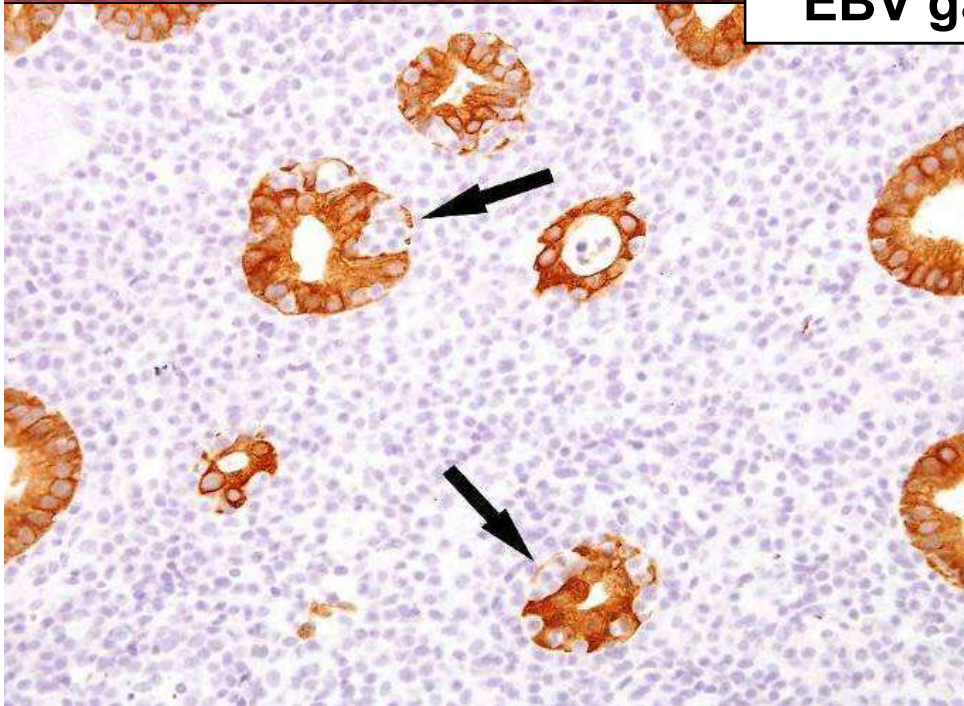


Granzyme



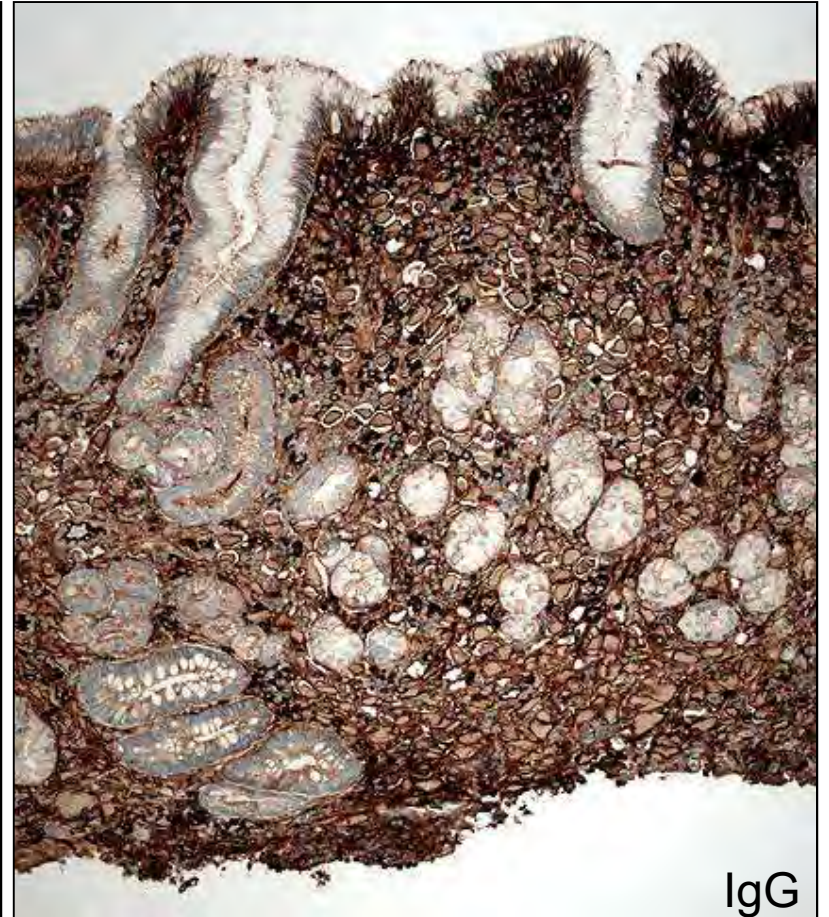
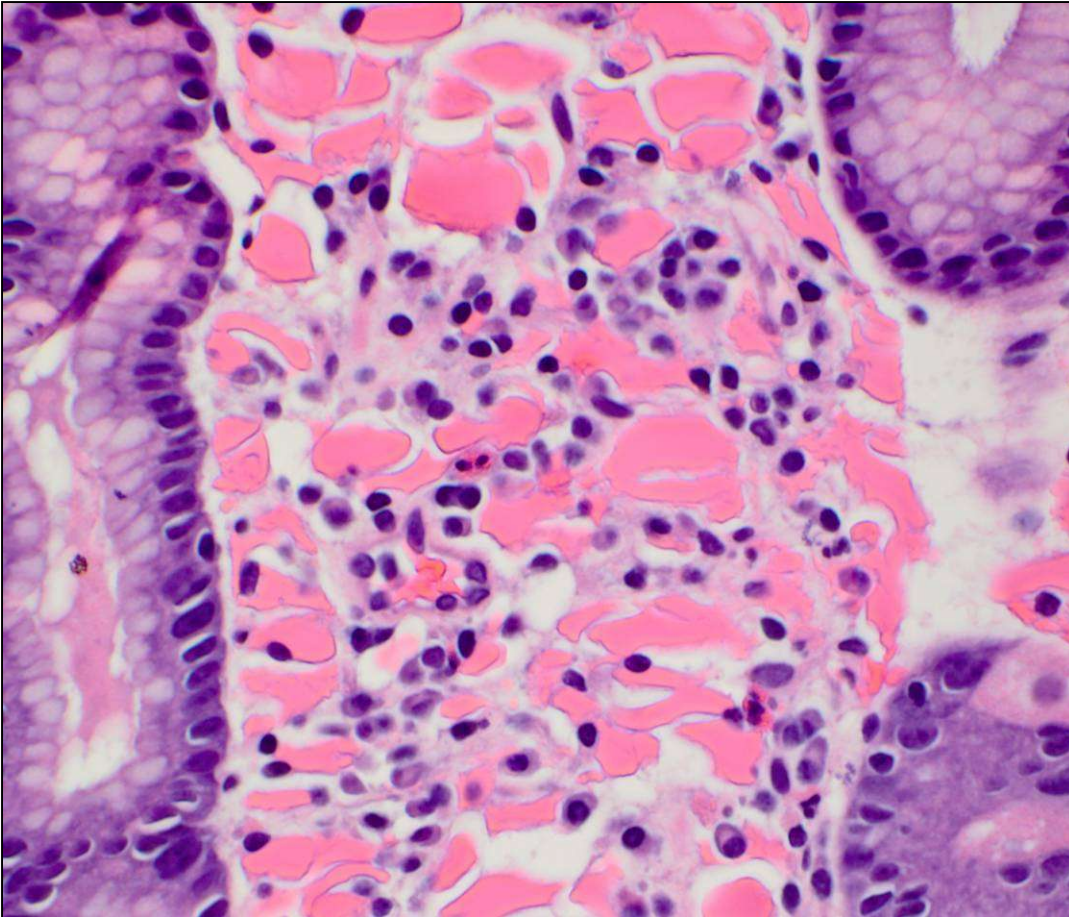


**EBV gastritis**



**EBER**

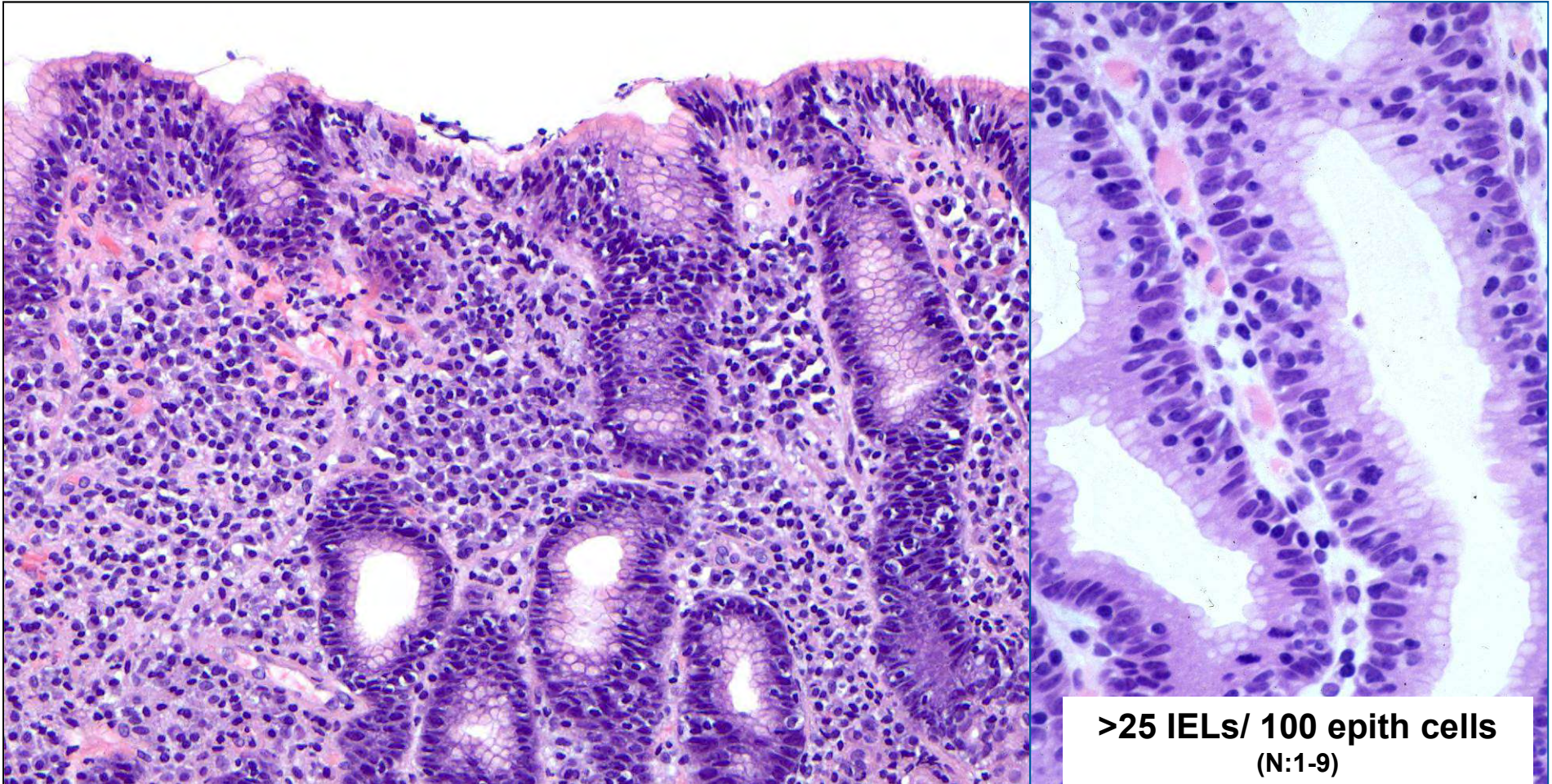
# Russell Body Gastritis



IgG

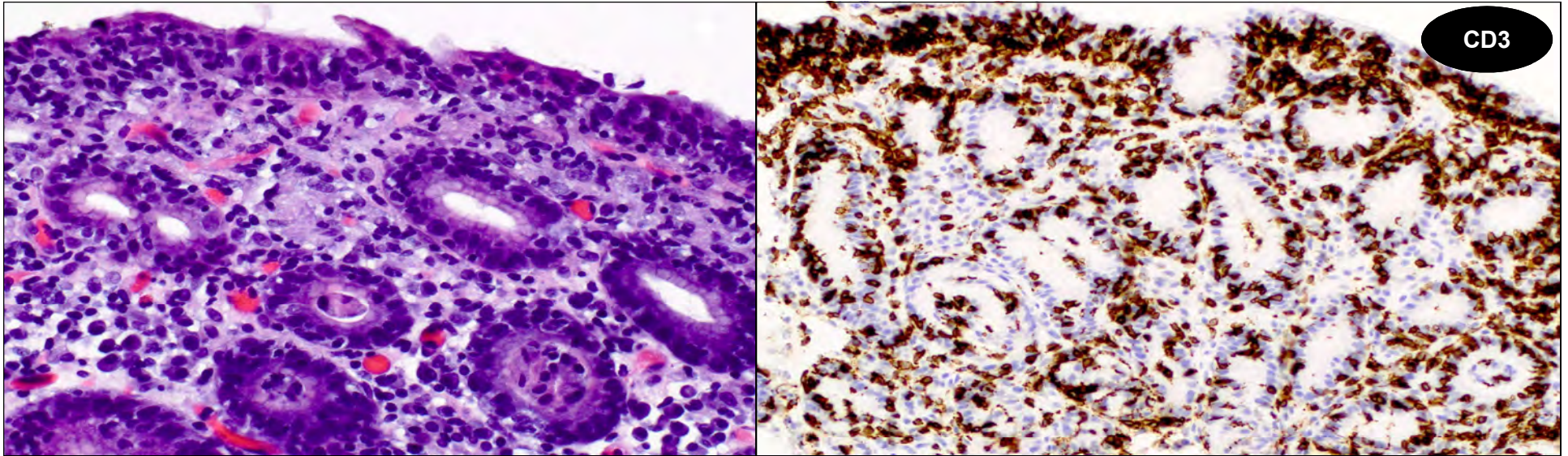
# Lymphocytic gastritis

- 0.83% of unselected biopsies
- 1.7% to 4.5% of inflamed biopsies



AJSP 1999;23.

•Pan gastric:76% - Fundus:18% - Antrum:6%



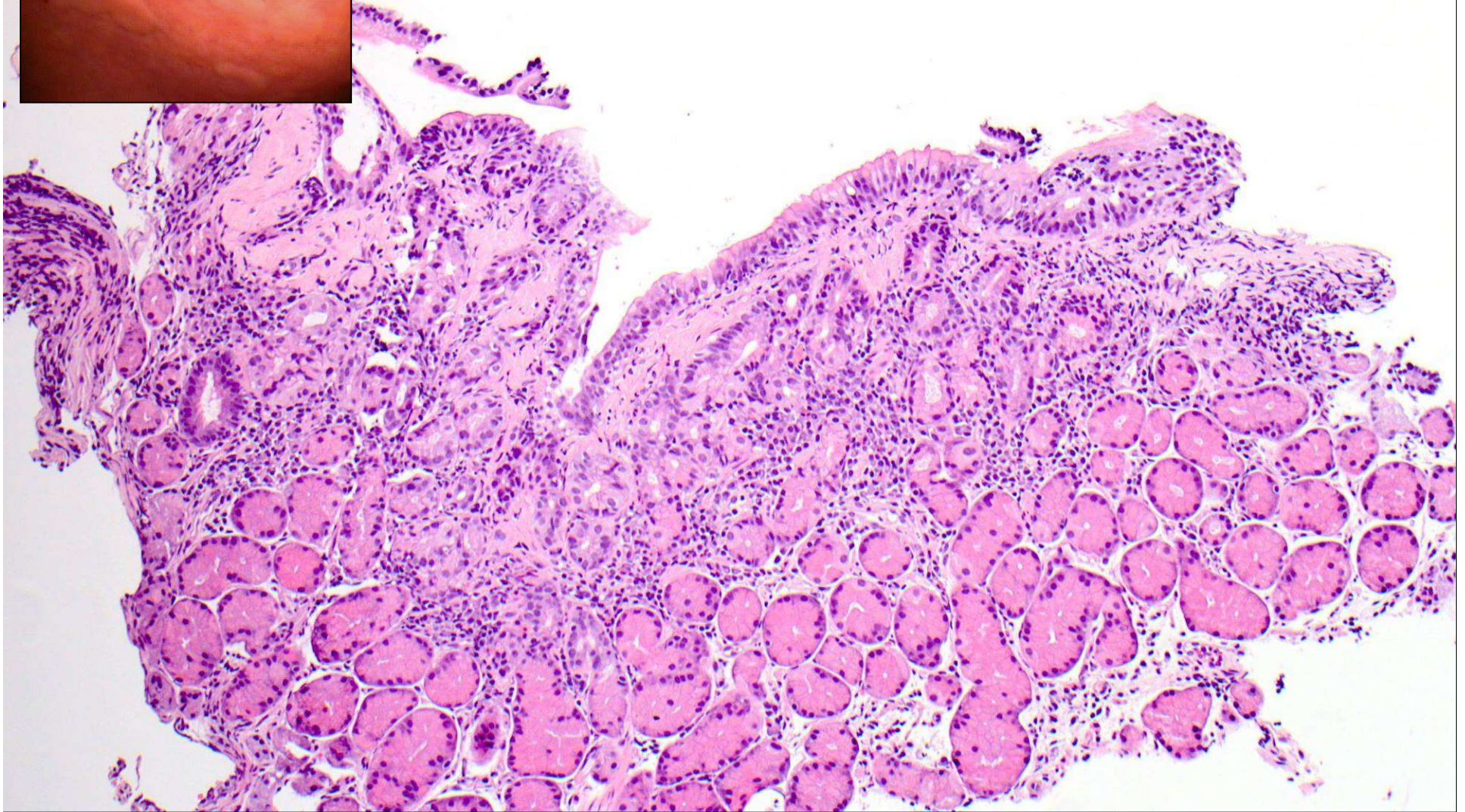
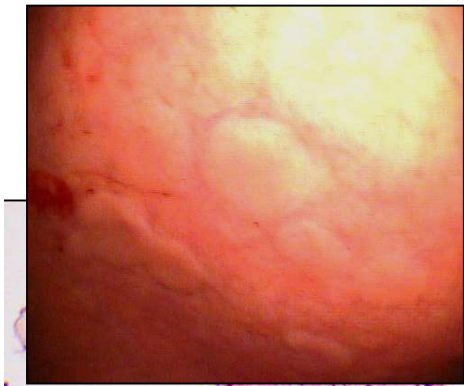- *H. pylori*: 30-40% [pan gastric or corpus predominant]
- Celiac sprue: 26.4-38% [typically antral]
- Crohn disease: 1.5%
- non GSE autoimmune disease: 4%
- Neoplasia (gastric cancer; lymphoma): 4%
- Drugs (Ticlopidine, Ticlid®): 1%
- HIV
- *No clinical association in 20-28% of the cases... a seasonal tendency (fall) was noted*

## Associations & Evolution of Lymphocytic Gastritis

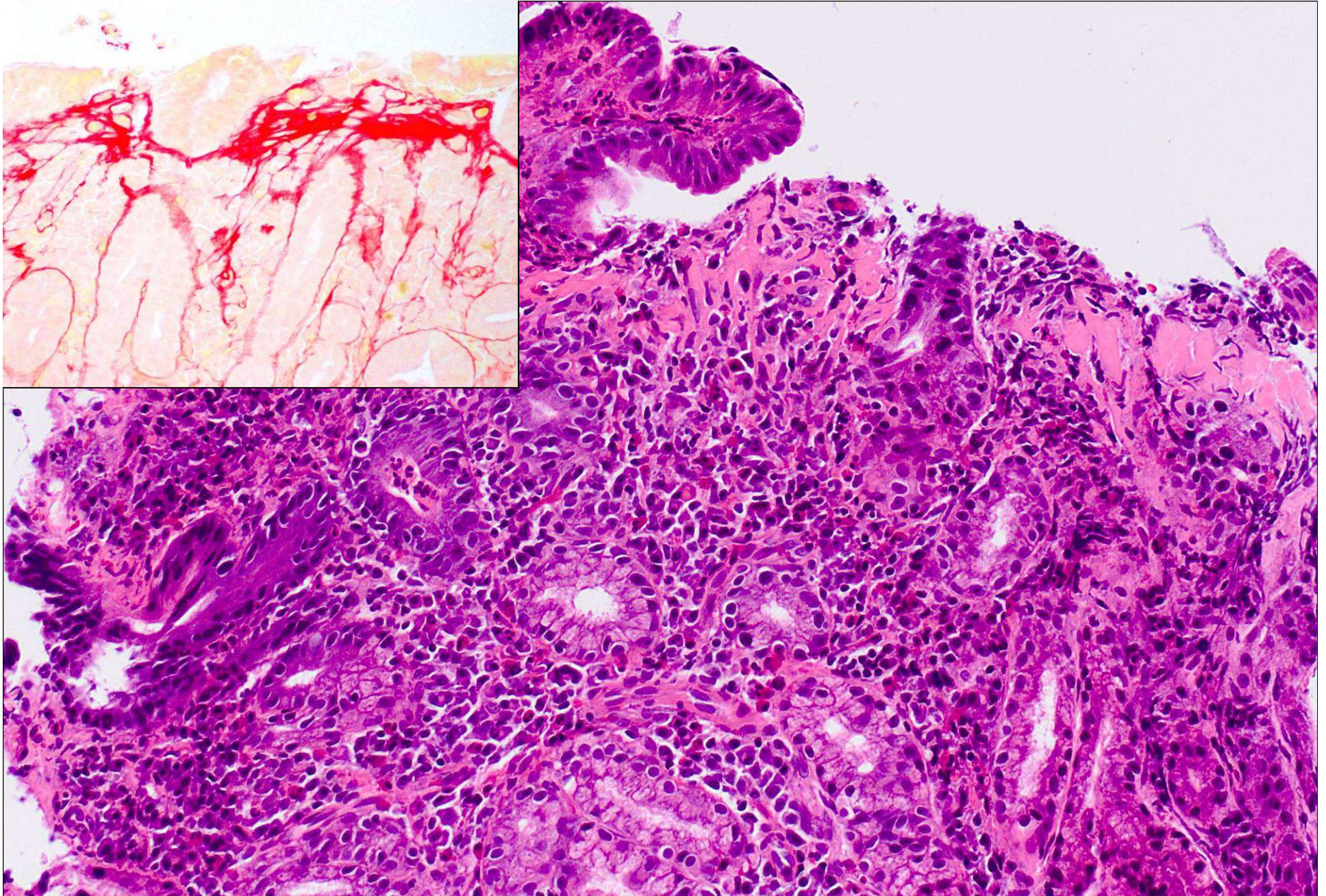
- 13.7% of associated duodenal bx exhibited non celiac related intraepithelial lymphocytosis:
  - 33% with *H.pylori*,
  - 67% without any clinical association.
- 9% of colon bx displayed lymphocytic colitis (all celiac related) and 5.7% had collagenous colitis (none celiac related).
- 63 (18.2%) patients had follow up biopsies (mean 33 months) w/ **resolution of LG in 89%, including all *H.pylori* related cases and all but 1 GSE related case.**

Personal data: 346 cases (age range 1-87 years, mean age 51 years).

# Collagenous Gastritis



- Subepithelial deposition of collagen in the superficial lamina propria associated w/ superficial lymphoplasmacytic infiltrate, scattered eosinophils, and rare neutrophils.



Collagen band is variably thick and discontinuous and entraps capillaries, (can average 30-70 microns; type III, IV and VI collagen; Increased IELs)

# The 2 clinical subsets of Collagenous Gastritis

(based on ~90 cases in the literature)

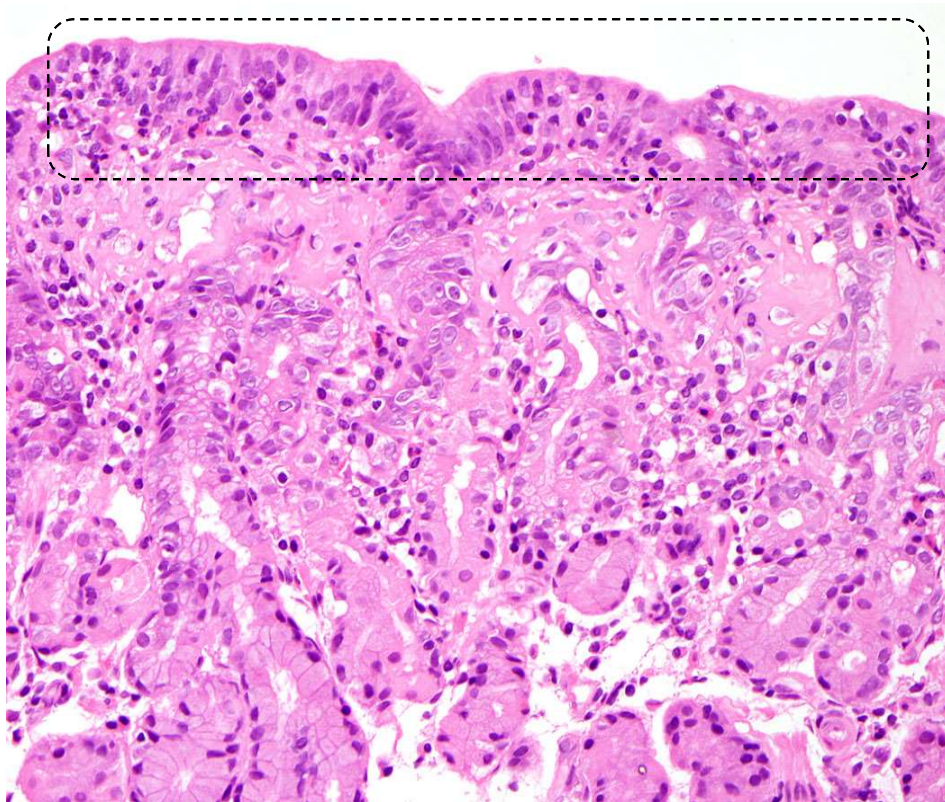
- ***Pediatric patients***

- Pain (57%), anemia (39%), bleeding (22%)
- Celiac sprue (8%); collagenous sprue, collagenous colitis (4%) each...disease more commonly confined to stomach.

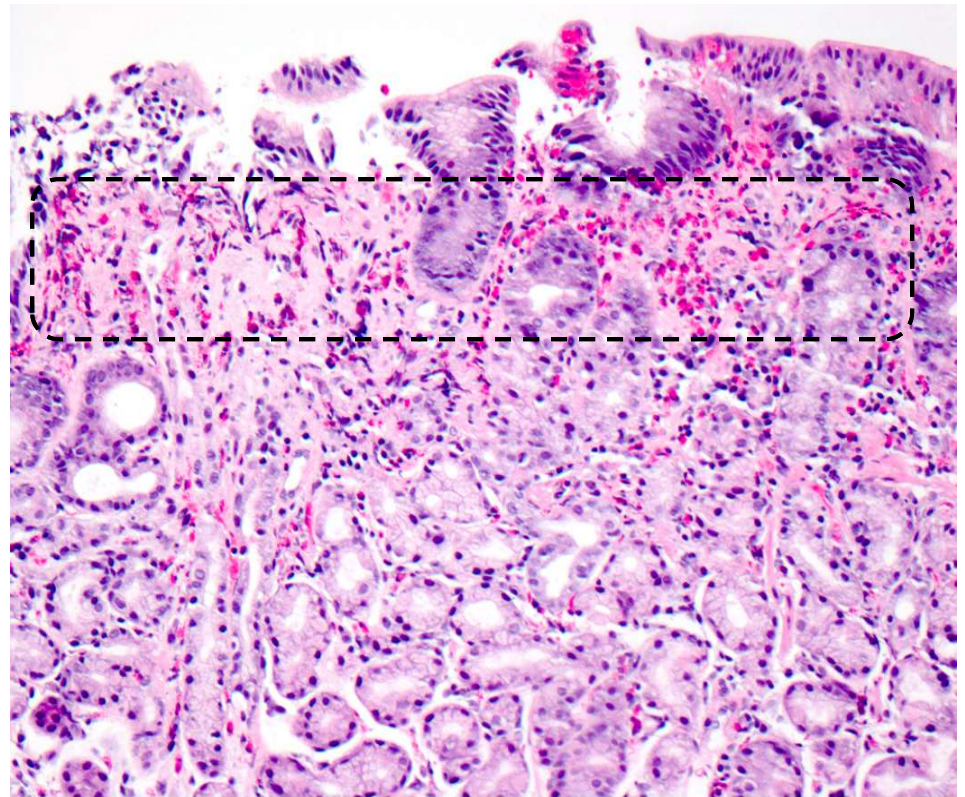
- ***Adults (women+)***

- Anemia (67%), Diarrhea(27%)
- Collagenous colitis (38%), collagenous sprue (25%), celiac sprue (6%)
- The more likely pan-enteric involvement...suggest a pan-enteric pathogenetic process.
- (also think drugs: Olmesartan®)





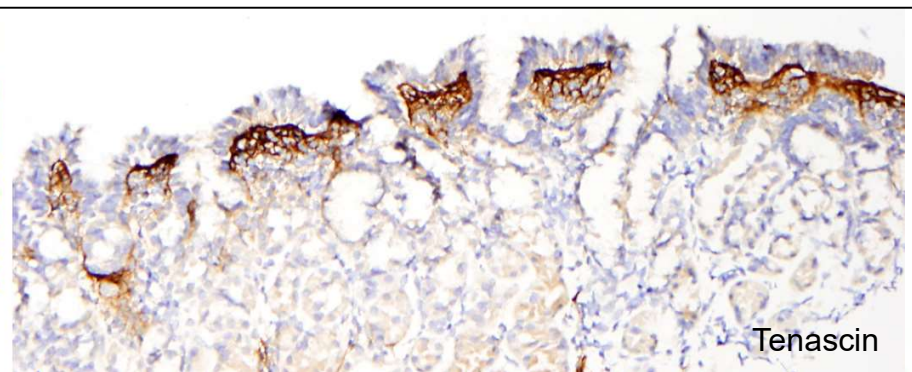
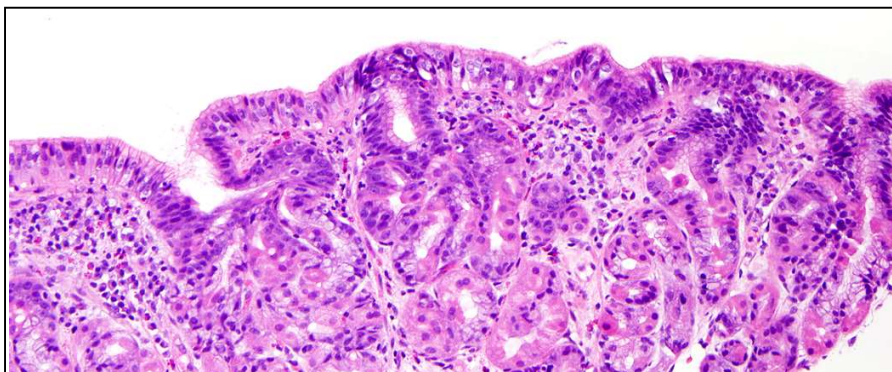
Intra-epithelial lymphocytes



Eosinophils

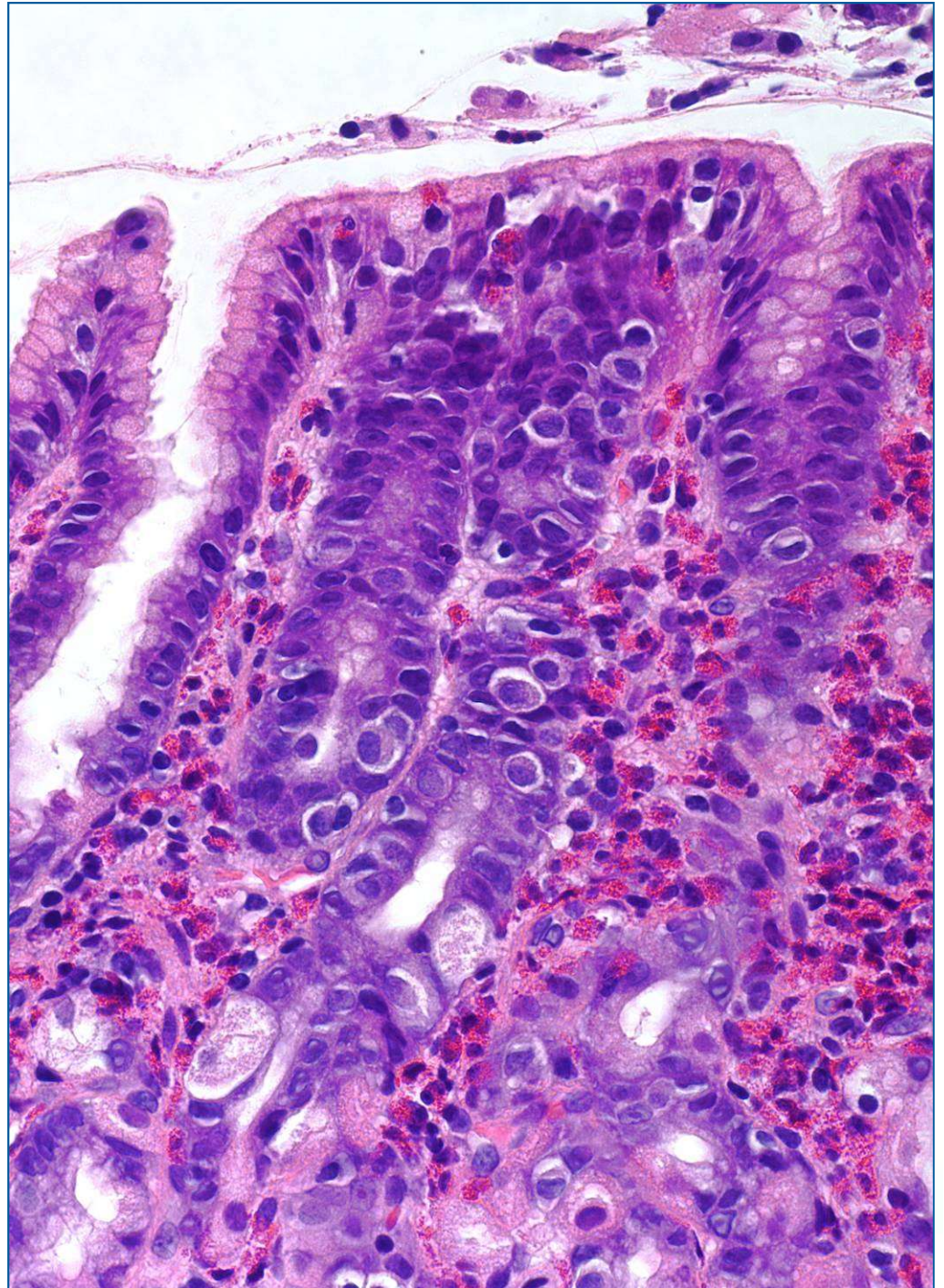
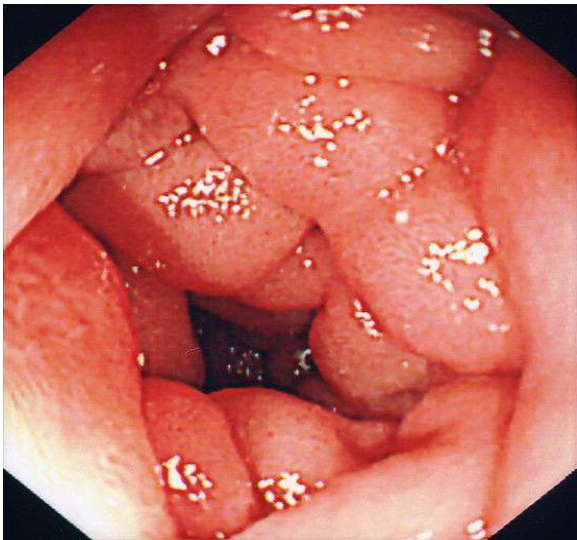
		Age ≤18	Age >18
Eosinophilic inflammation	>30/HPF	15 (62%)	6 (38%)
	≤30/HPF	9 (38%)	10 (62%)
Intraepithelial lymphocytes	>25	2 (8%)	3 (19%)
	≤25	22 (92%)	13 (81%)
Atrophy of corpus	Moderate to severe	5 (21%)	2 (12%)
	Mild or none	19 (79%)	14 (88%)

		Age ≤18	Age >18
Location of collagen	corpus predominant	17 (71%)	5 (31%)
	antrum predominant	3 (12.5%)	8 (50%)
	equal antral/corpus involvement or unclear	4 (17%)	3 (19%)
Surface epithelial sloughing	none	0	3 (19%)
	focal (<30% of surface)	19 (79%)	13 (81%)
	prominent (>30% of surface)	5 (21%)	0
Collagen distribution	focal (<30% of surface)	2 (8%)	1 (6%)
	patchy (30-69% of surface)	13 (54%)	7 (44%)
	diffuse (≥70% of surface)	9 (38%)	8 (50%)



# Eosinophilic Gastritis

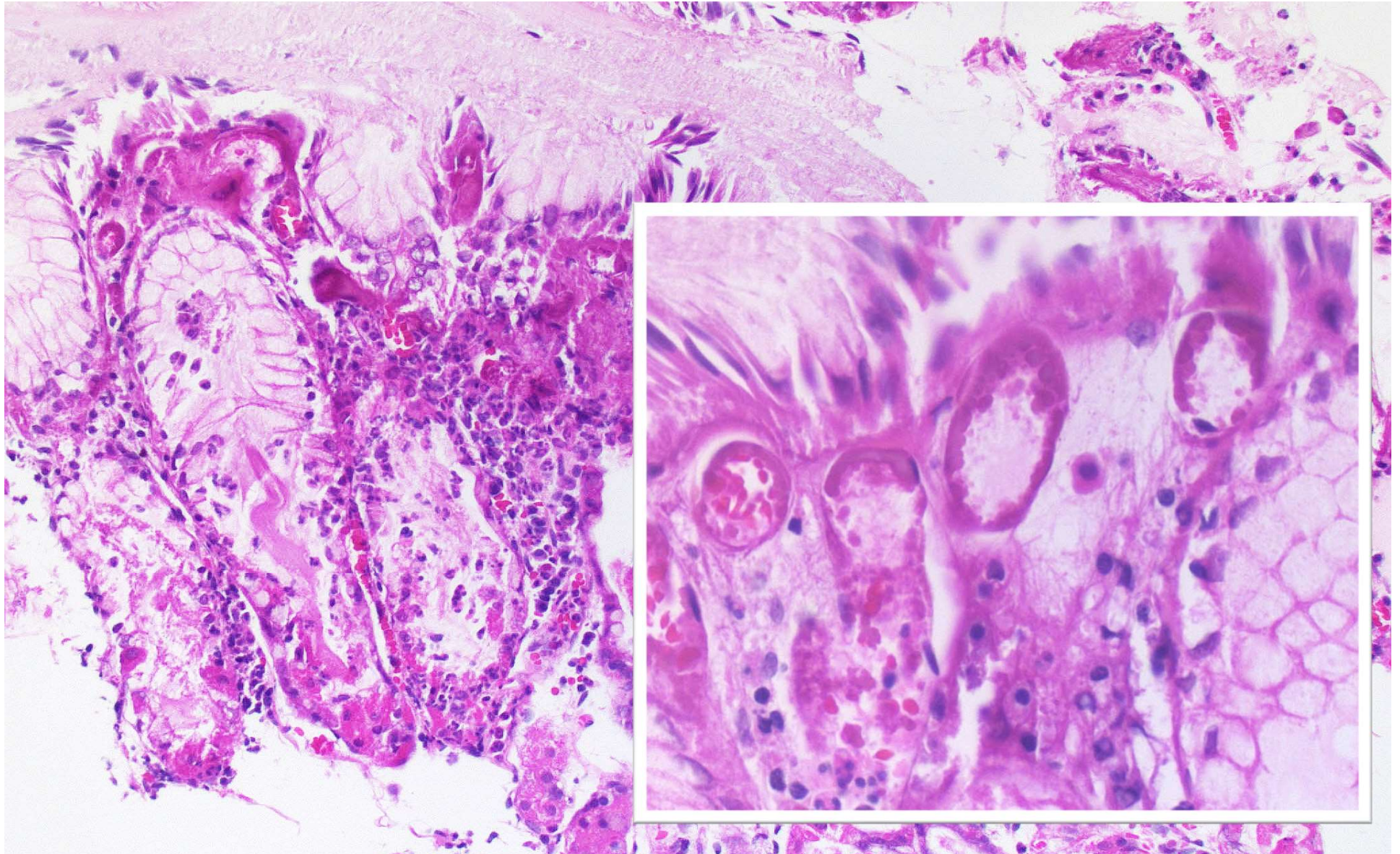
- Asthma/ Food allergies.
- Paraneoplastic Sd.
- Parasitic infestation.
- Connective tissue diseases.
- Drugs (i.e, angiotensine converting enz.inh.)



# Gastric Mucosal Necrosis With Vascular Degeneration Induced by Doxycycline

*Shu-Yuan Xiao, MD,\* Lei Zhao, MD, PhD,\* John Hart, MD,\* and Carol E. Semrad, MD†*

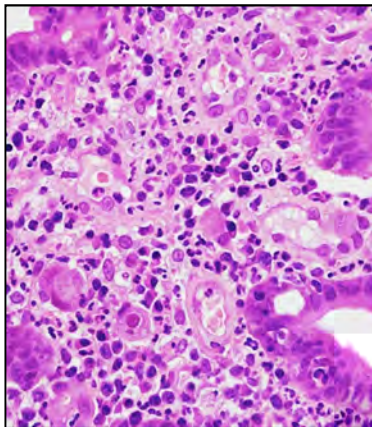
AJSP 2013;37



## GASTRITIS WITH LIMITED INFLAMMATORY INFILTRATE OF THE LAMINA PROPRIA

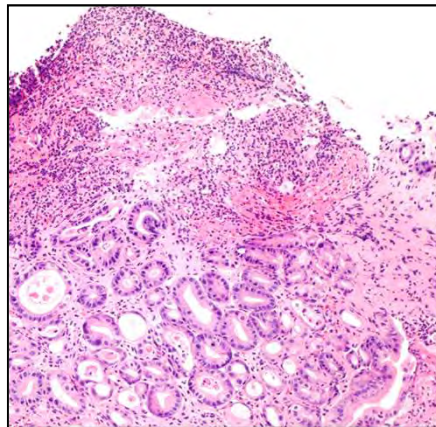
### Viral inclusions:

CMV gastritis  
HSV gastritis



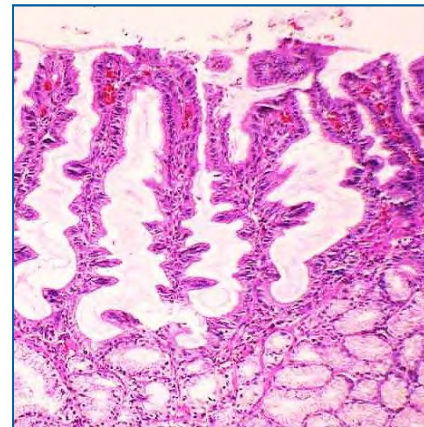
### Hemorrhage, ulceration, and/or necrosis:

Caustic gastritis  
Ulcerohemorrhagic gastritis



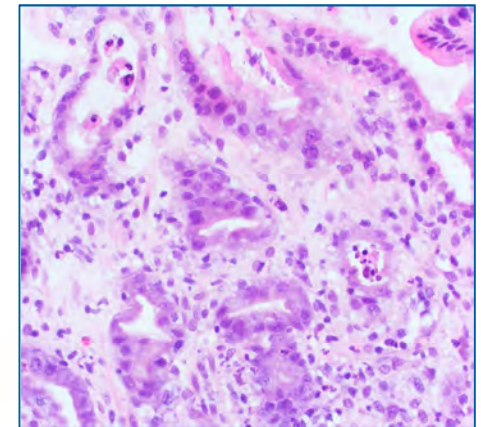
### Foveolar hyperplasia and mucin depletion:

Reactive gastropathy

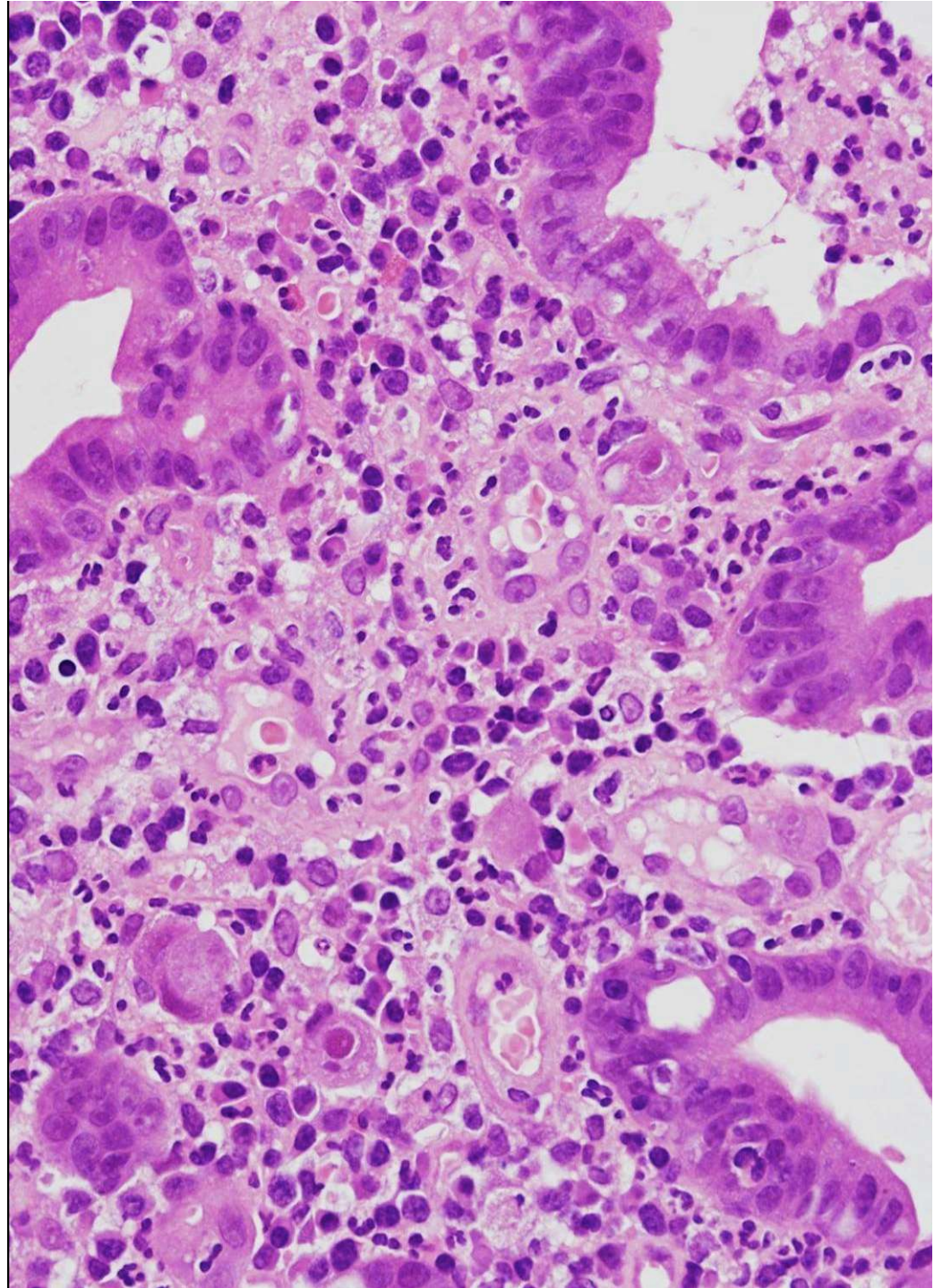


### Increased apoptosis and/or mitotic figures and nuclear atypia:

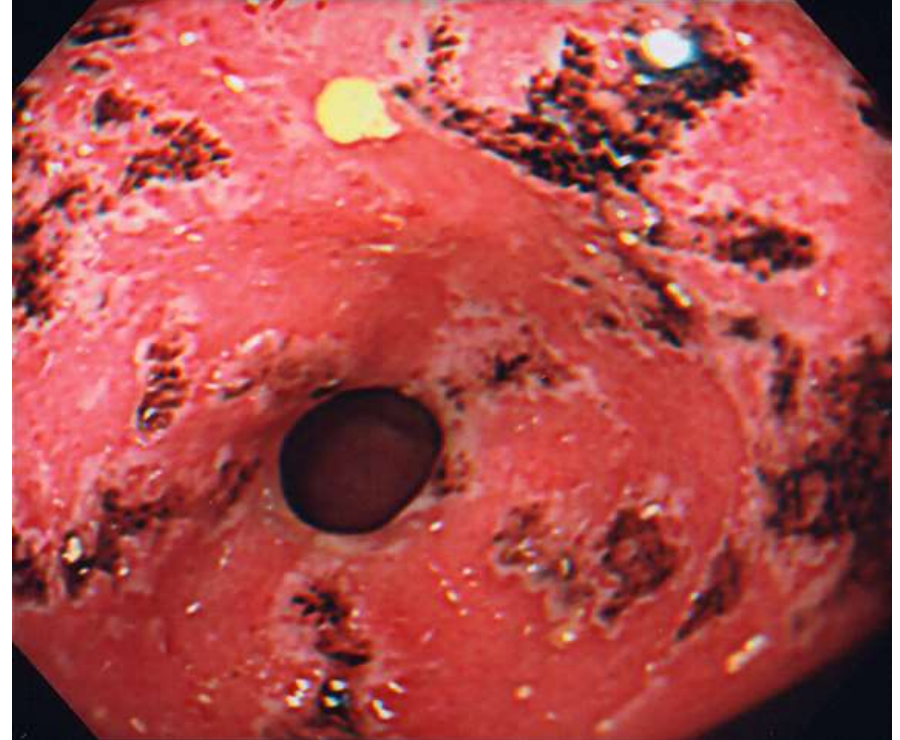
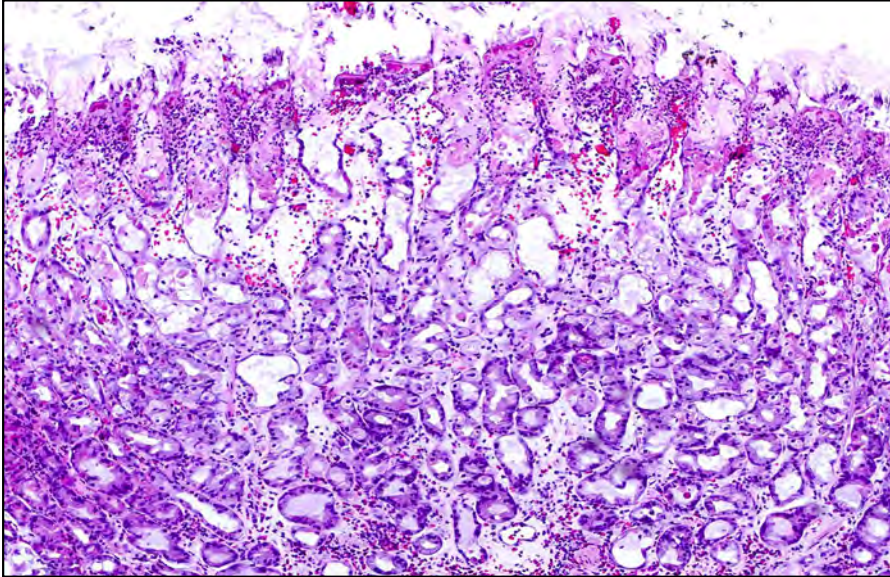
GVHD  
Drug-induced gastritis (colchicine and taxol)  
Chemoradiation-induced gastritis



**CMV**



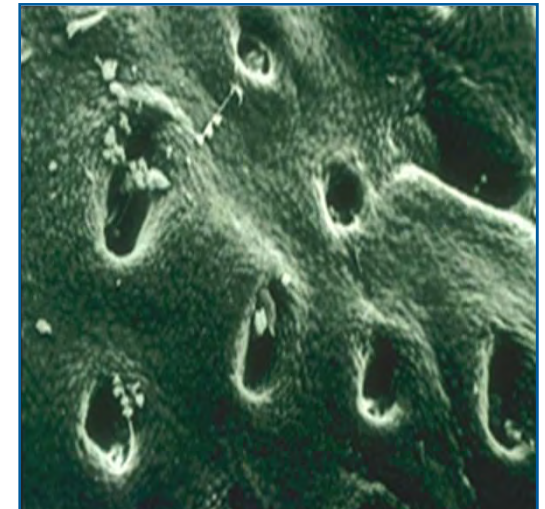
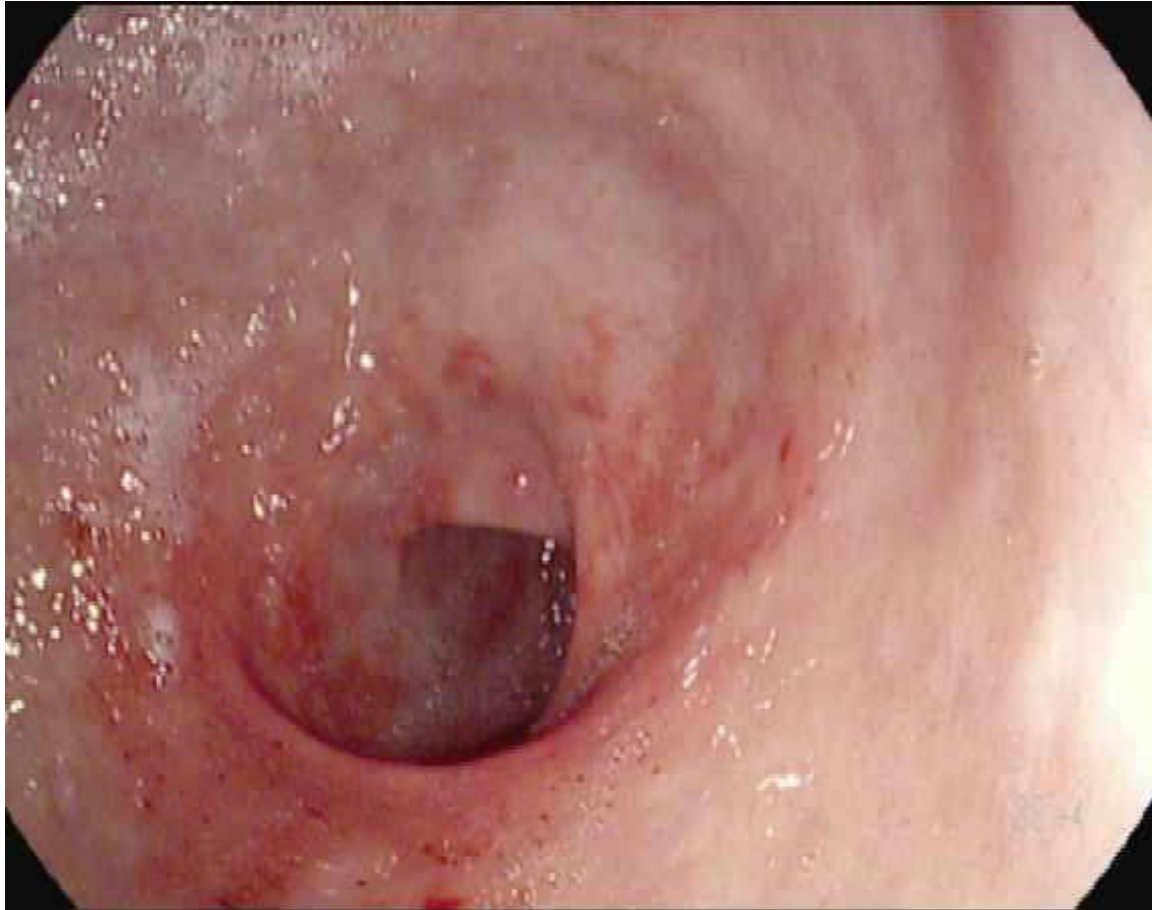# Acute Hemorrhagic Gastritis



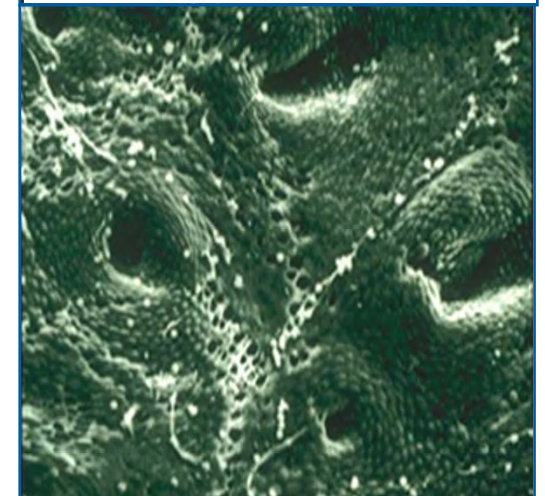
Shock  
NSAIDs  
EtOH  
Steroids

- Ischemia
- Increased vascular permeability
- Direct mucosal injury
- Interference w/ PG synthesis

# 30-40% of patients taking NSAIDs may show gastric mucosal damages

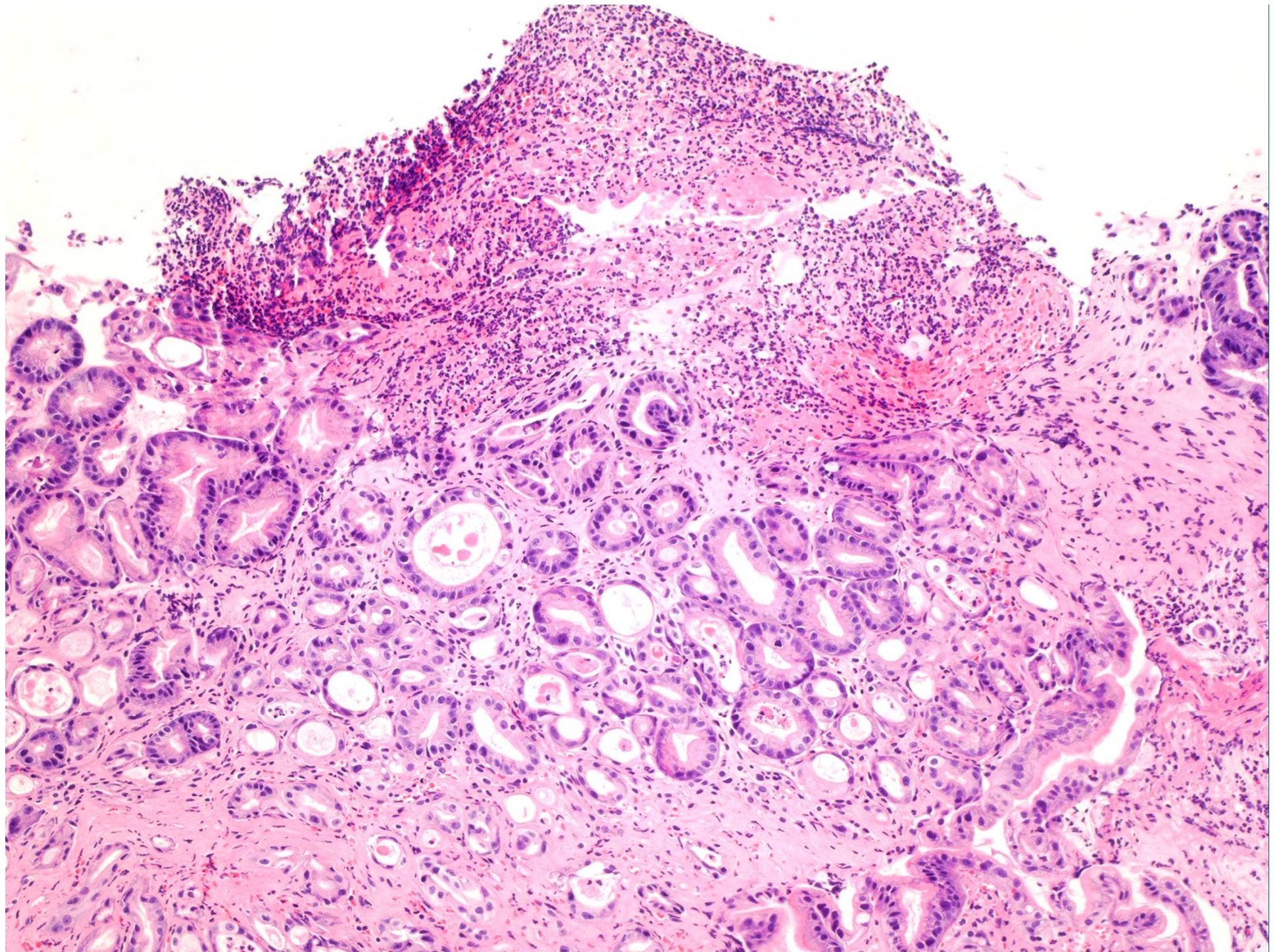


normal gastric mucosa

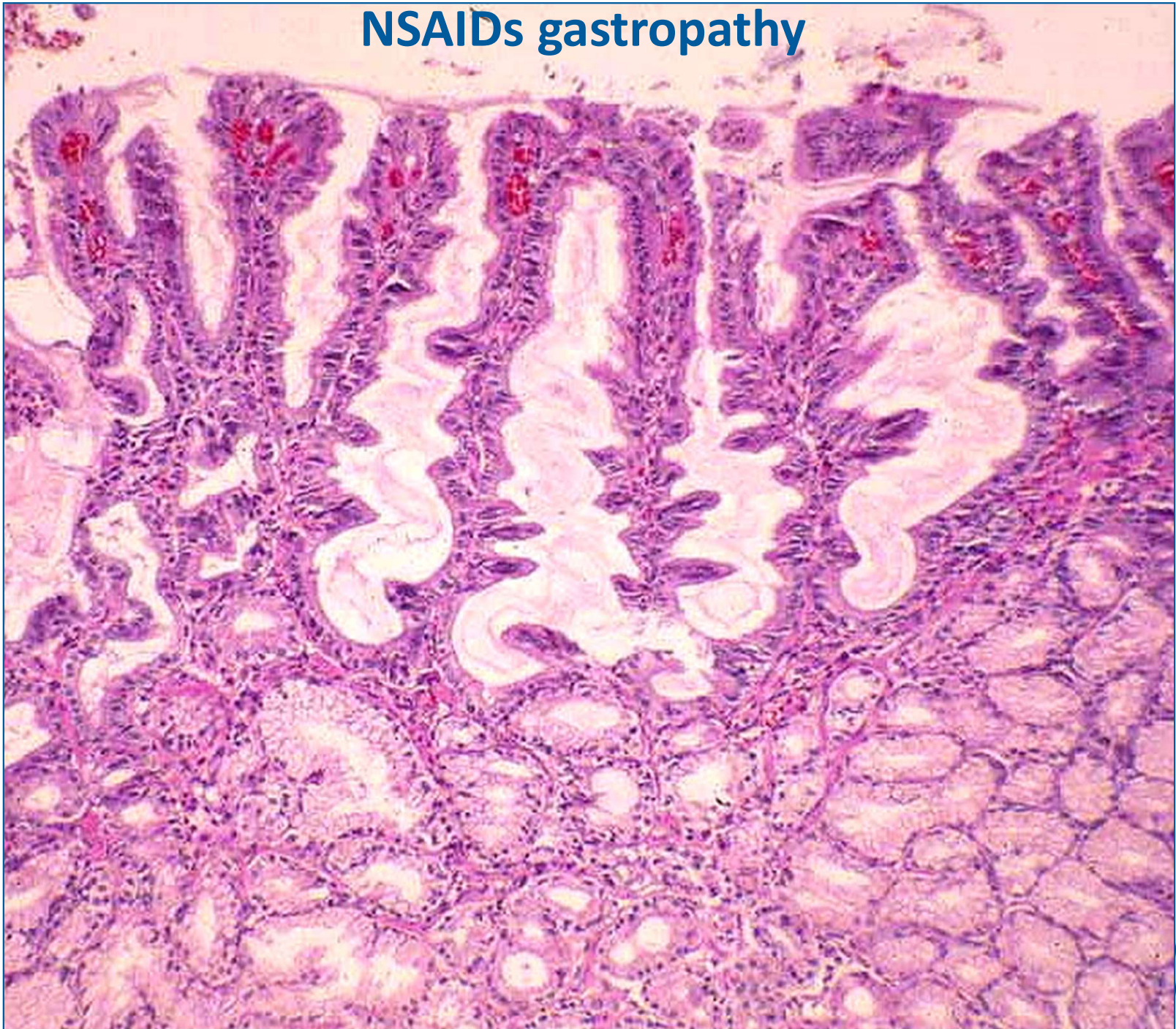


16 min post administration

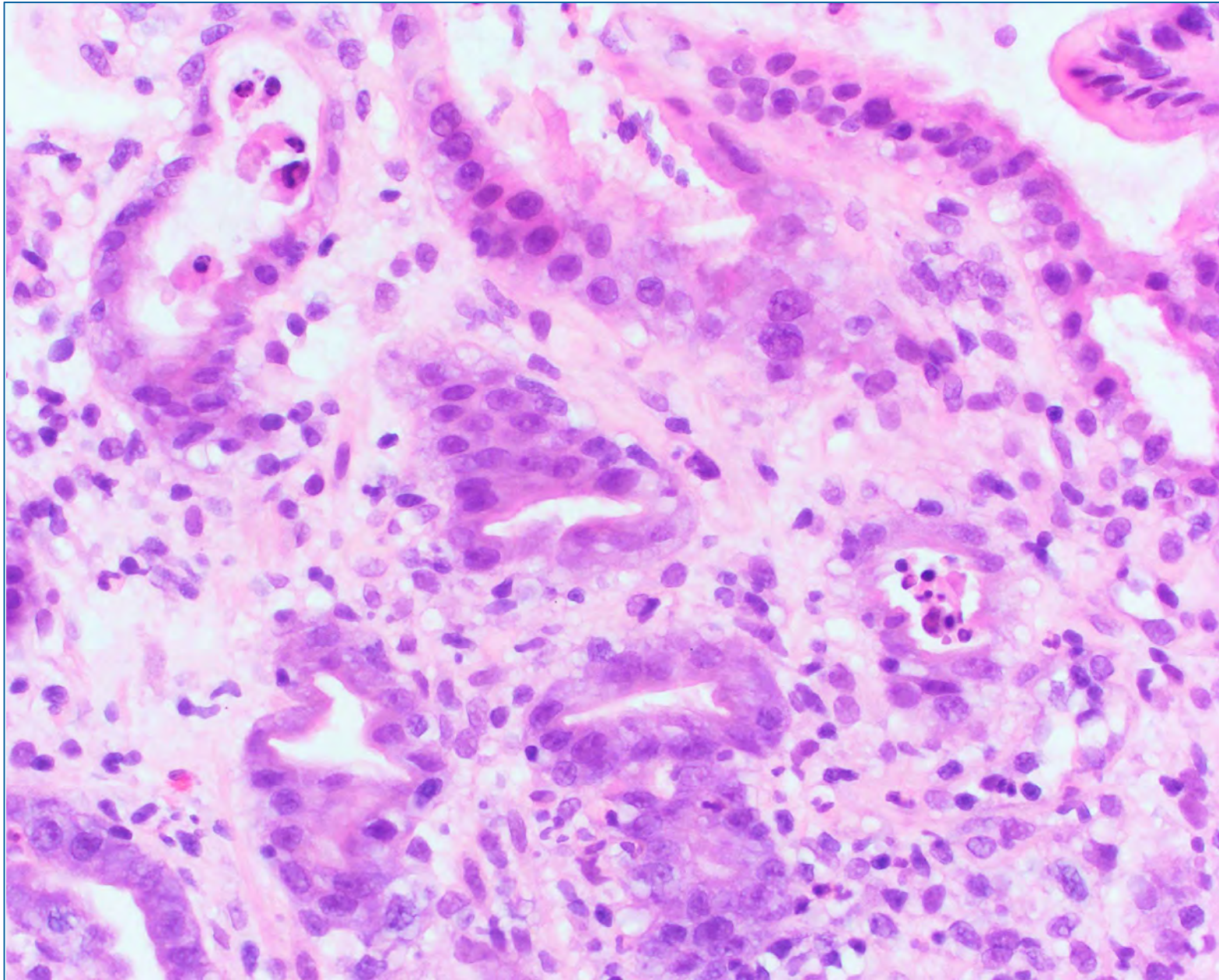
- **Patients-related factors**
  - Age >60 years
  - Female?
  - Smoking? Alcohol?
- **Drug-related factors**
  - Relative toxicity & dosage
  - Duration of usage
  - Concurrent corticosteroid use



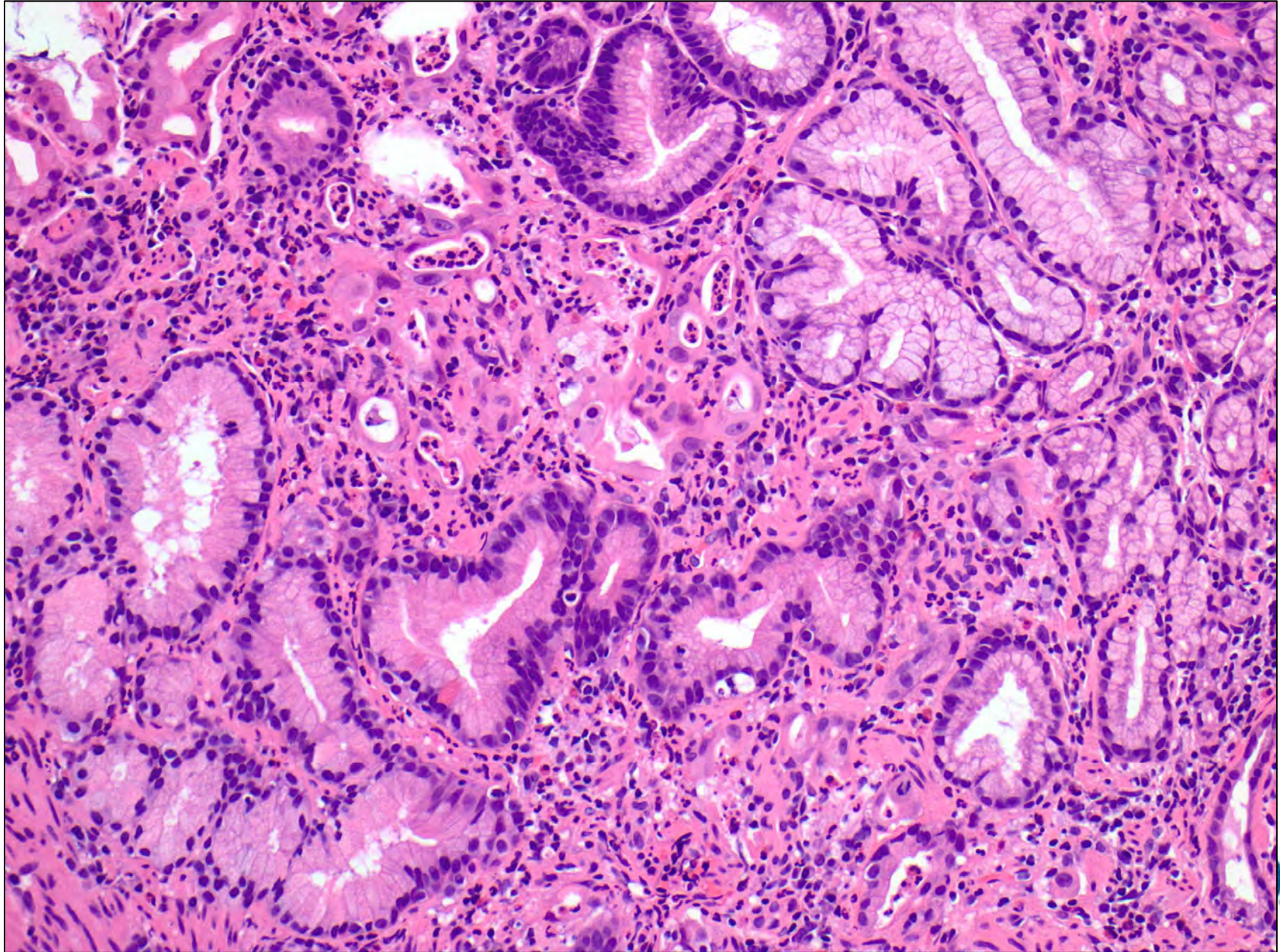
## NSAIDs gastropathy



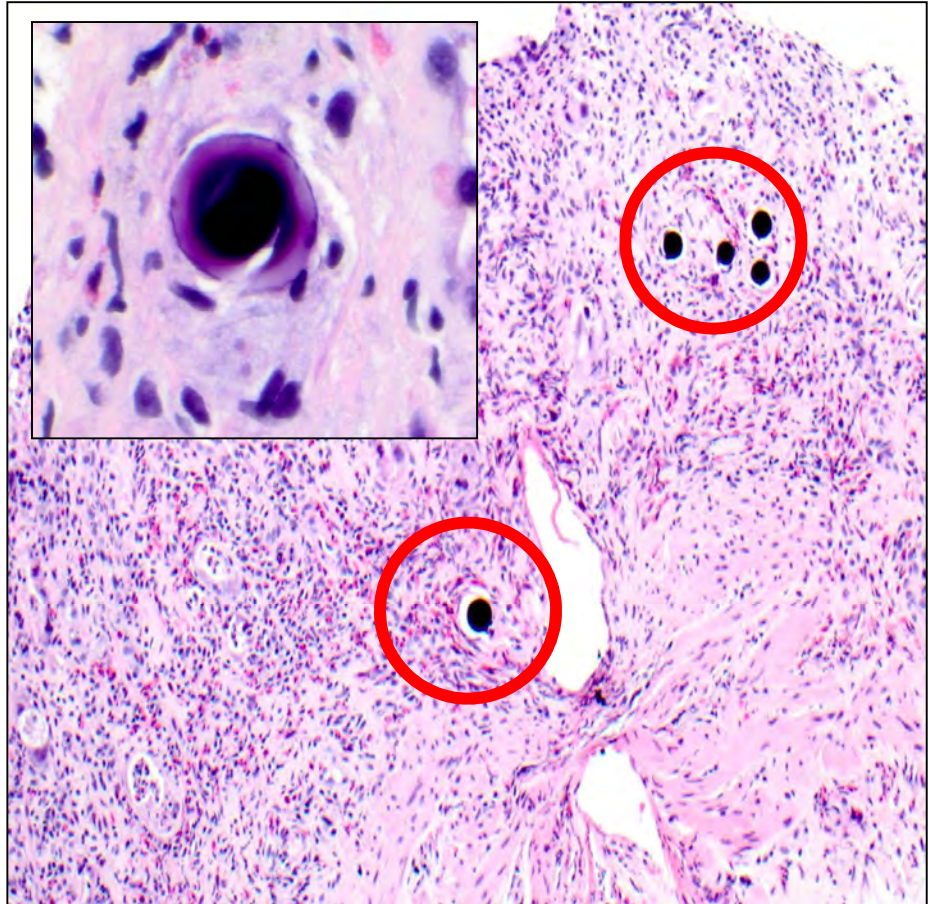
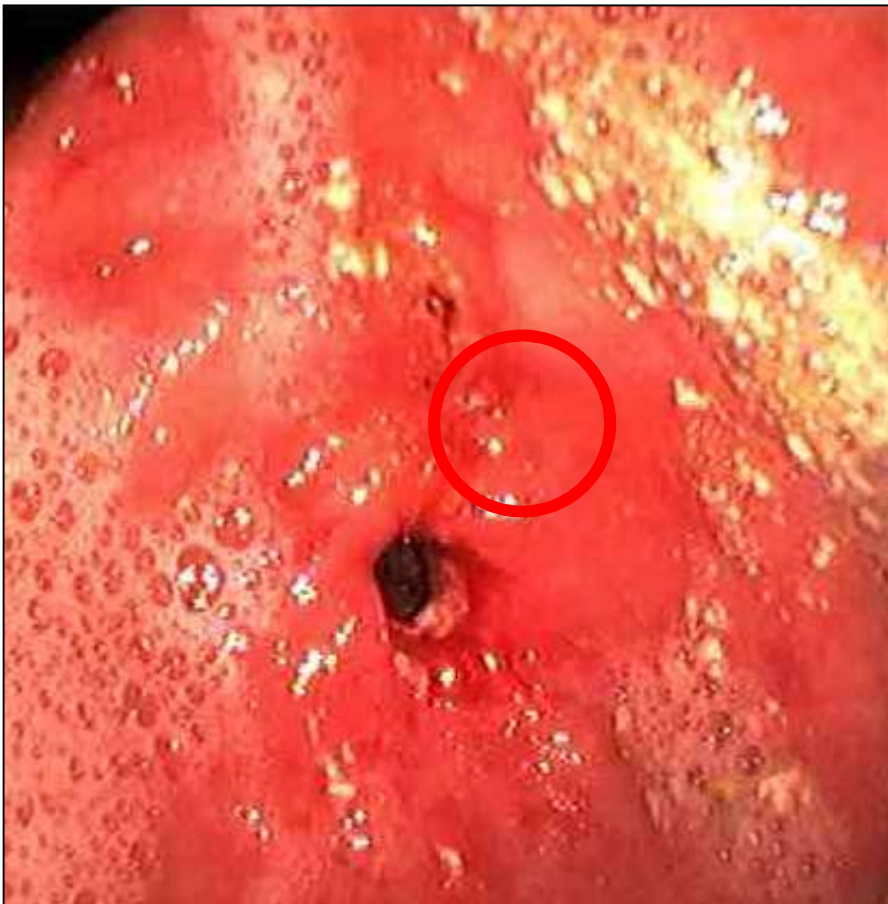# Graft-versus-host disease



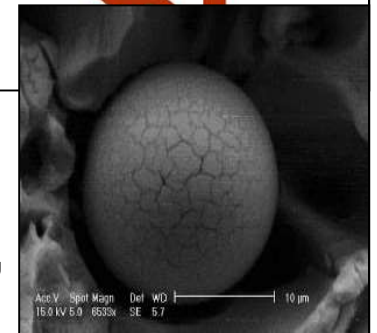
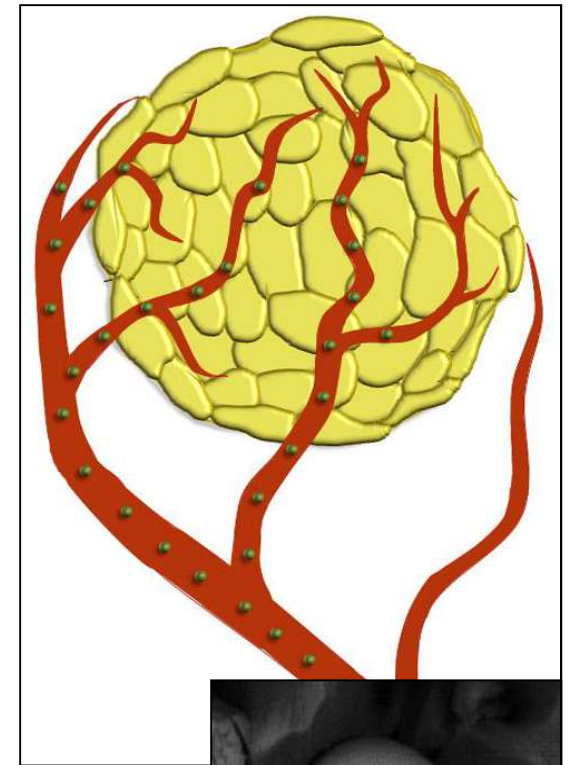
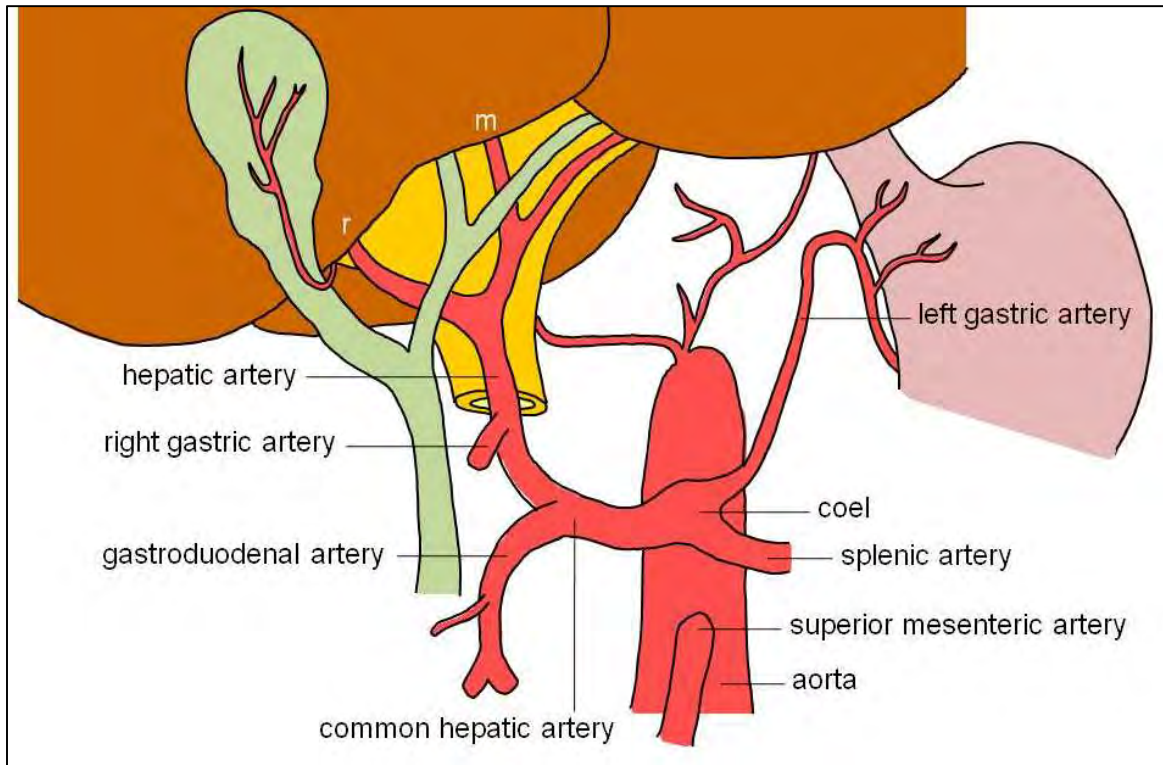
# Radiation Gastritis



# Selective Internal Radiation Therapy (SIRT)

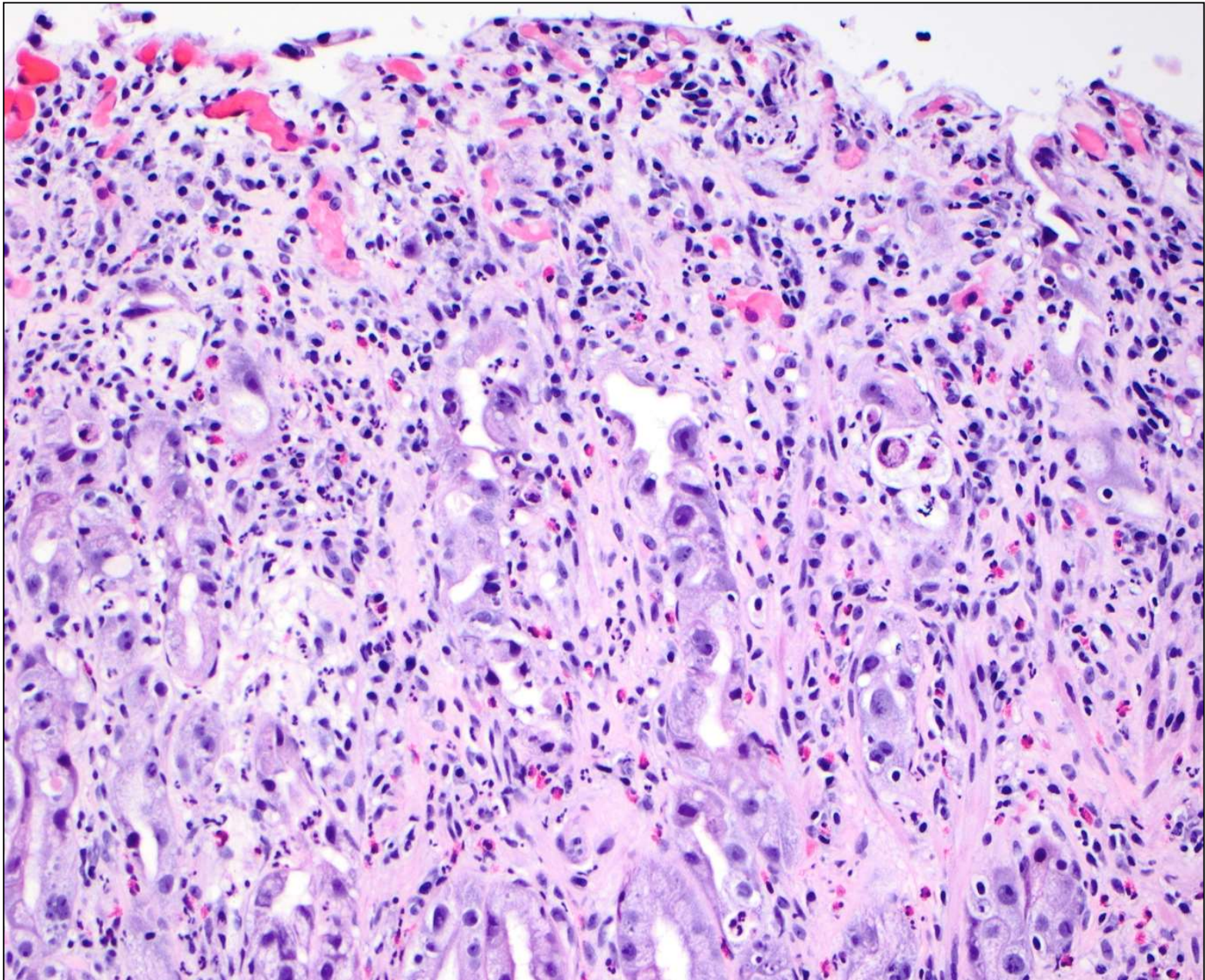


Micro-brachytherapy delivering high doses of ionizing radiation using Yttrium-90 impregnated onto 40  $\mu\text{m}$  resin microspheres



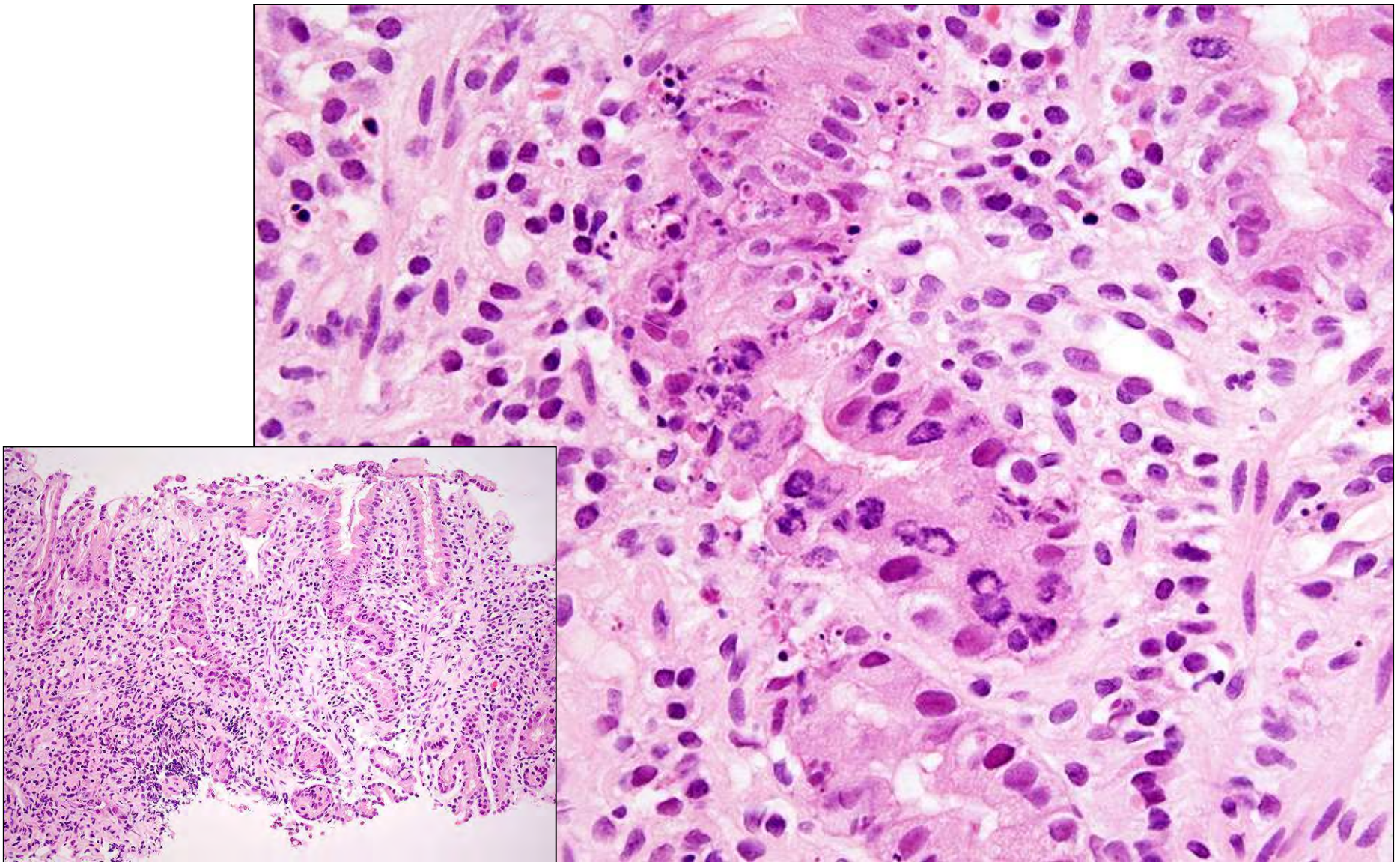
- Gastric-duod. ulceration, esophagitis, pancreatitis, hepatitis, cholecystitis.
- Incidence : 0-13% (most within the first 2 months).
  - One series of 21 pts reports up to 29% rate of gastric ulceration.

## Selective Internal Radiation Therapy (SIRT)



# Chemotherapy induced gastritis

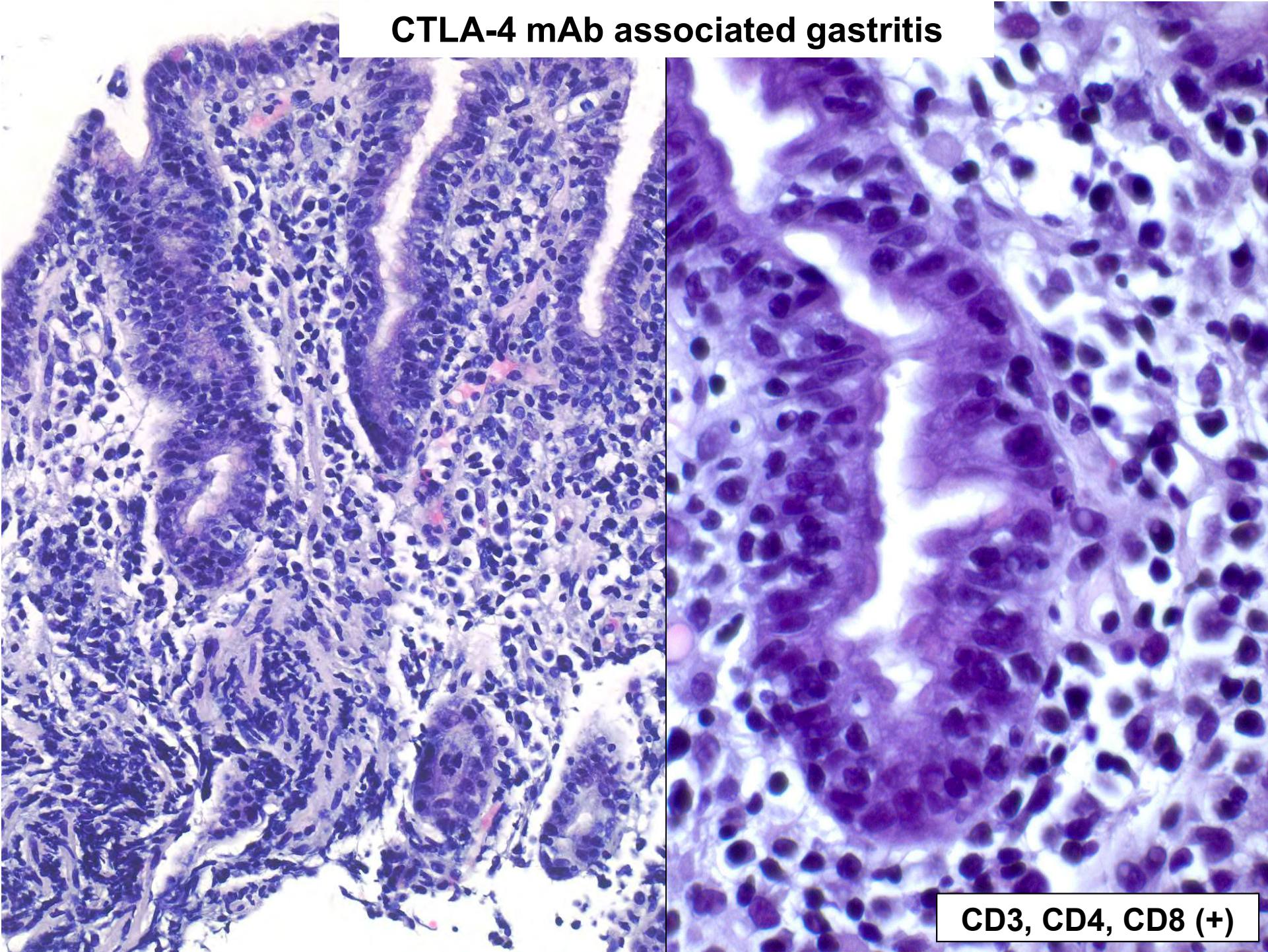
- Chemotherapy regimens: Taxol, 5-FU, others



# CTLA-4 monoclonal antibody (ipilimumab®)

- Adjuvant to tumor vaccination therapy (melanoma, RCC, ovarian Ca).
- CTLA-4 is expressed on Tregs.
  - following antigenic stimulation, CTLA-4 inhibits T cell signaling and proliferation.
- mAb against CTLA-4 result in expansion of tumor-specific T cells & enhancing tumor destruction.
- Enterocolitis: lymphoplasmacytic expansion of LP, intraepithelial lymphocytosis and apoptosis.
  - Villous blunting of small bowel /cryptitis in colon

**CTLA-4 mAb associated gastritis**



**CD3, CD4, CD8 (+)**

## Pointers for Chemo-RT induced damage

- Cytoplasmic eosinophilic transformation w/w-o  
whithering glandular structures
- Vacuolated cytoplasm
- Monster nuclei w/w-o nucleoli intermixed w/ normal  
nuclei
- Apoptosis
- Mitotic arrest and atypical mitotic figures
- Eosinophilic inflammation; Lymphocytic exocytosis
- Stromal edema or fibrosis; Ectatic capillary vessels

## GASTRITIS WITH GRANULOMATOUS INFILTRATION OF THE LAMINA PROPRIA

Crohn's disease

Sarcoidosis

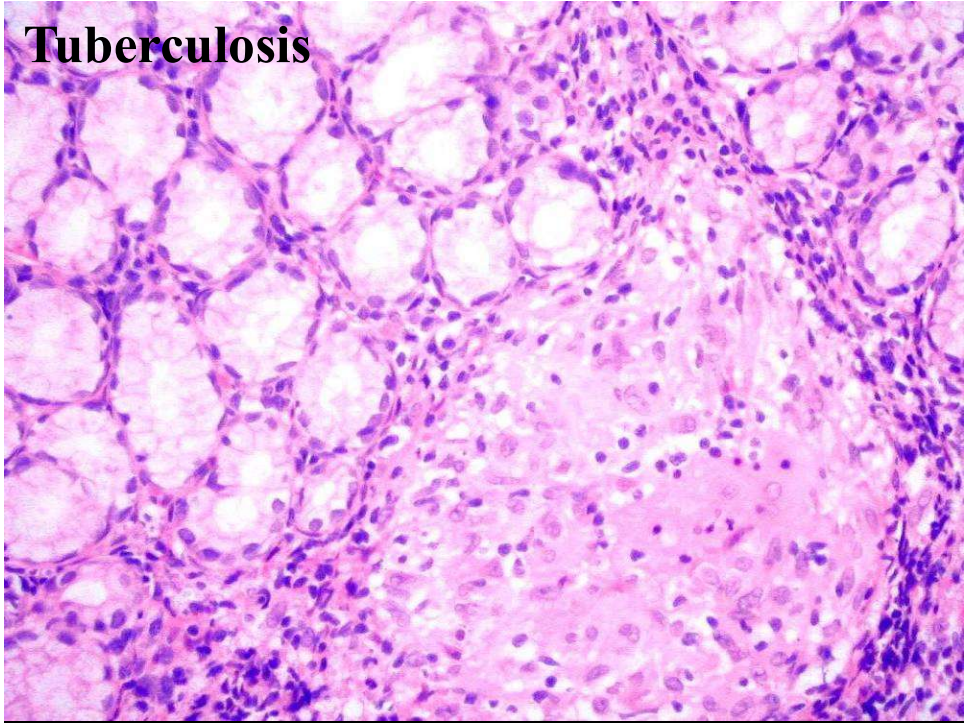
Infectious etiologies:

Tuberculosis  
Cryptococcus  
Anisakiasis  
Taeniasis

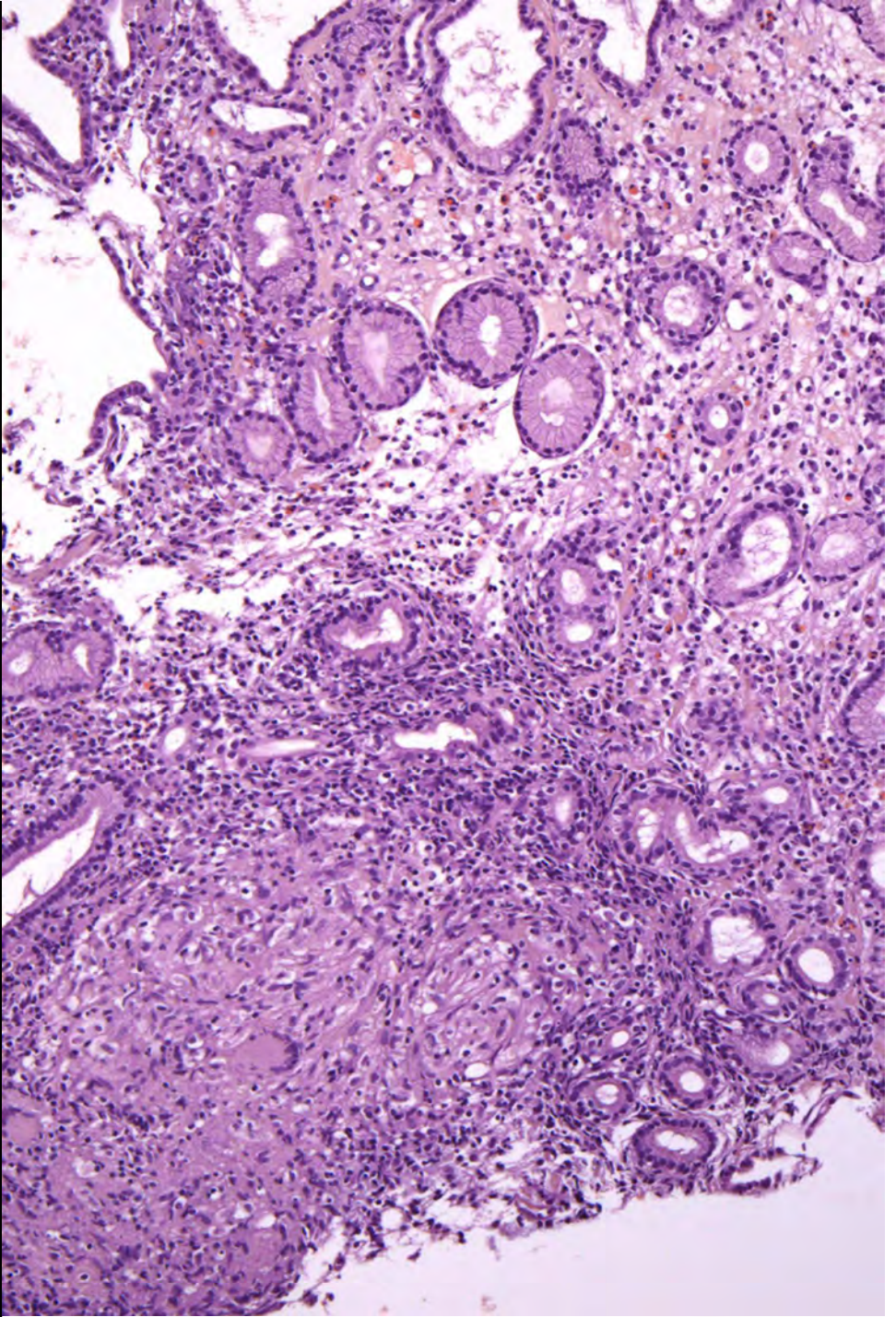
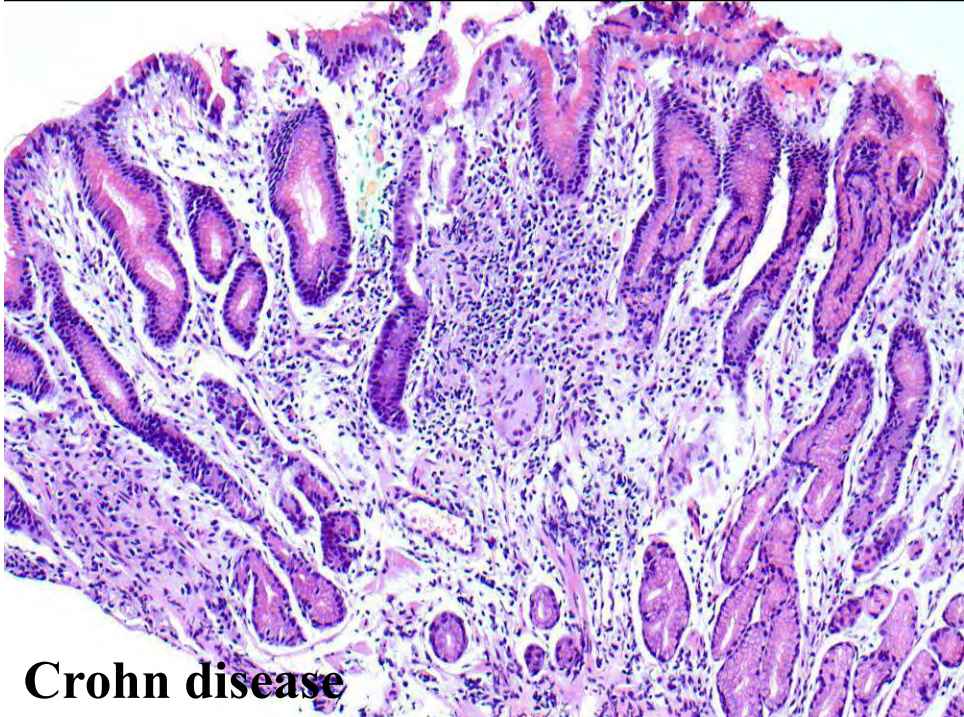
Other uncommon etiologies:

Gastric adenocarcinoma  
Chronic granulomatous disease  
Common variable immunodeficiency  
Langerhans cell histiocytosis  
Whipple's disease  
Vasculitis  
Xanthogranulomatous gastritis  
Foreign body reaction

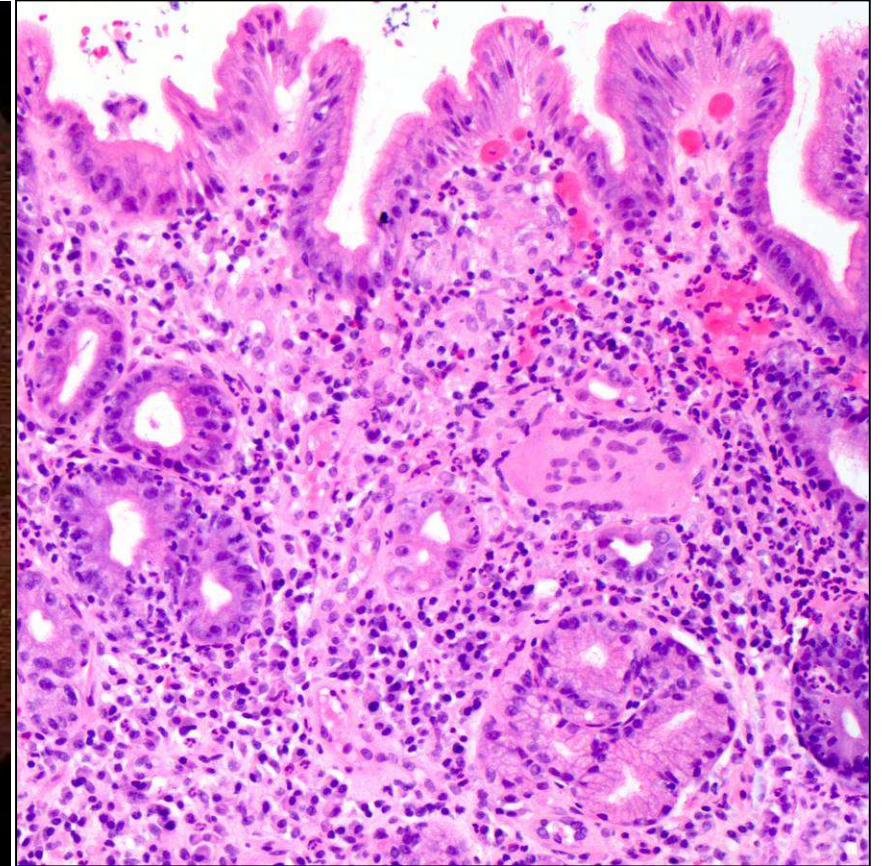
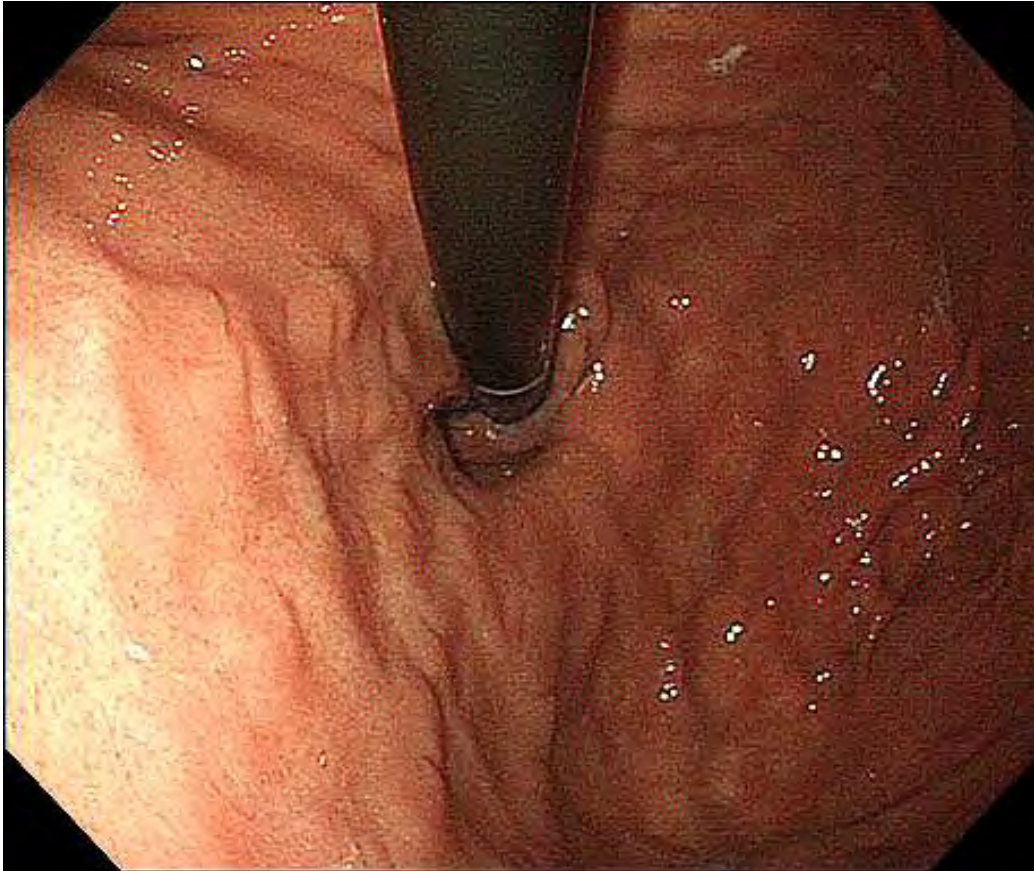
**Tuberculosis**



**Crohn disease**



# Gastric manifestations of Crohn



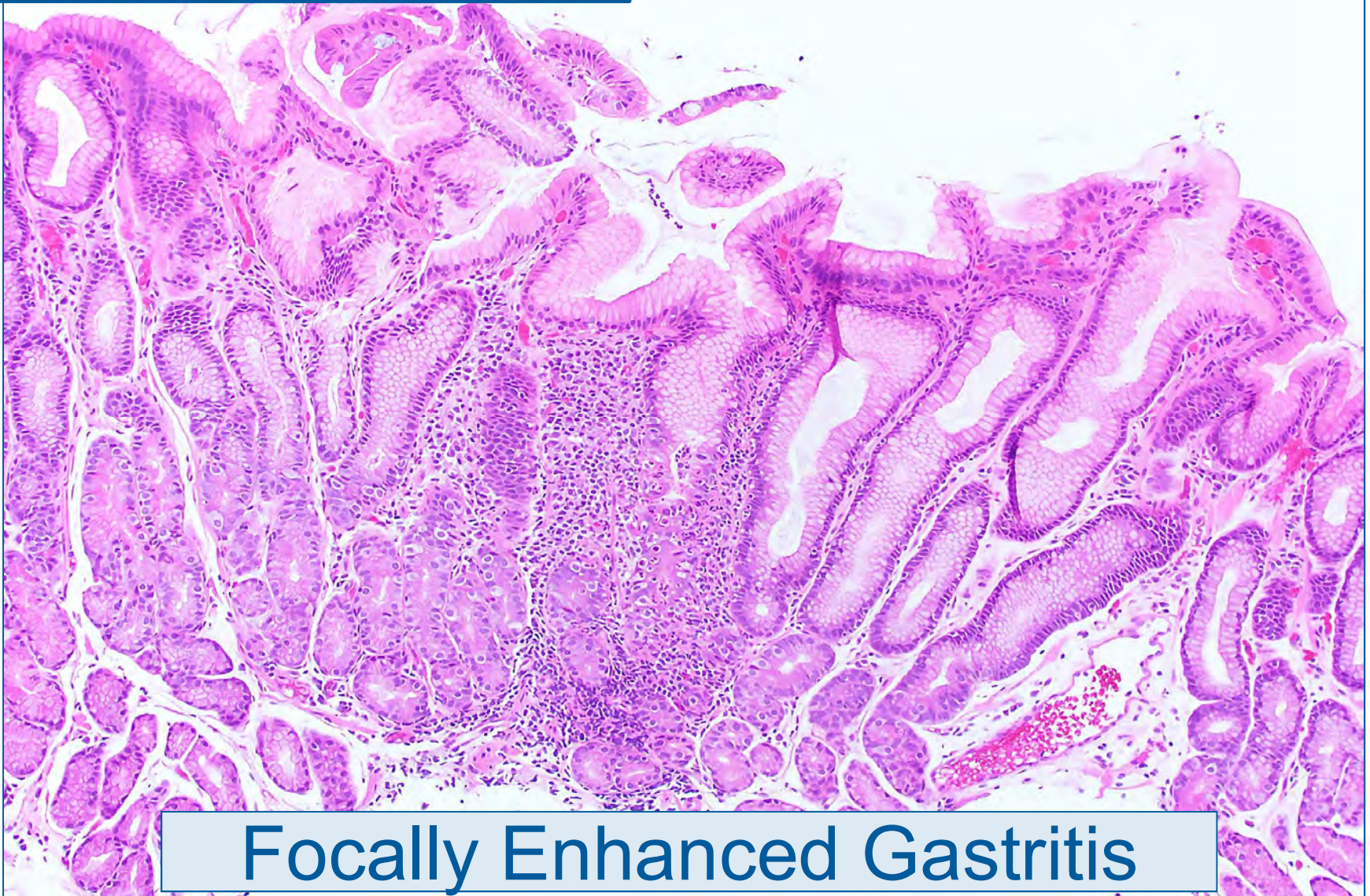- Clinical:
  - Up to 34%-83% (referral centers / endoscopy+histology)
- Endoscopy:
  - Normal.
  - Nodular, thickened folds.

FEG and/or granulomas:  
8-75% of pts.

Exclude HP (incompletely treated)

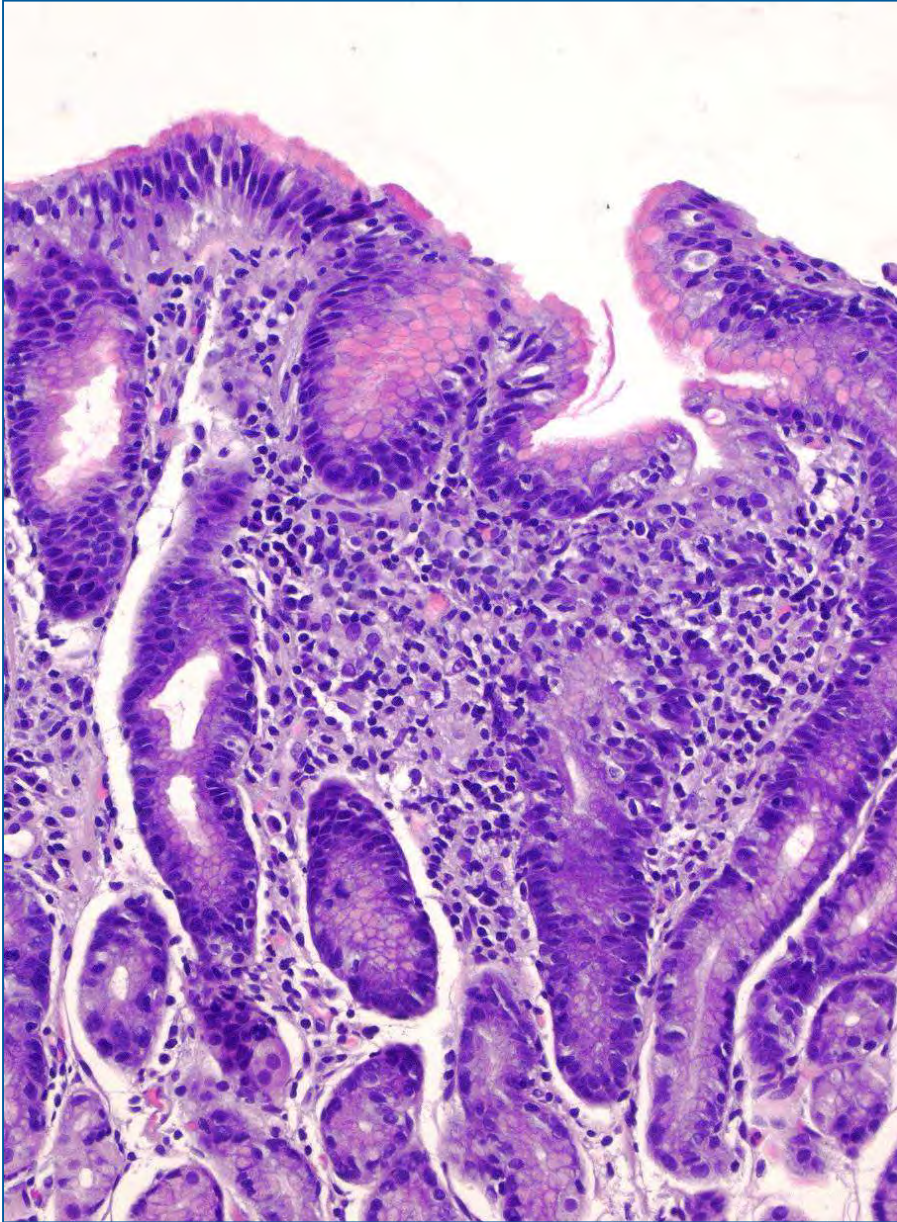
BMT; Autistic children

**IBD**



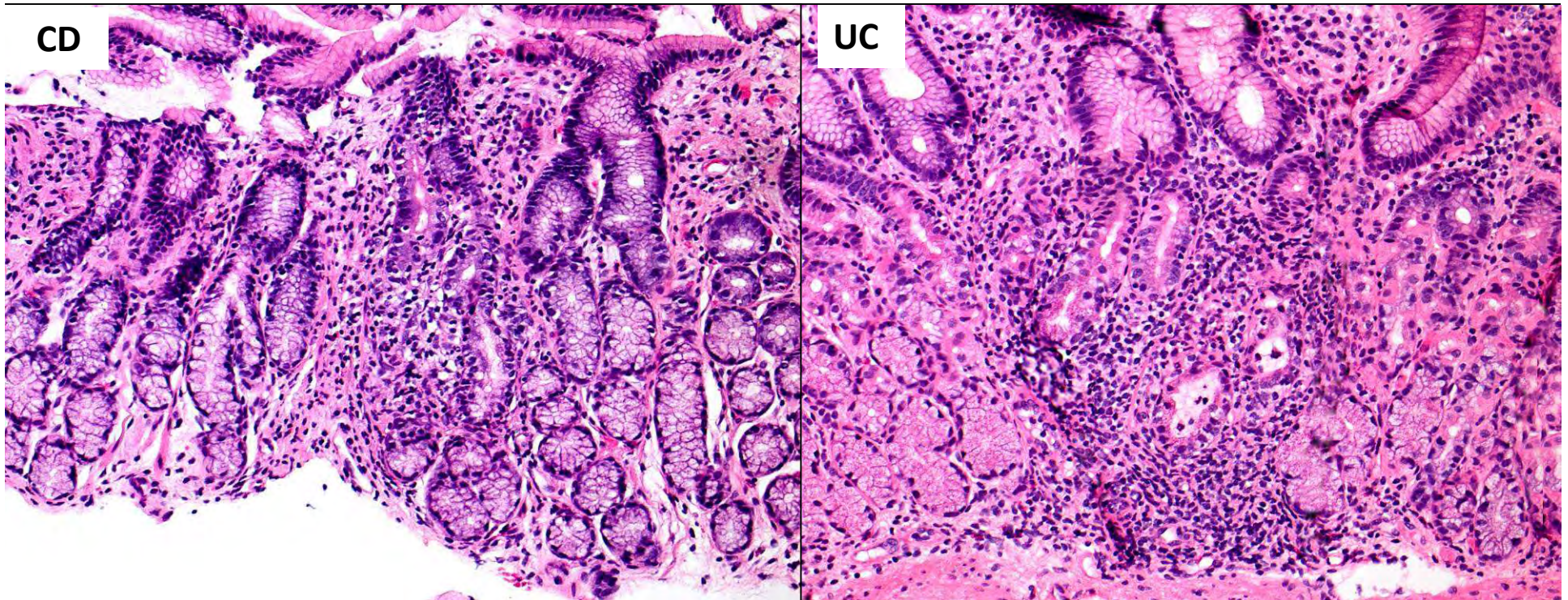
**Focally Enhanced Gastritis**

# Focally Enhanced Gastritis



- Predominantly composed of CD3+ T cells & CD68+ histiocytes w/ occasional neutrophils (62% of cases).
- Single lesion (73.5%) involving 2-8 glands.
- Antrum >>> body-fundus

# Focally Enhanced Gastritis



- Number of glands involved in FEG foci:
  - UC (6.4 $\pm$ 5.1 glands) v. CD (4.0 $\pm$ 3.0 glands) [ $p=0.0465$ ]
- Granulocytic infiltrates
  - more common in UC (47%) than in CD (24%) [ $p>0.05$ ]

119 pts:62 CD / 57 UC

## Focally Enhanced Gastritis

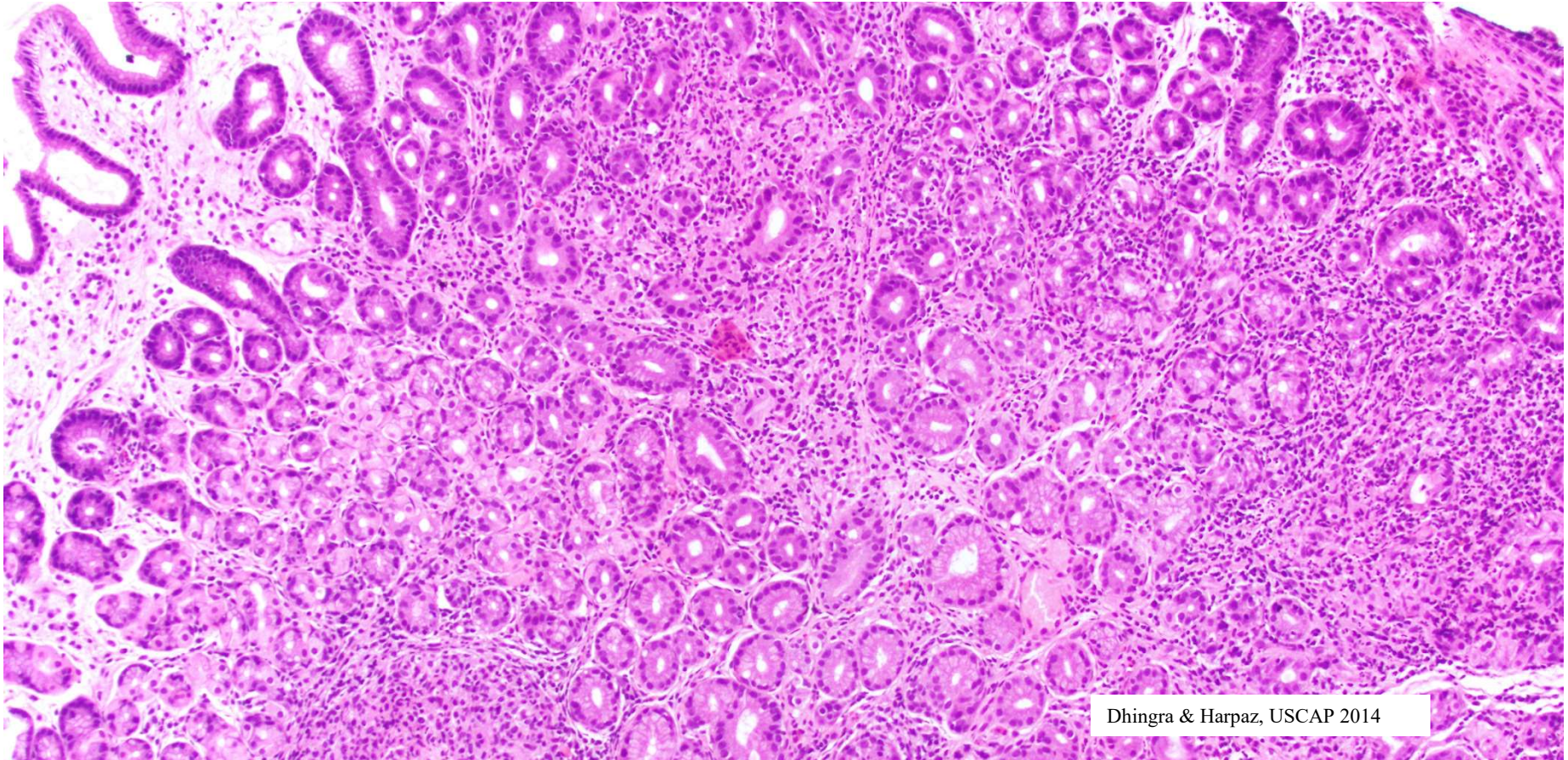
	All patients			Pediatric Pts		
	UC	CD	Control	UC	CD	Control
<b>Prevalence</b>	12- 24%	43 - 76%	2-19%	21-30%	55-69%	3-5%
<b>PPV of IBD</b>	5.9%			61-76%		

- More common in yg pts: 73% at age 10 VS 43% >10, ( $p=0.0358$ ) w/ peak in the 5-10 years age-group (80%)
- Associated w/ the presence of granulomas in the entire gut [ $p=0.0006$ ]
- Prevalence of active SB inflammation is higher in FEG group (62%) v. non-FEG (36%) [ $p=0.0412$ ]

Ushiku T. 2013. Am J Surg Pathol

McHugh et al. Am J Surg Pathol, 2013.

Xin et al. Am J Surg Pathol 2004, 28(10): 1347-51



Dhingra & Harpaz, USCAP 2014

	<b>CAG, focal PMN</b>	<b>CAG diffuse PMN infiltration</b>	<b>Chronic inactive gastritis</b>	<b>FEG-N</b>	<b>FEG-G</b>	<b>Granulomas</b>	<b>Lymphoid follicles</b>
<b>CDG (n=82)</b>	<b>40%</b>	<b>13%</b>	<b>34%</b>	<b>13%</b>	<b>44%</b>	<b>20%</b>	<b>13%</b>

CAG: chronic active gastritis; FEG: focally enhanced gastritis; PMN: polymorphonuclear; N; Normal; G: gastritis.

# Granulomatous Gastritis

Reported in **0.08%-0.35%** of gastric bx.

## • Infectious

- Mycobacterial infection.
- Candida, Aspergillosis.
- Mucormycosis.
- Histoplasmosis.
- Blastomycosis.
- Anisakis, Strongyloides stercoralis
- Schistosoma mansoni.

## • Non Infectious

- Crohn's disease.
- Sarcoidosis.
- Foreign body.
- Cancer.
- CGD
- Idiopathic.

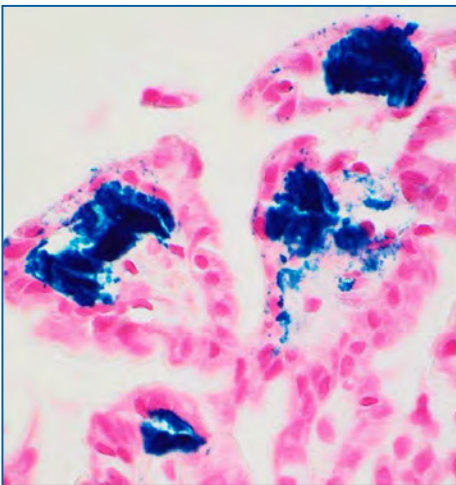
- ***Granulomas vary in number, size, location, and composition. Usually do not display distinctive morphology specific for an etiology.***
- Special stains and examination under polarized light may be helpful.
- Clinical & serological correlation fqt<sup>ly</sup> needed to identify the etiology.

- Antrum > corpus
- Thickened mucosal folds
- Gastric outlet obstruction (R/O CA, lymphoma)

## GASTRITIS WITH CRYSTAL OR PIGMENT DEPOSITION

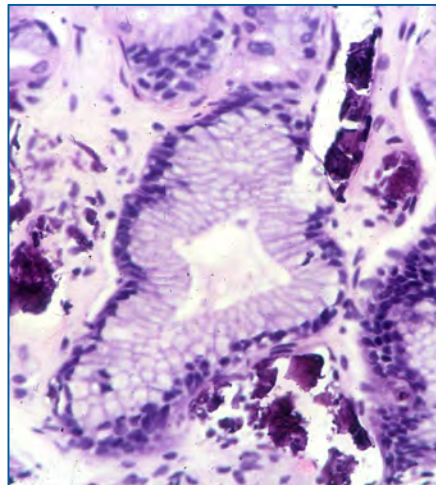
### Iron-pilled gastritis:

Golden brown pigment in a background of reactive gastropathy-type changes



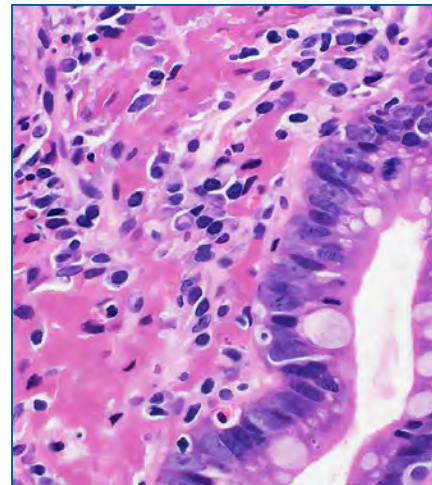
### Gastric mucosa calcinosis:

Dark pink to purple, partially calcified, refractile crystals just beneath the surface epithelium



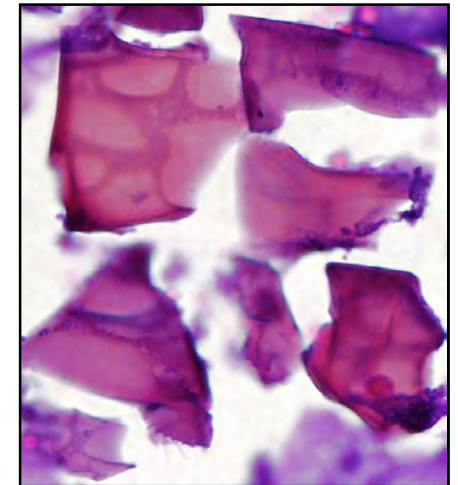
### Lanthanum carbonate:

Fine, granular, brownish material in the cytoplasm of histiocytes

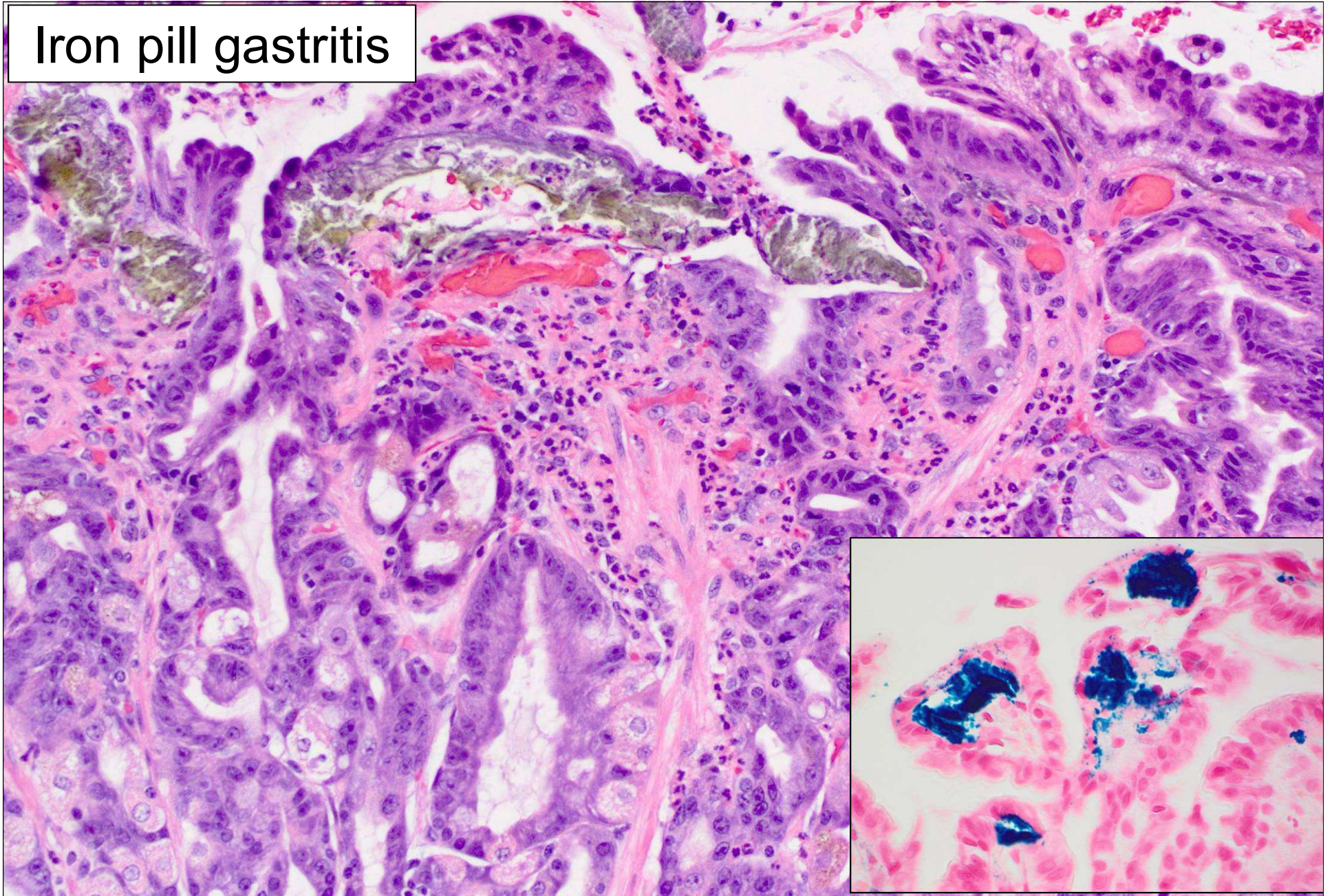


### Kayexalate in sorbitol:

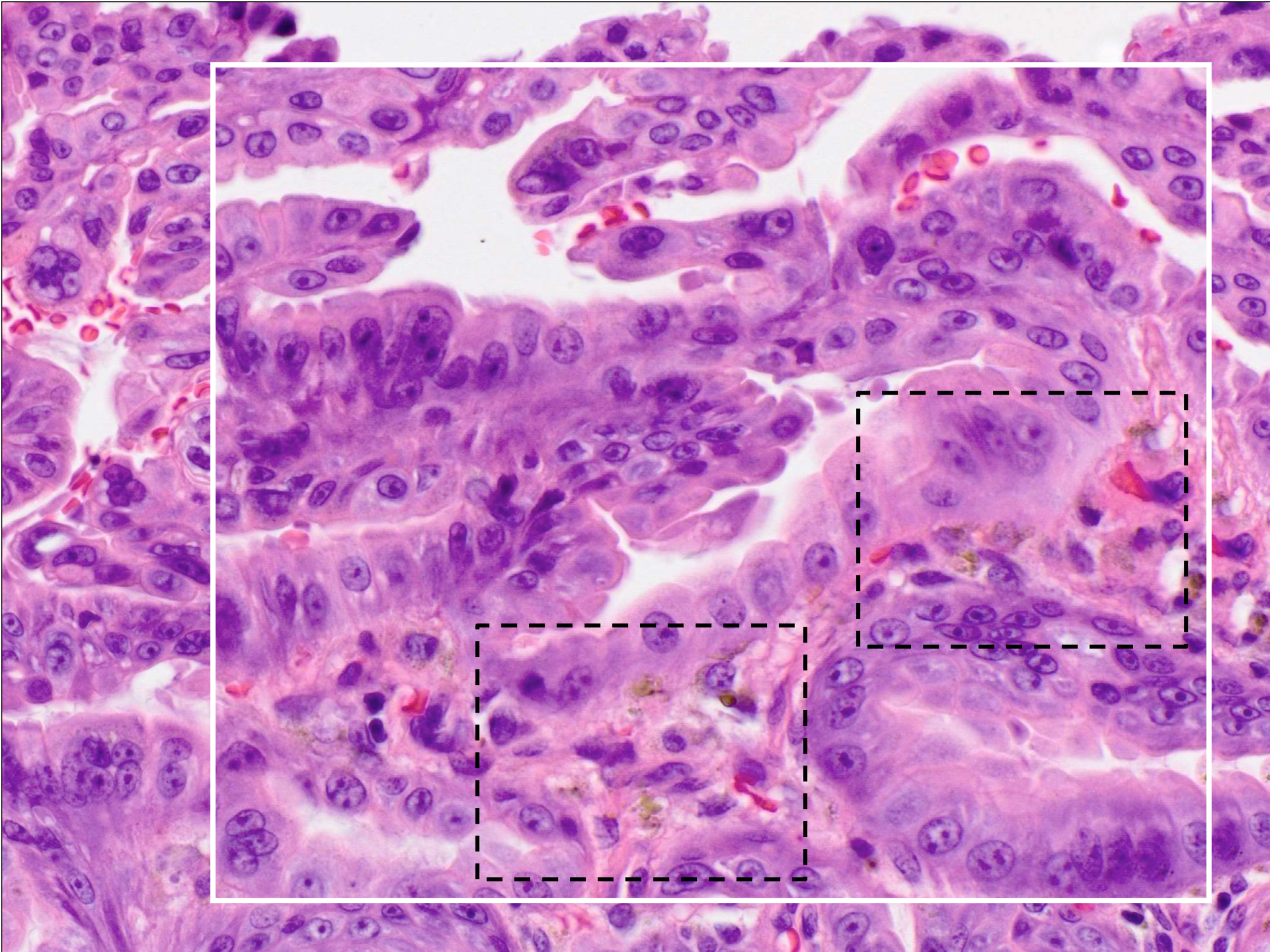
Slightly basophilic, rhomboid or triangular in shape with a characteristic mosaic pattern



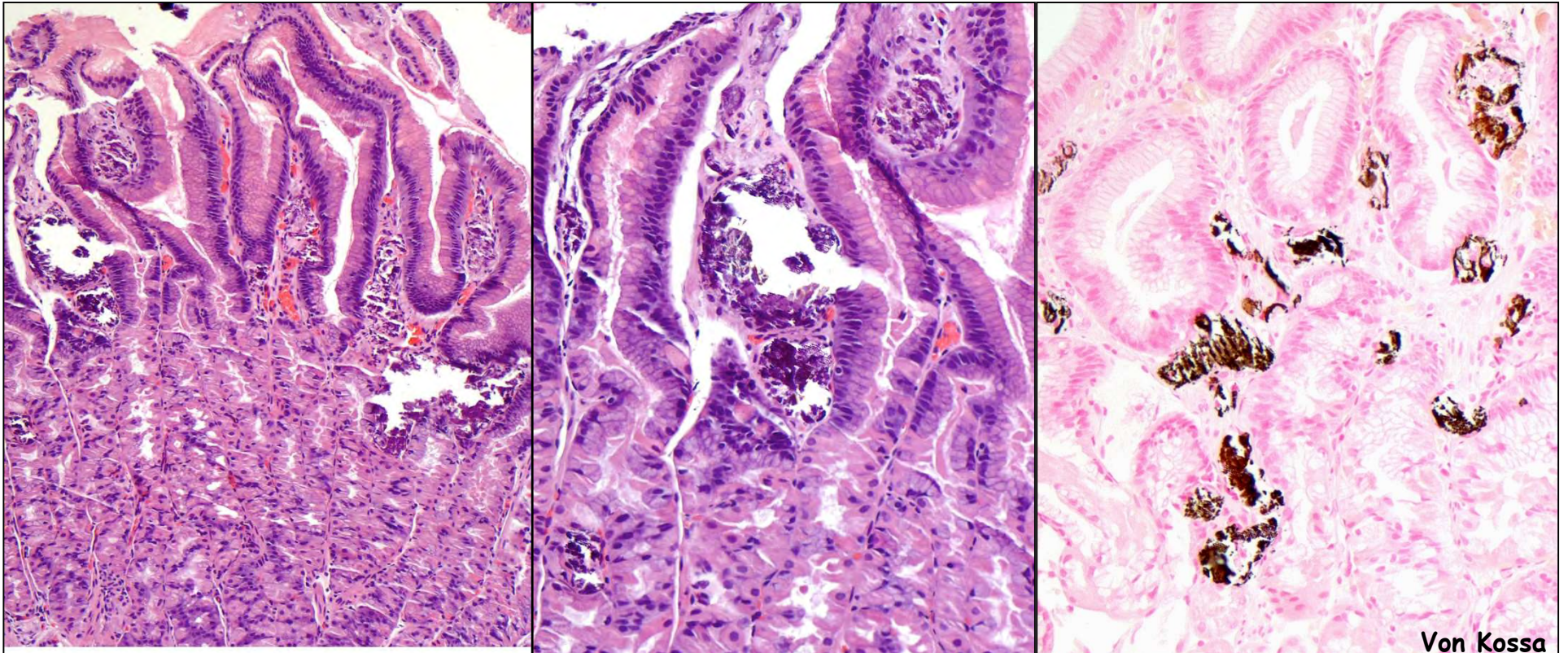
## Iron pill gastritis



- *Erosions, foveolar hyperplasia, hyperplastic-type polyps, infarct-like necrosis.*

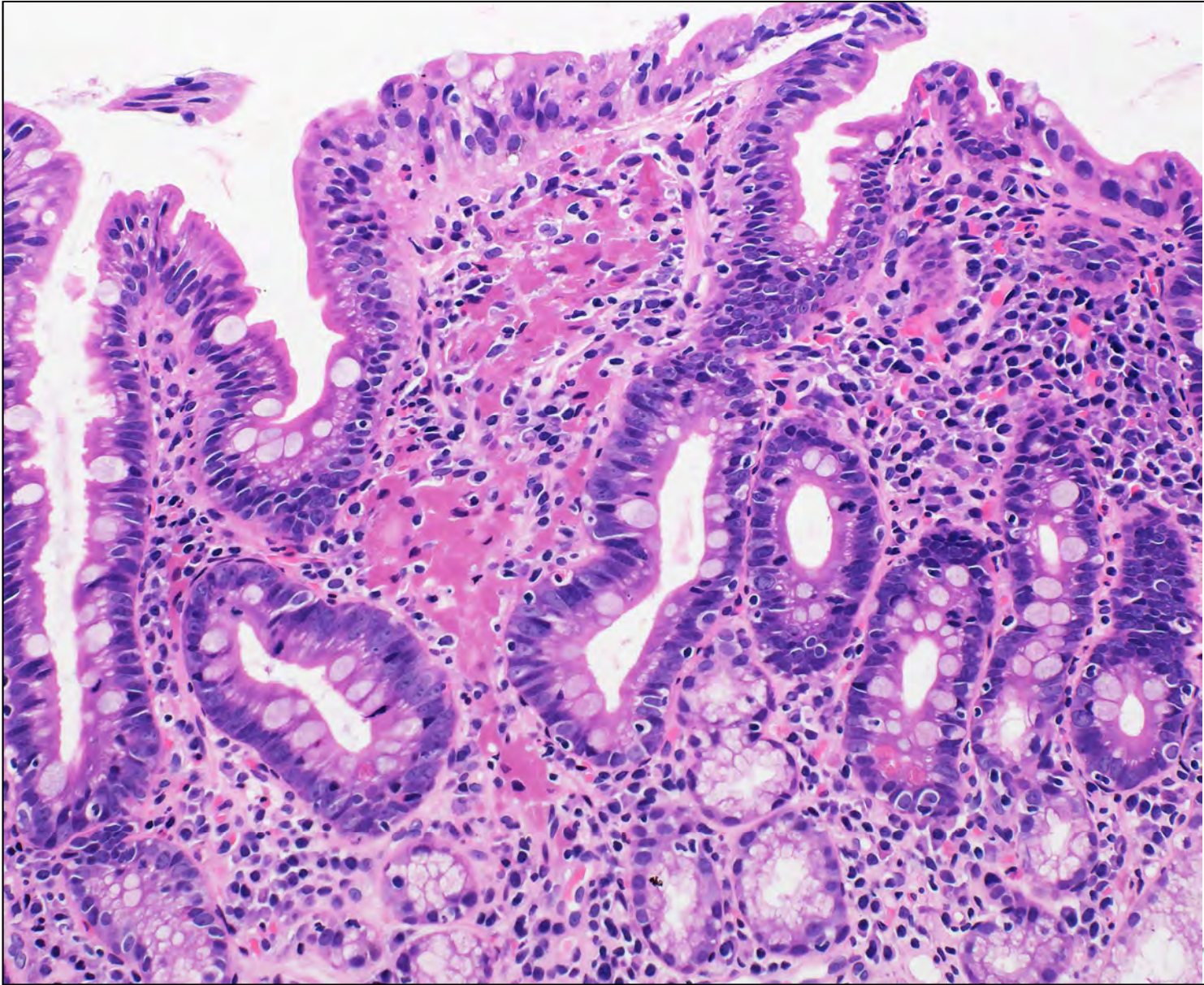


# Gastric Mucosal Calcinosis



- Organ transplant patients (renal+)
- Aluminum hydroxide-containing antacid or sucralfate.
- Elemental analysis: aluminium, chlorine, calcium, phosphorus

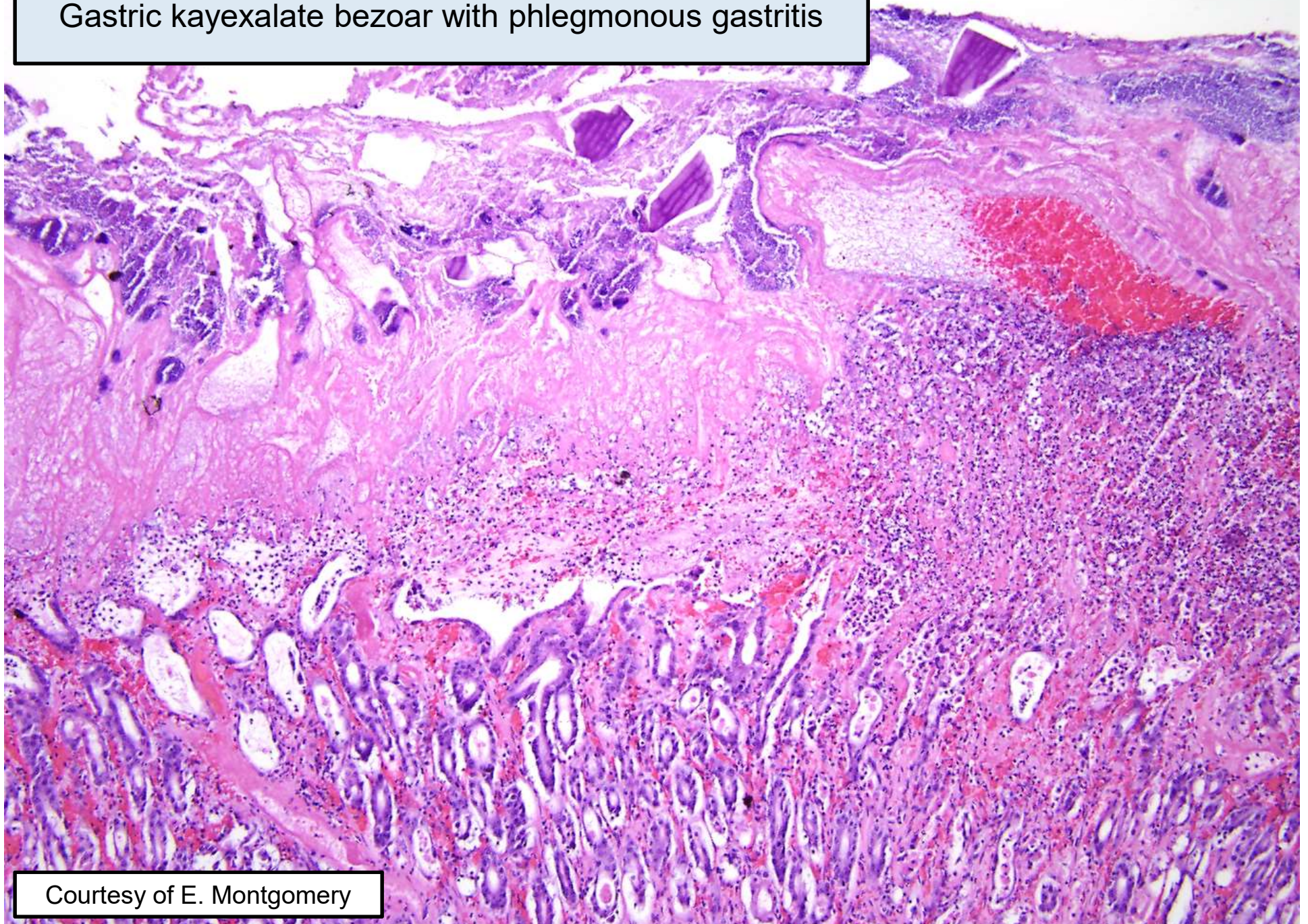
# Lanthanum carbonate



phosphate binder for the treatment of hyperphosphatemia in dialysis patients

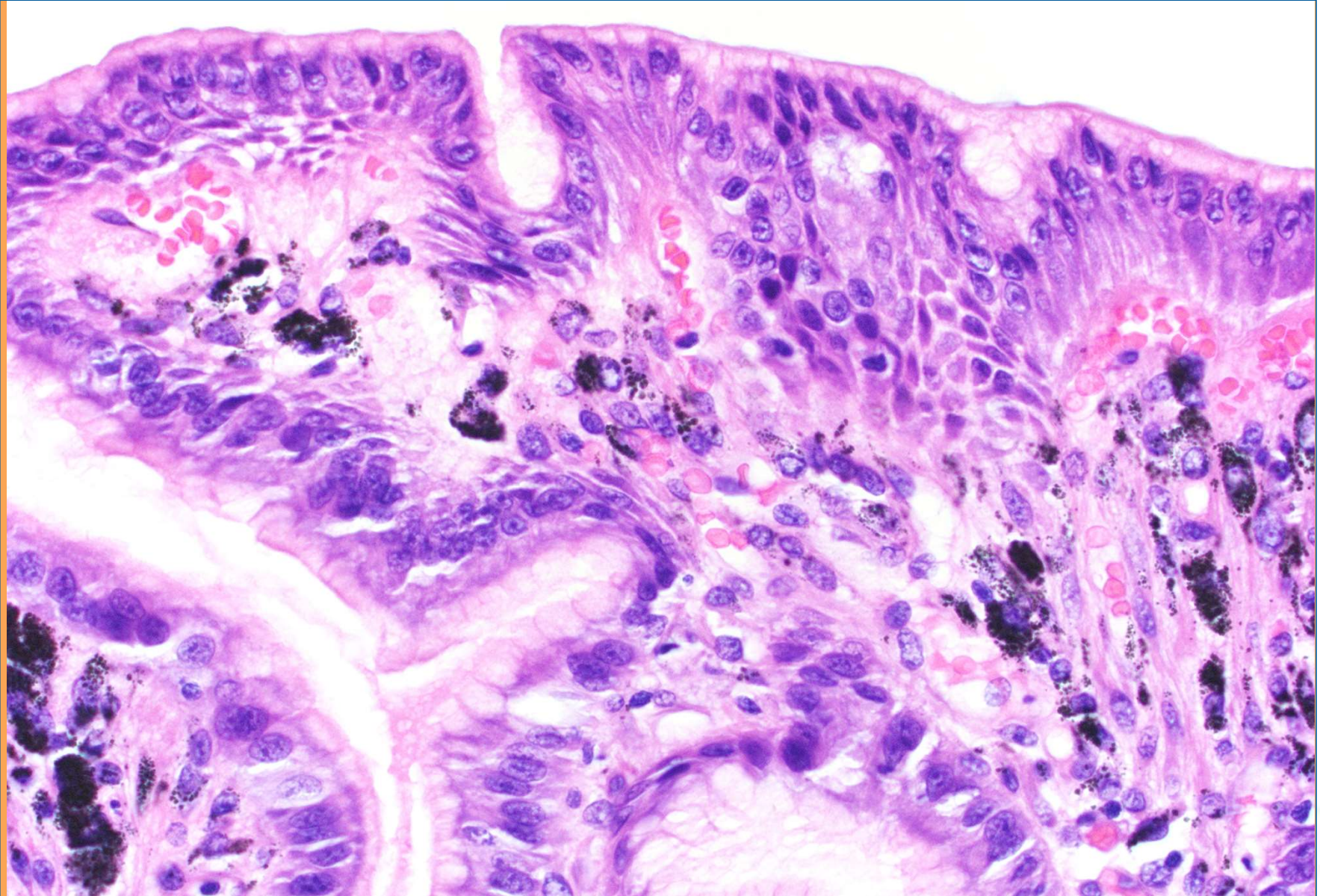


Gastric kayexalate bezoar with phlegmonous gastritis



Courtesy of E. Montgomery

## Titanium from toothpaste



# Thank You!

