

An Algorithmic approach to neoplasms of the pancreas- Ductal adenocarcinoma vs. chronic pancreatitis



JOHNS HOPKINS
MEDICAL INSTITUTIONS

February 2017

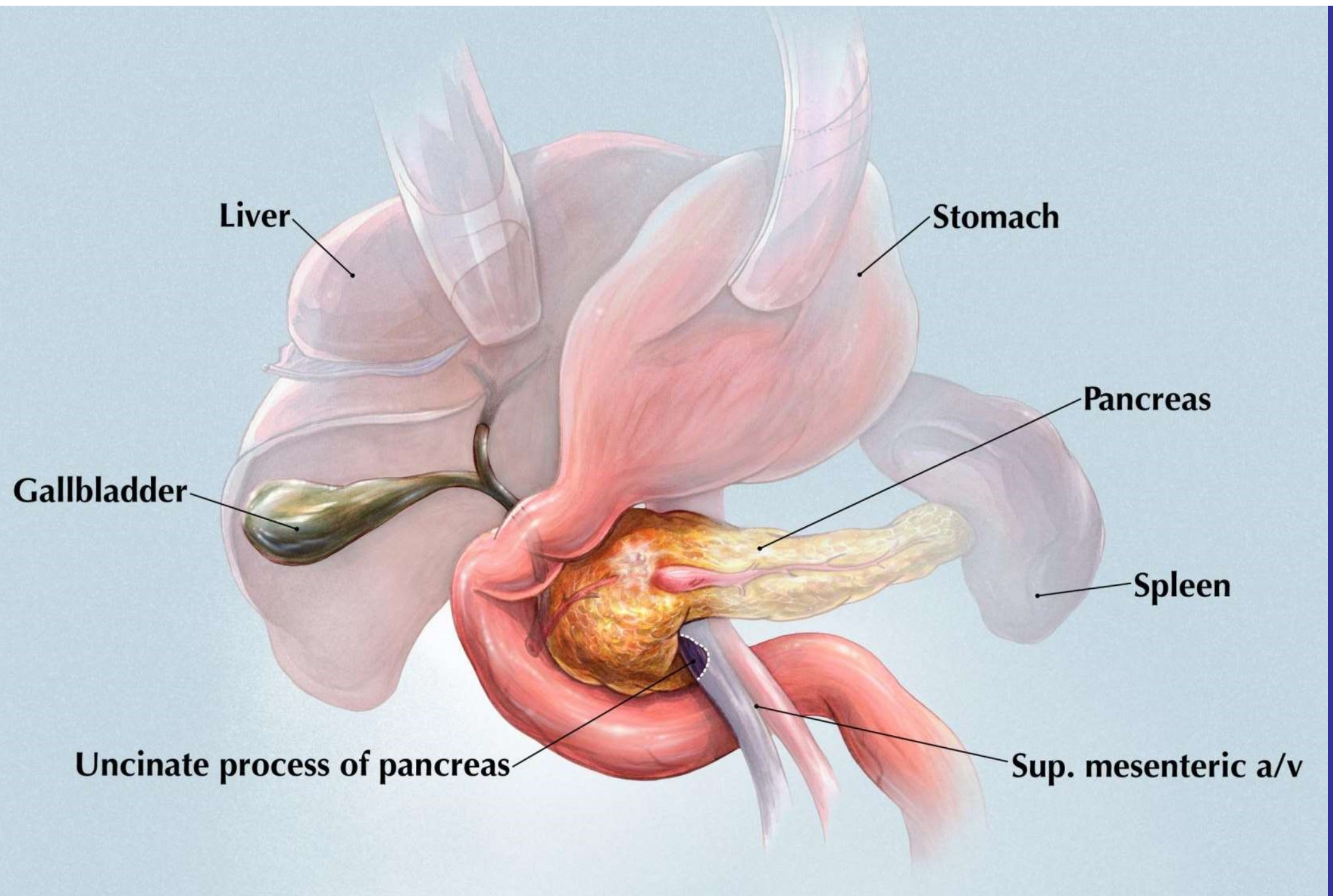
Ralph H. Hruban, M.D.

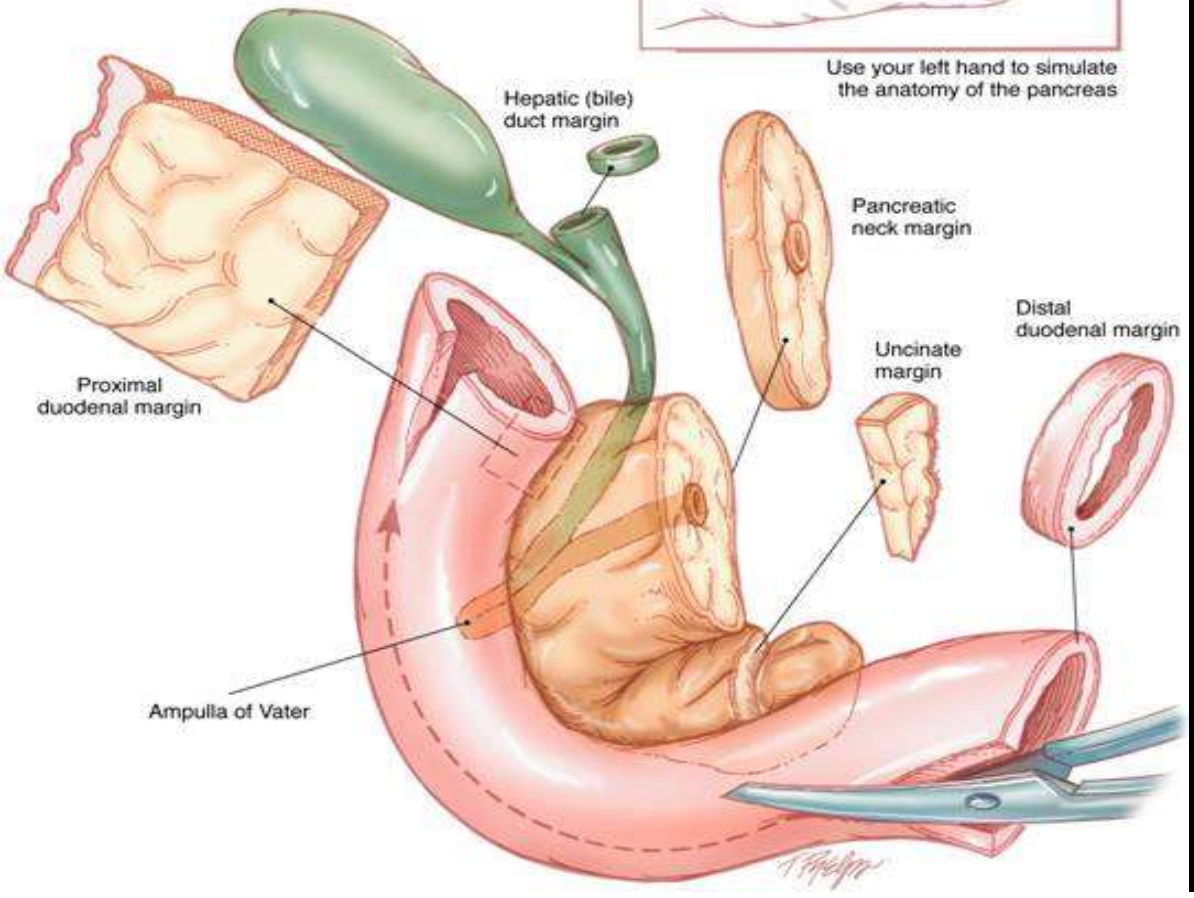
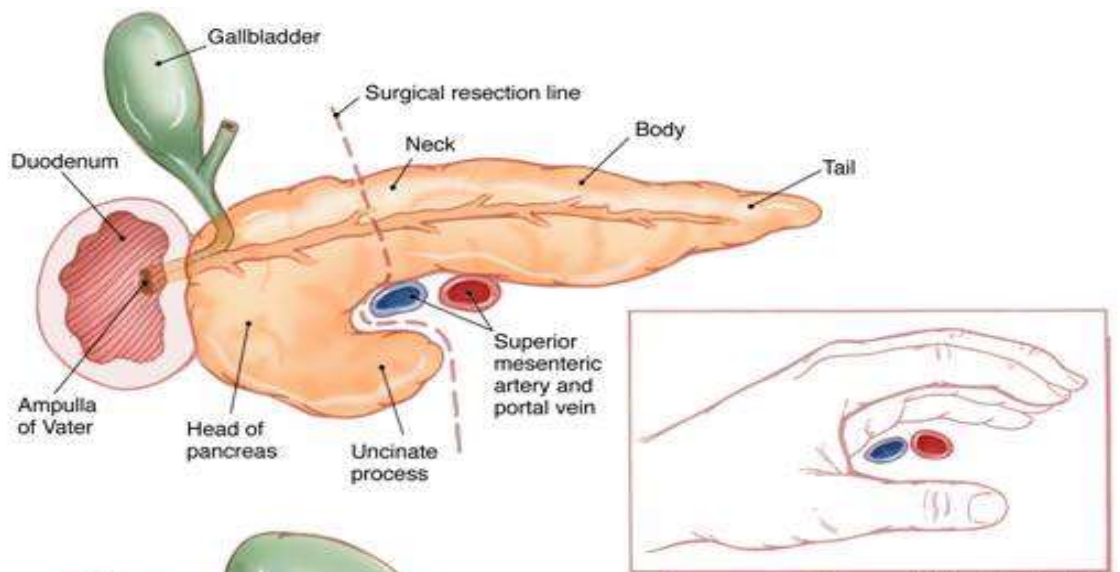
Professor and Director of Pathology
The Sol Goldman Pancreatic Cancer Research Center
The Johns Hopkins Medical Institutions

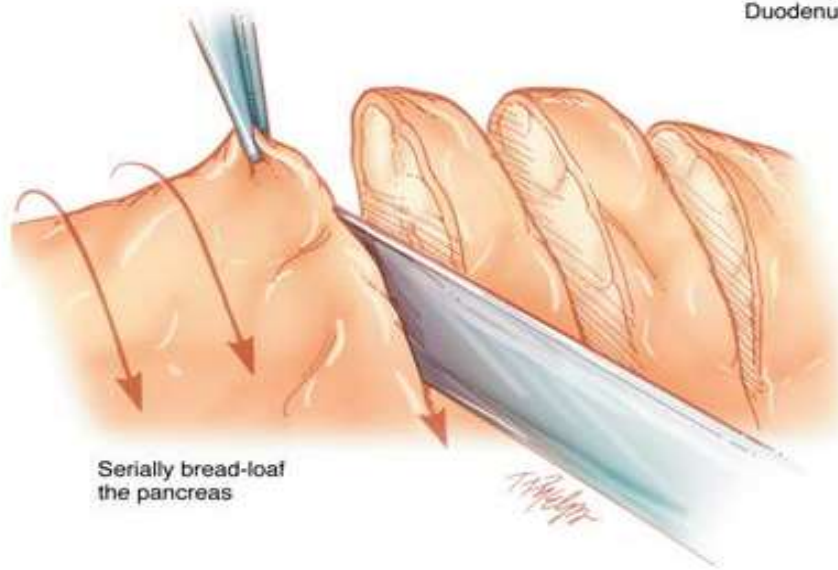
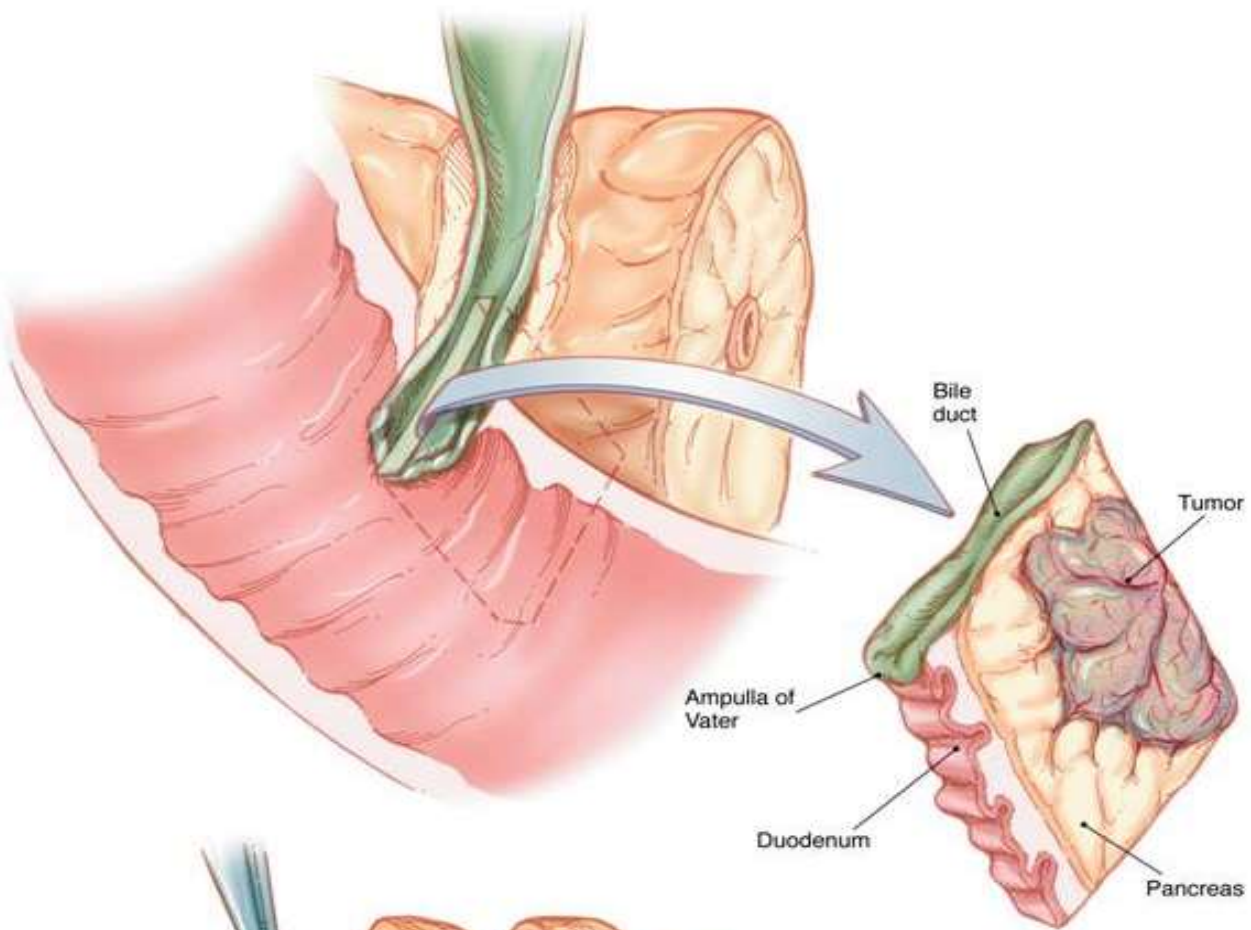
Disclosure

- I receive royalty payments from Myriad Genetics for the PALB2 invention.
- Selected images from the AFIP Fascicle with permission

Grossing







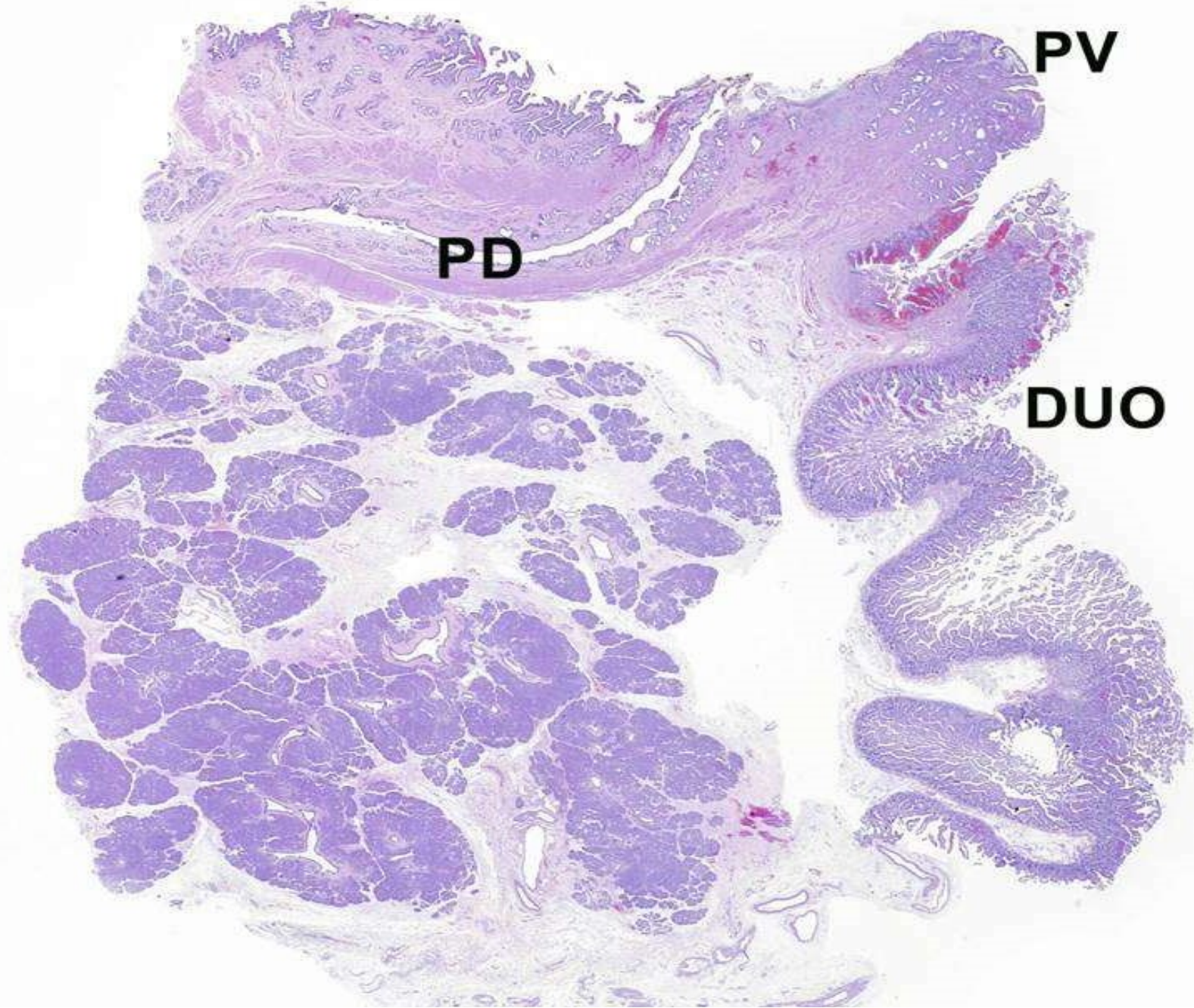
Serially bread-loaf the pancreas

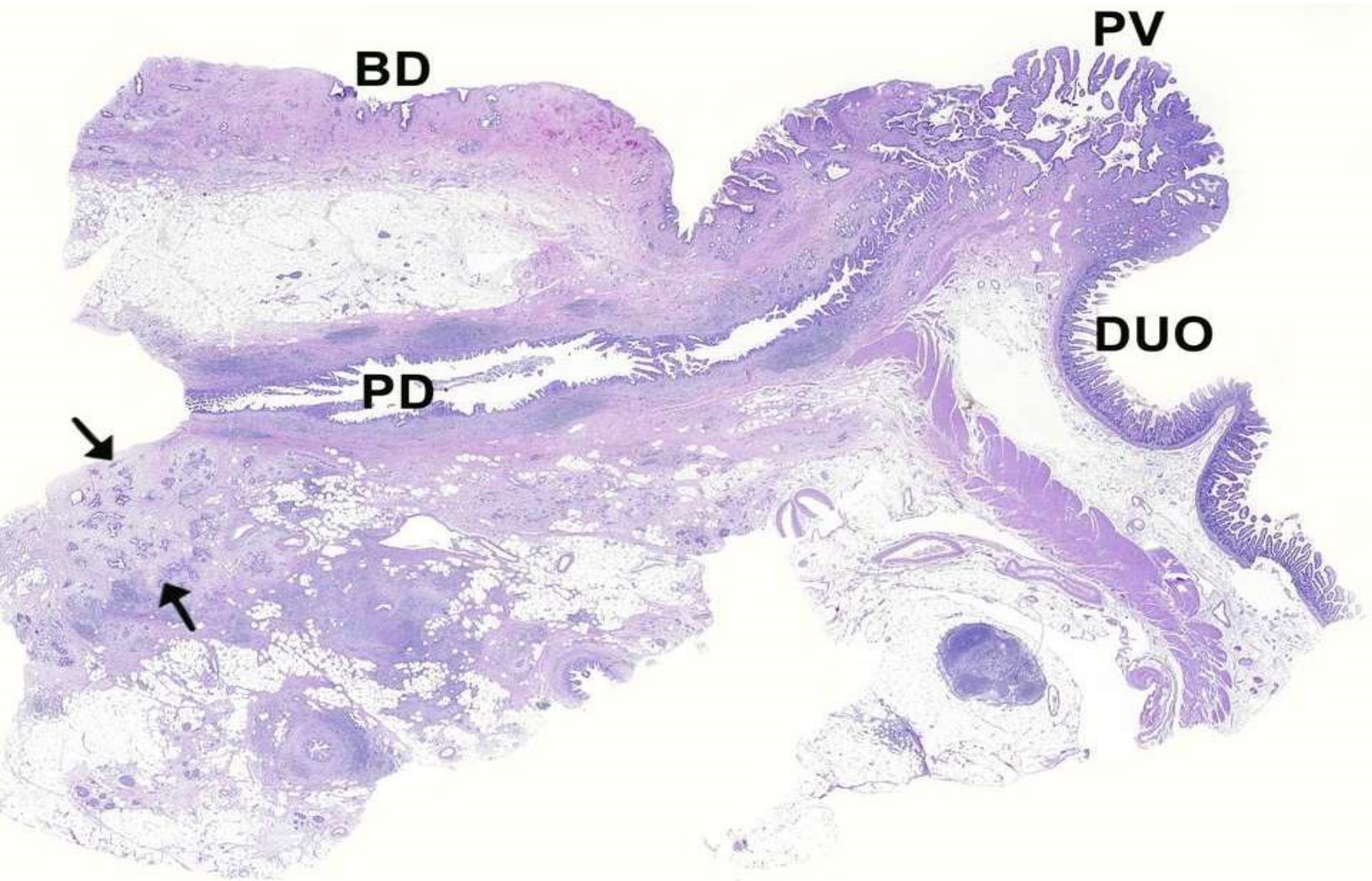
BD

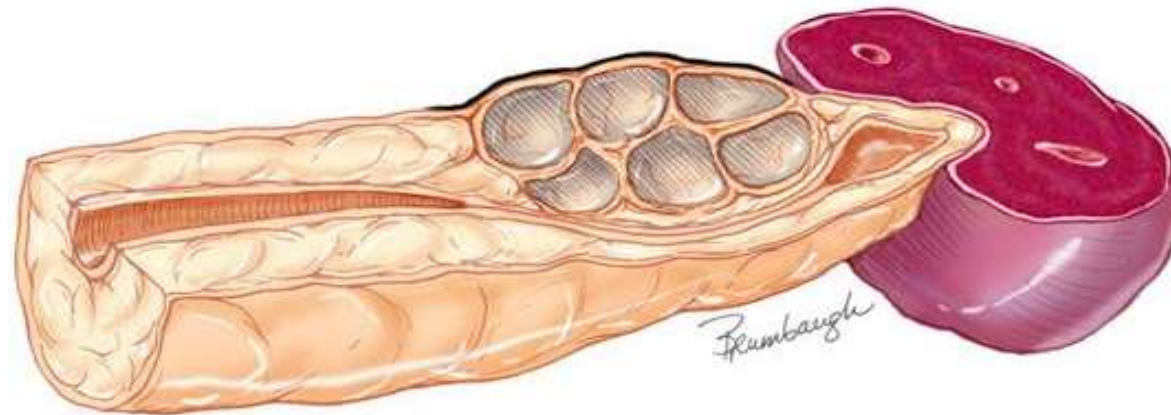
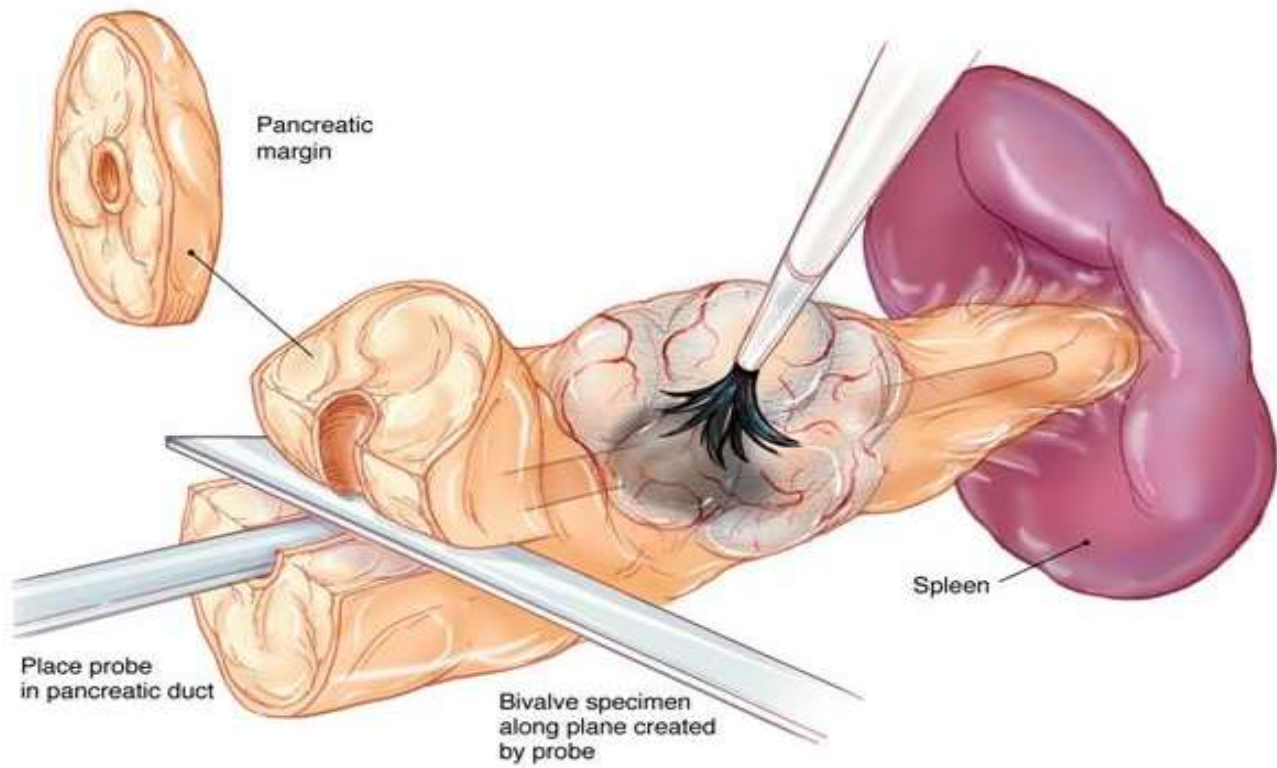
PV

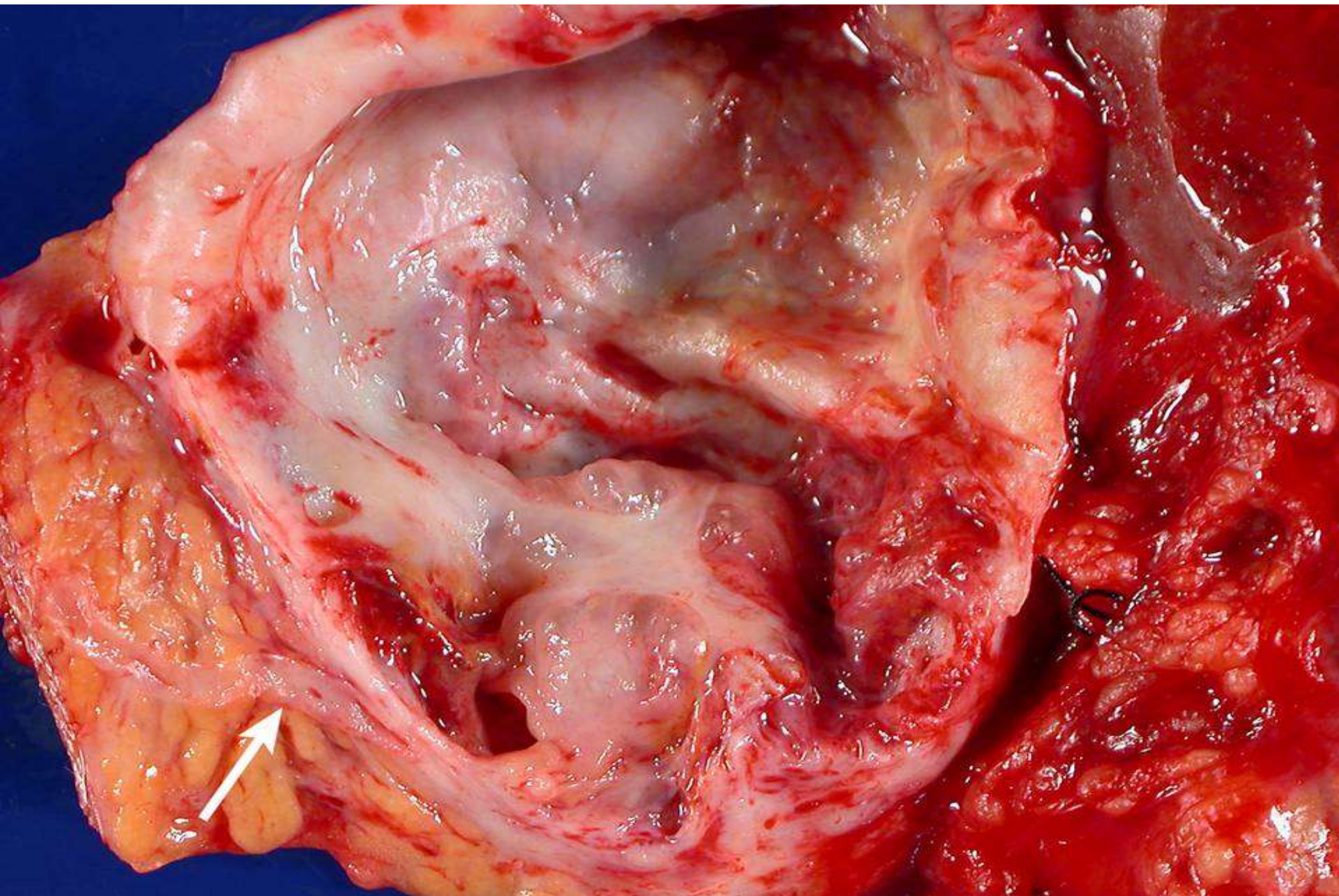
PD

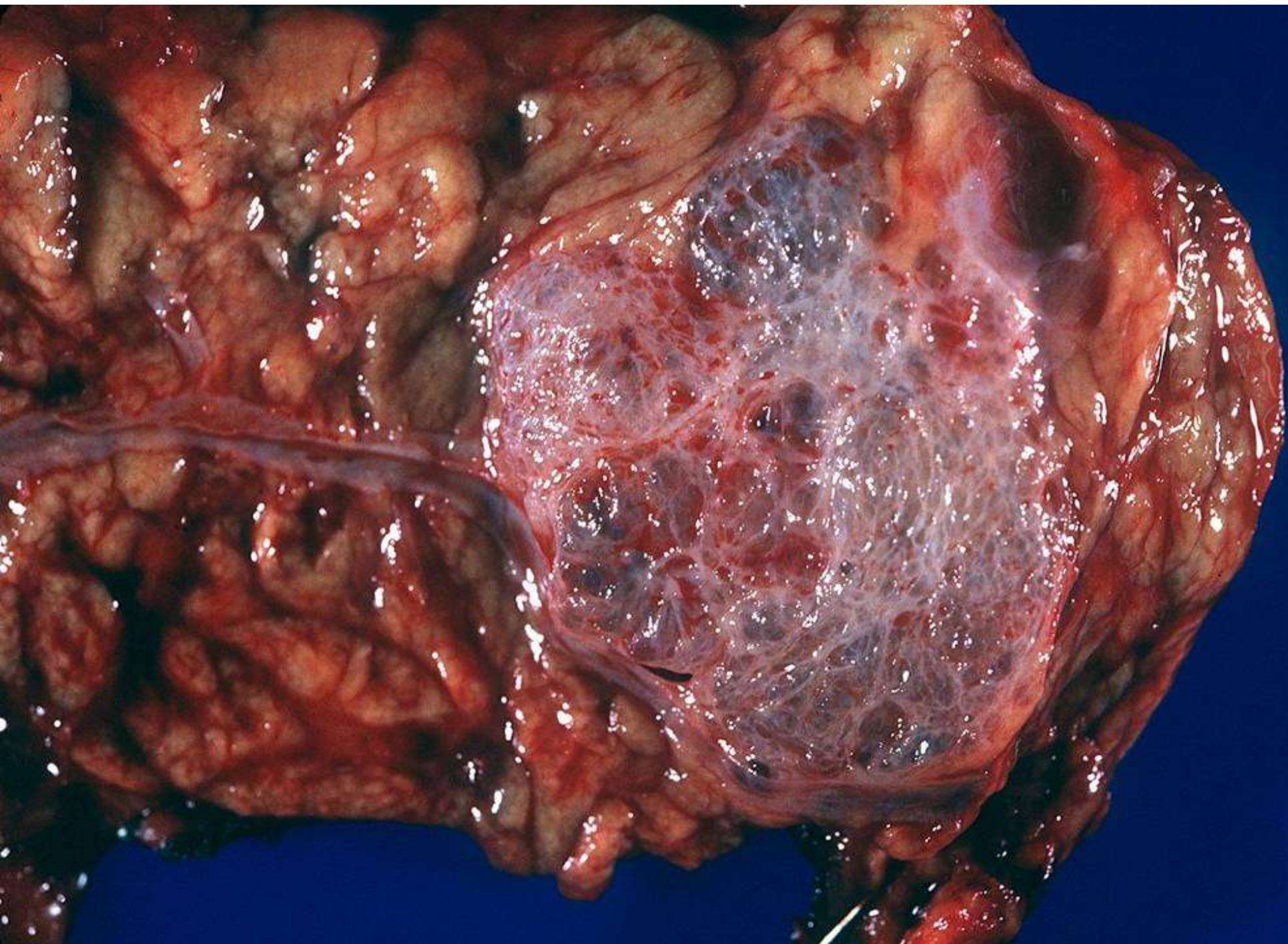
DUO

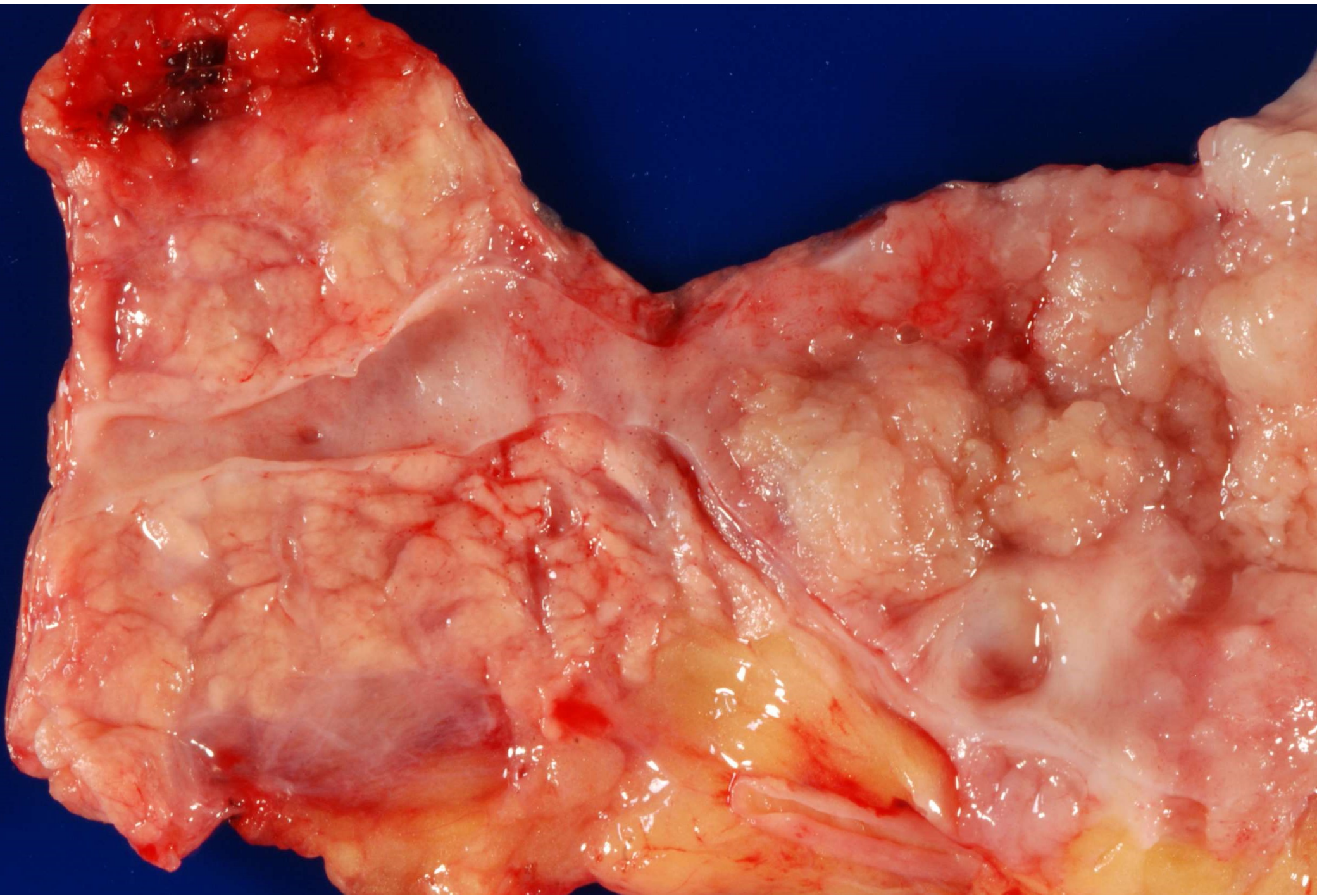








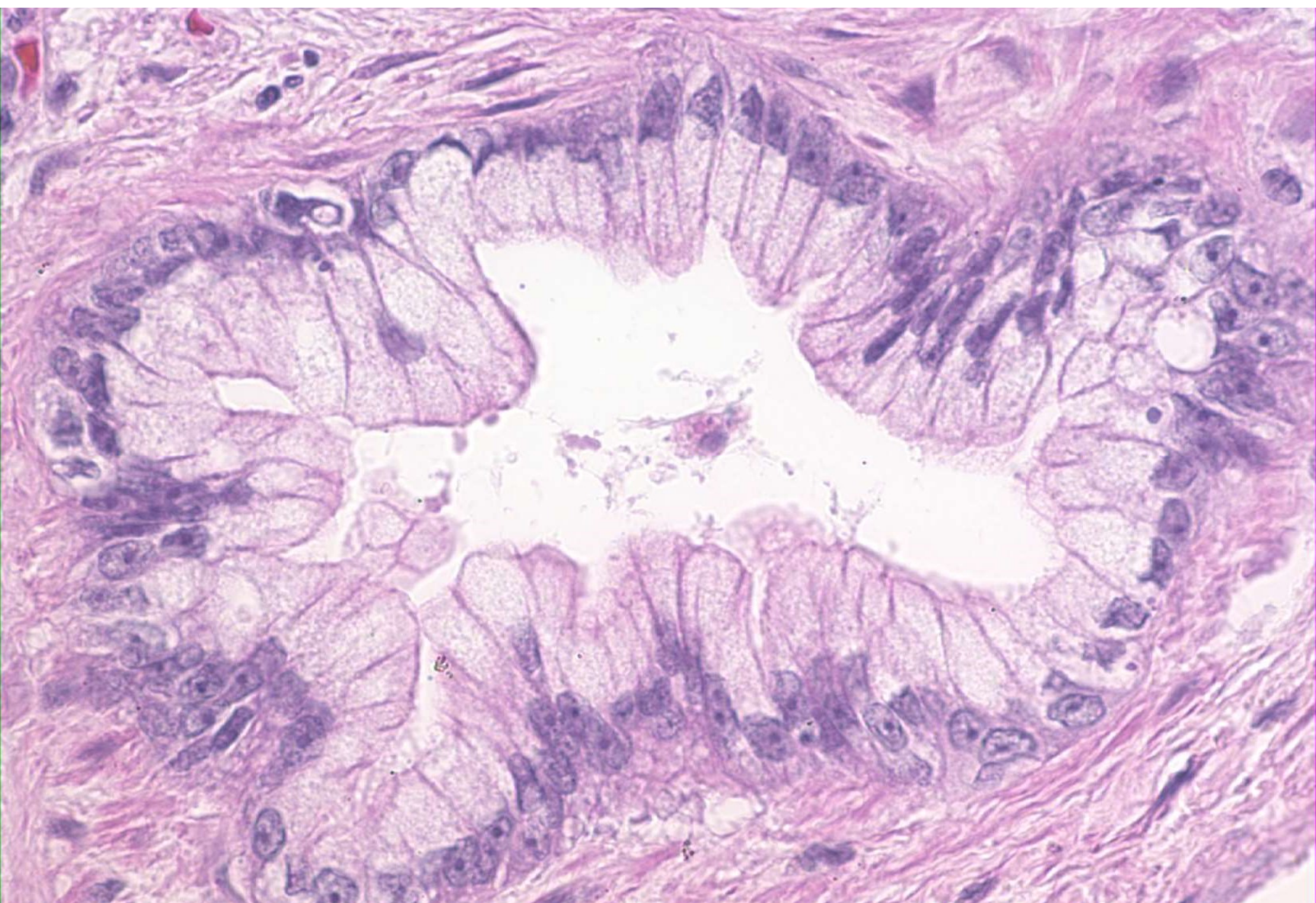


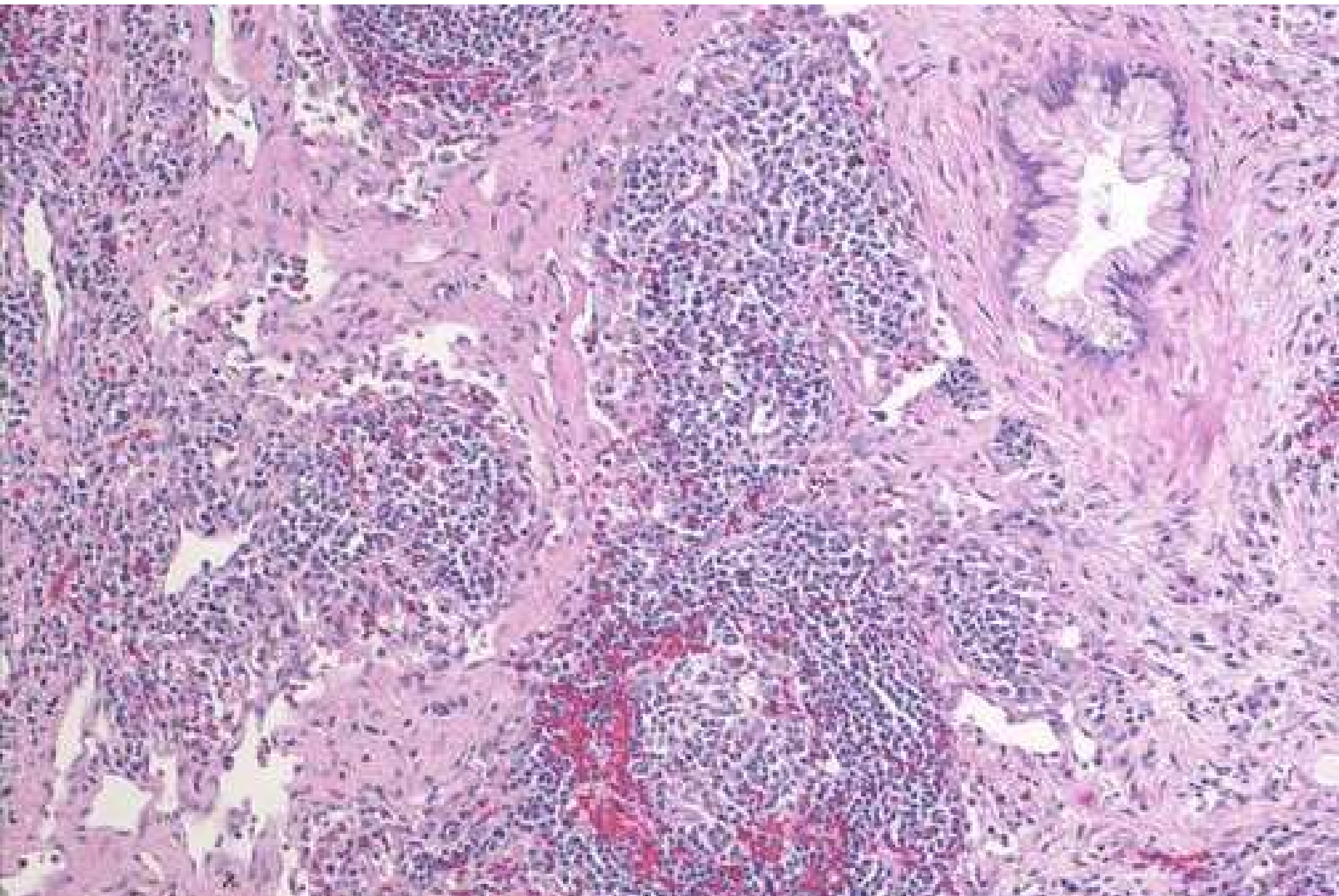


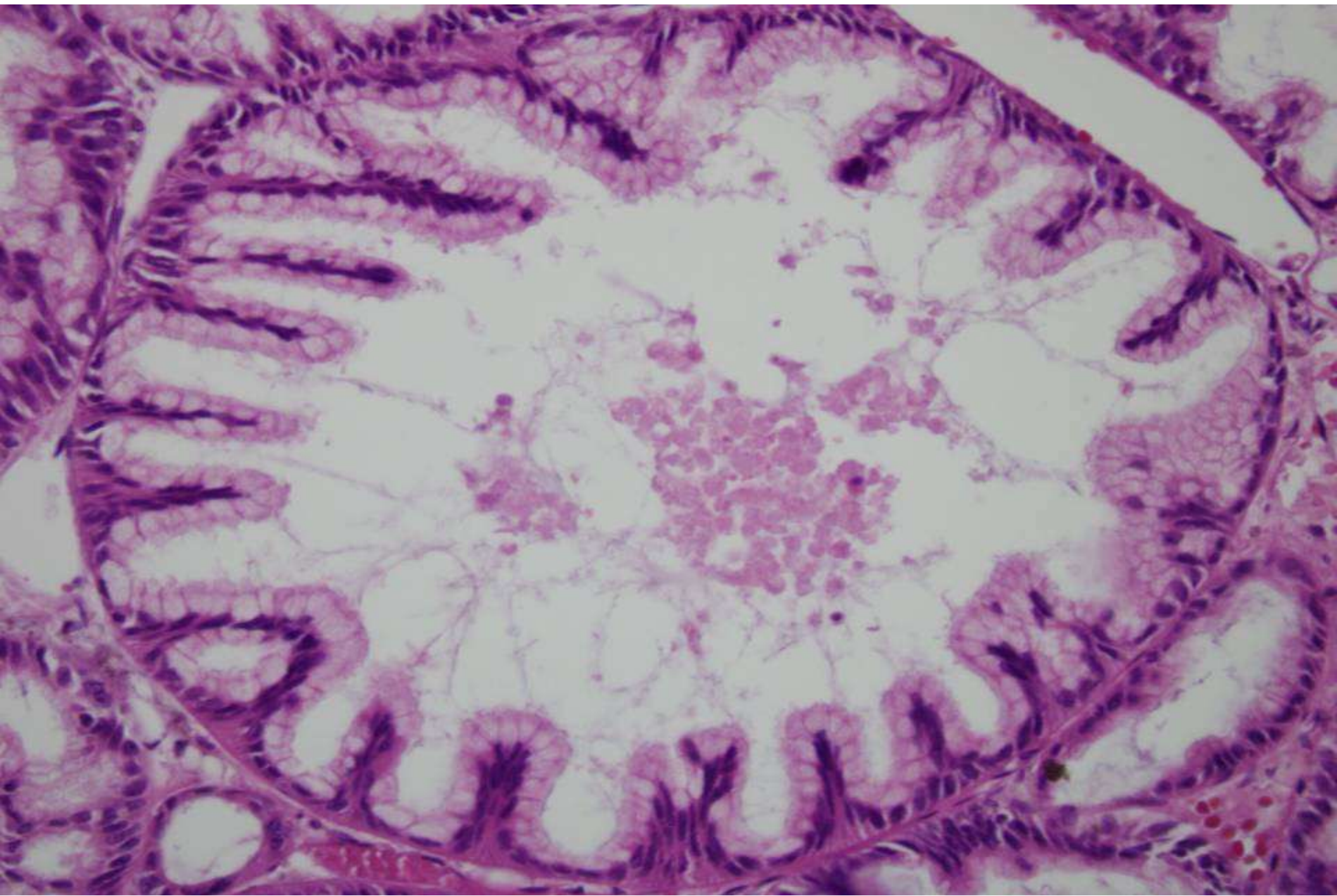
Grossing

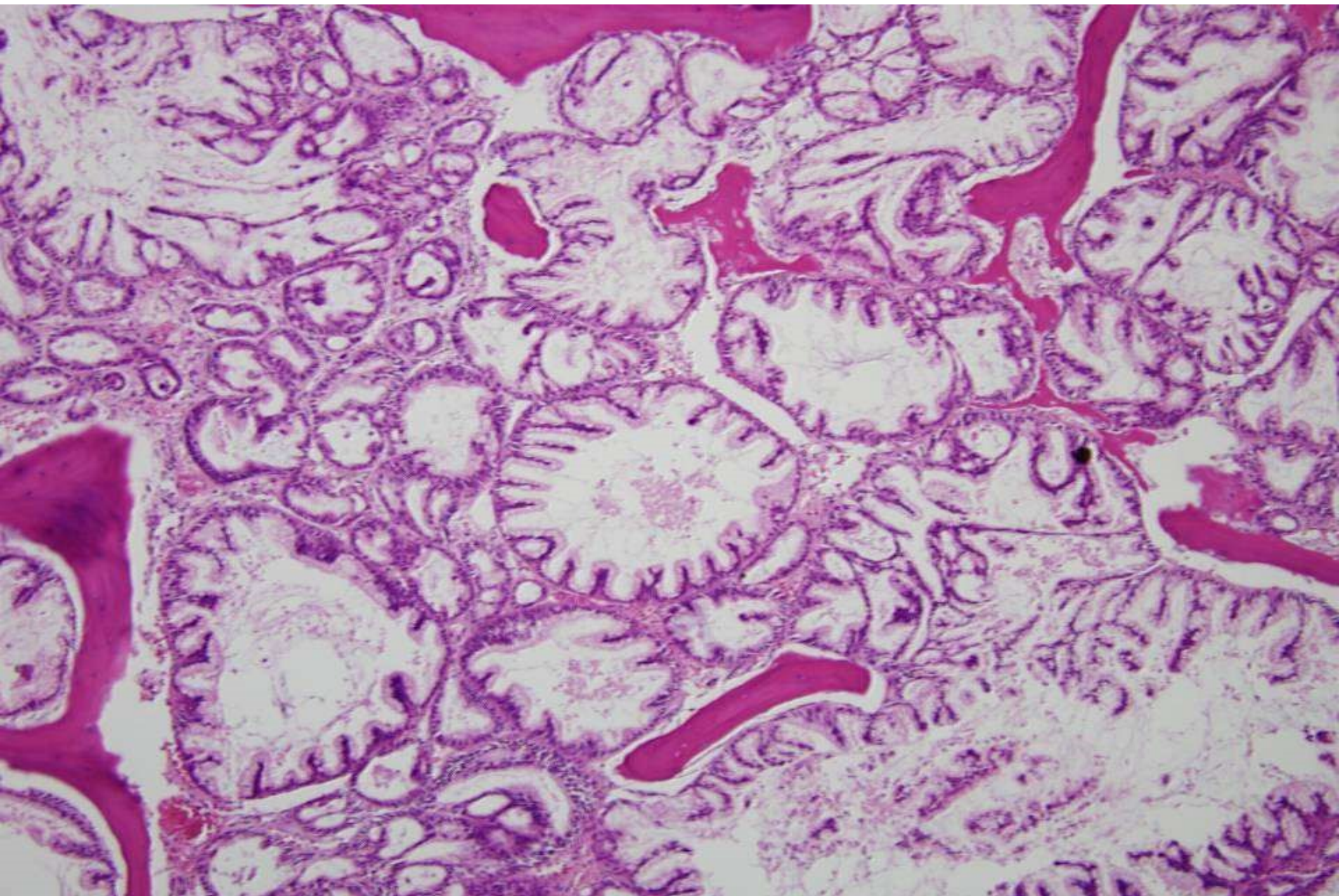
- Head vs. Tail.
- Use your left hand to simulate the anatomy.
- Section through the ampulla to include the ampulla, distal common bile duct, duodenum and the pancreas.
- Cyst contents.
- Do the cysts connect to the duct system.

Adenocarcinoma vs. Reactive Glands



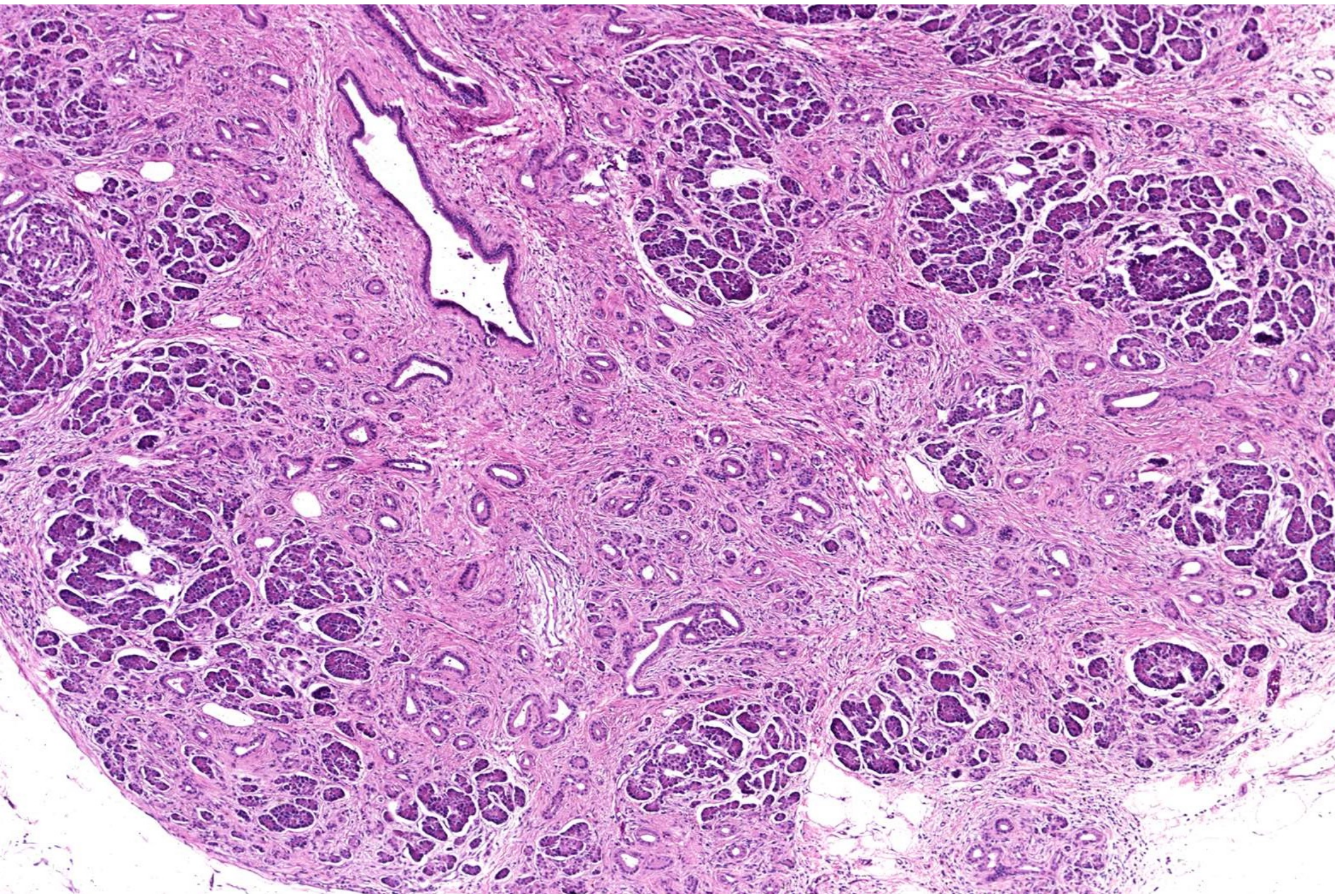


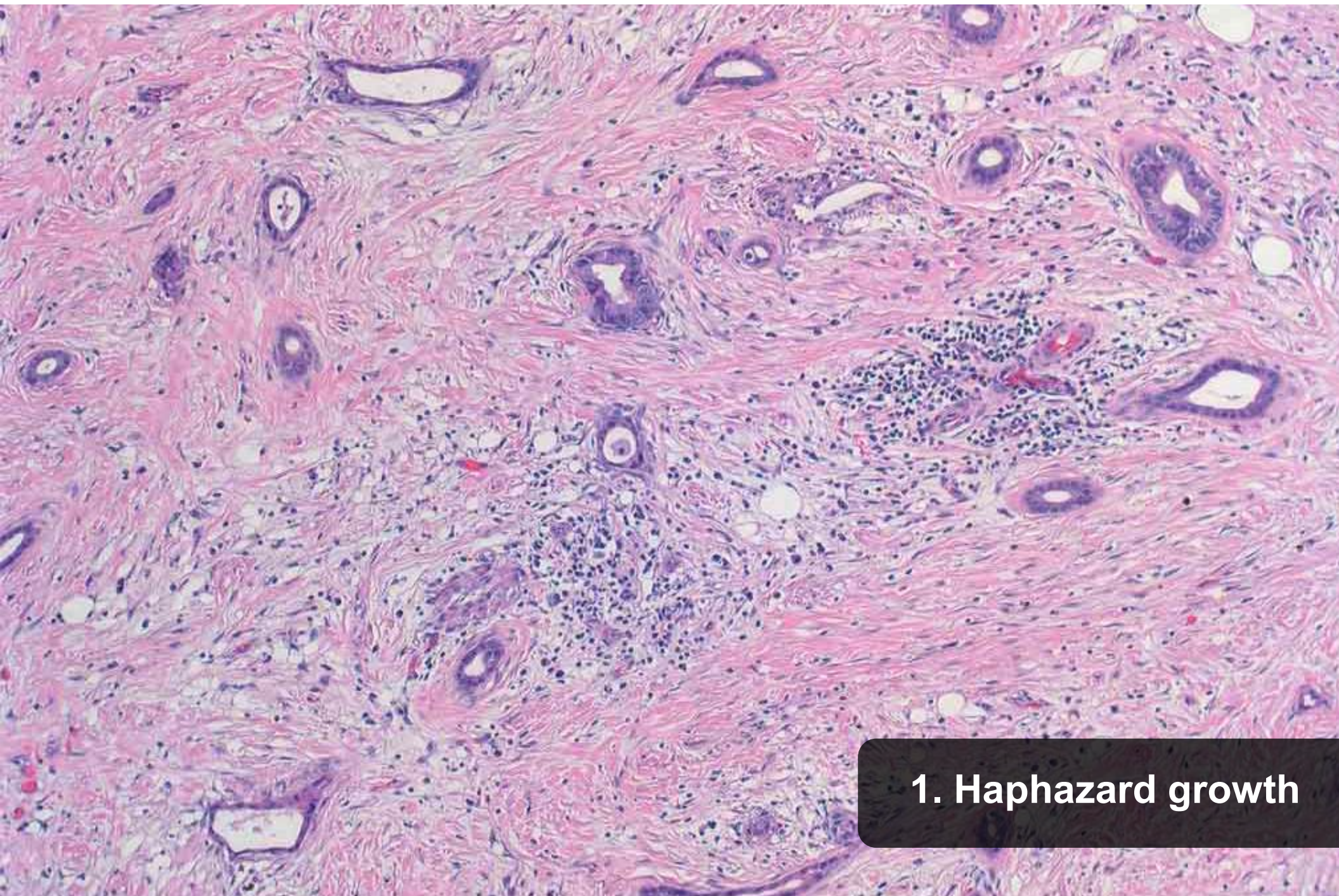




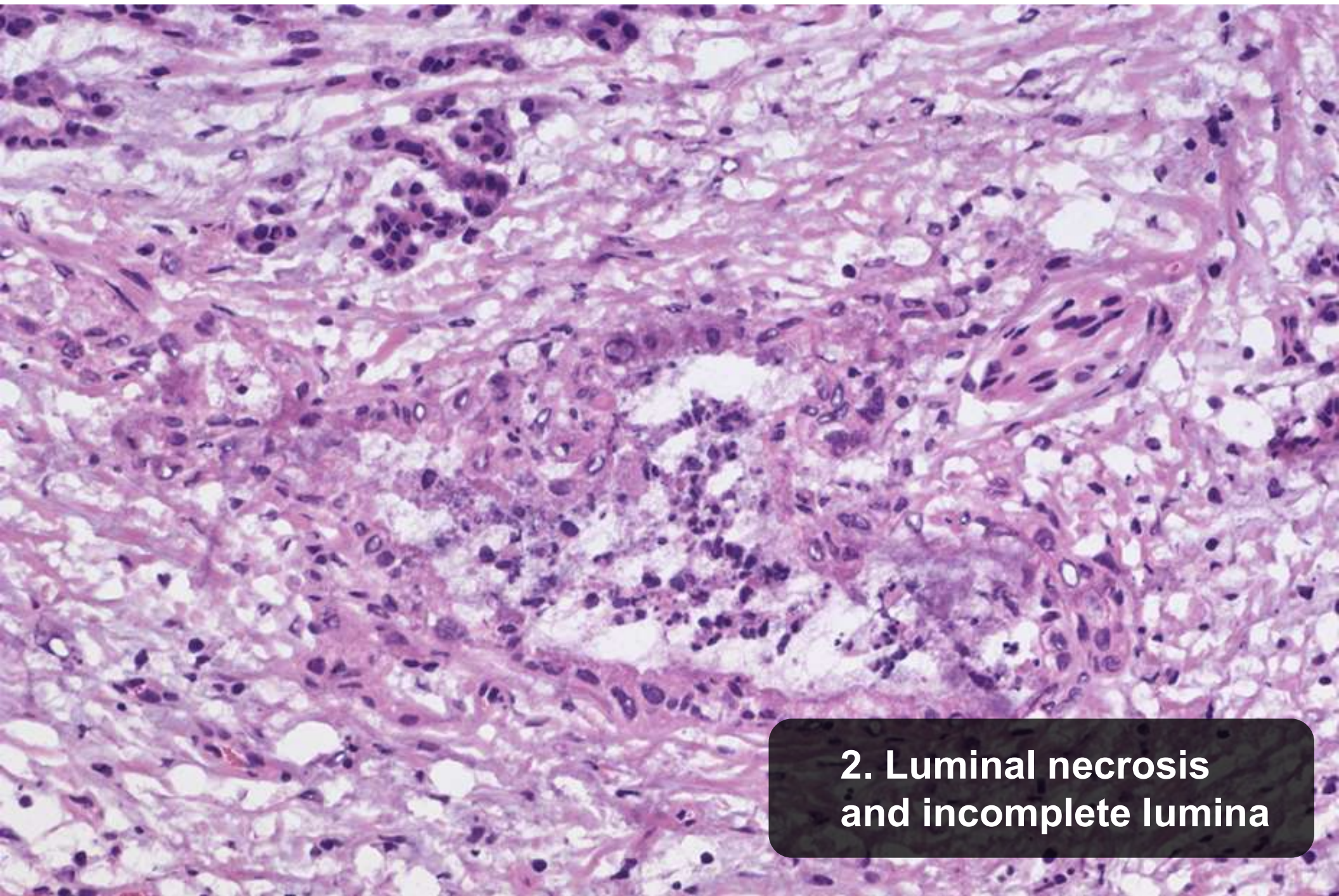
Features Supporting Adenocarcinoma

1. Haphazard growth pattern*
2. Glands next to muscular vessels*
3. Perineural or vascular invasion*
4. Nuclear variation > 4:1*
5. Necrotic glandular debris
6. Incomplete lumina
7. Gland touching fat
8. Loss of dpc4 expression, expression of CEA, mesothelin



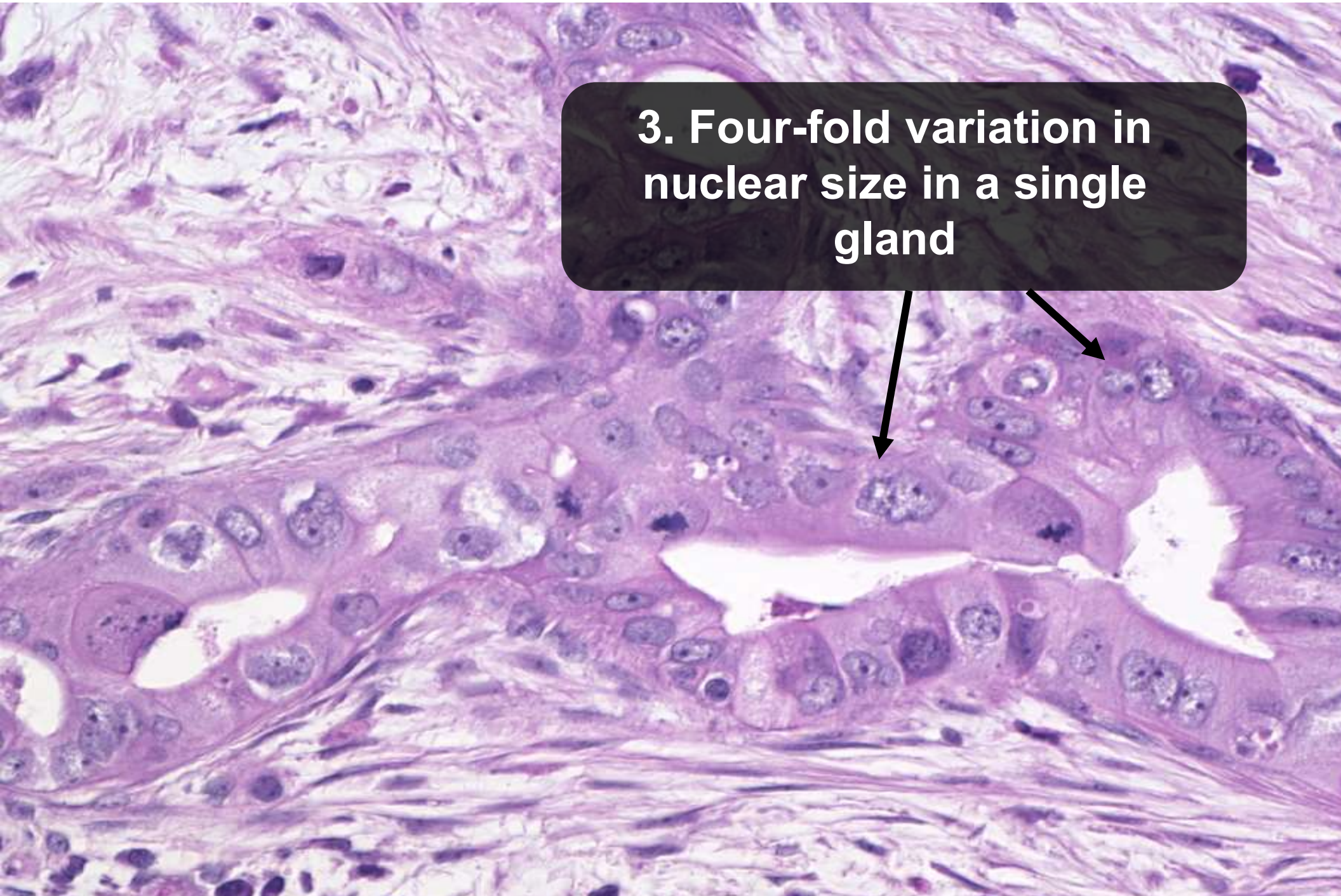


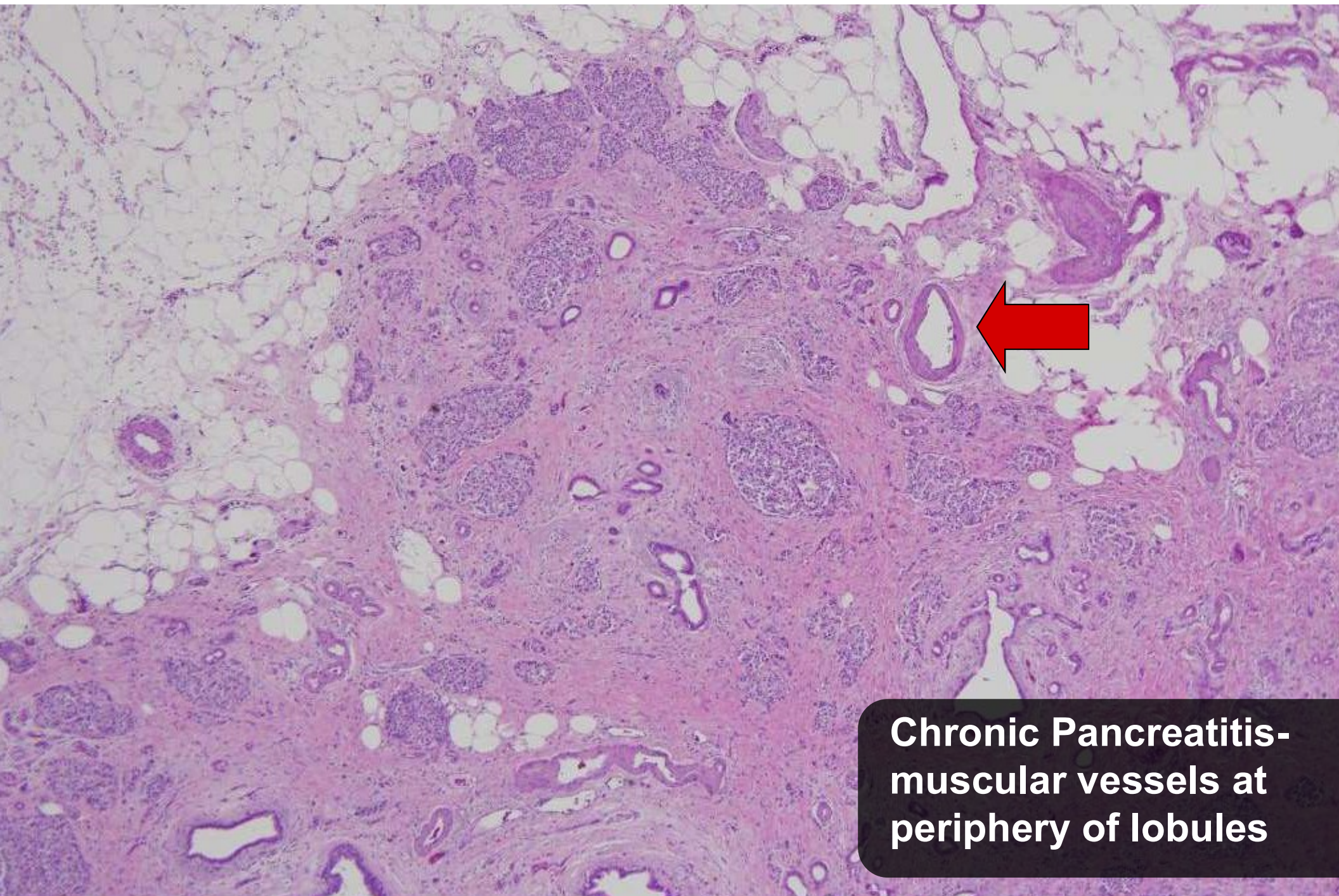
1. Haphazard growth



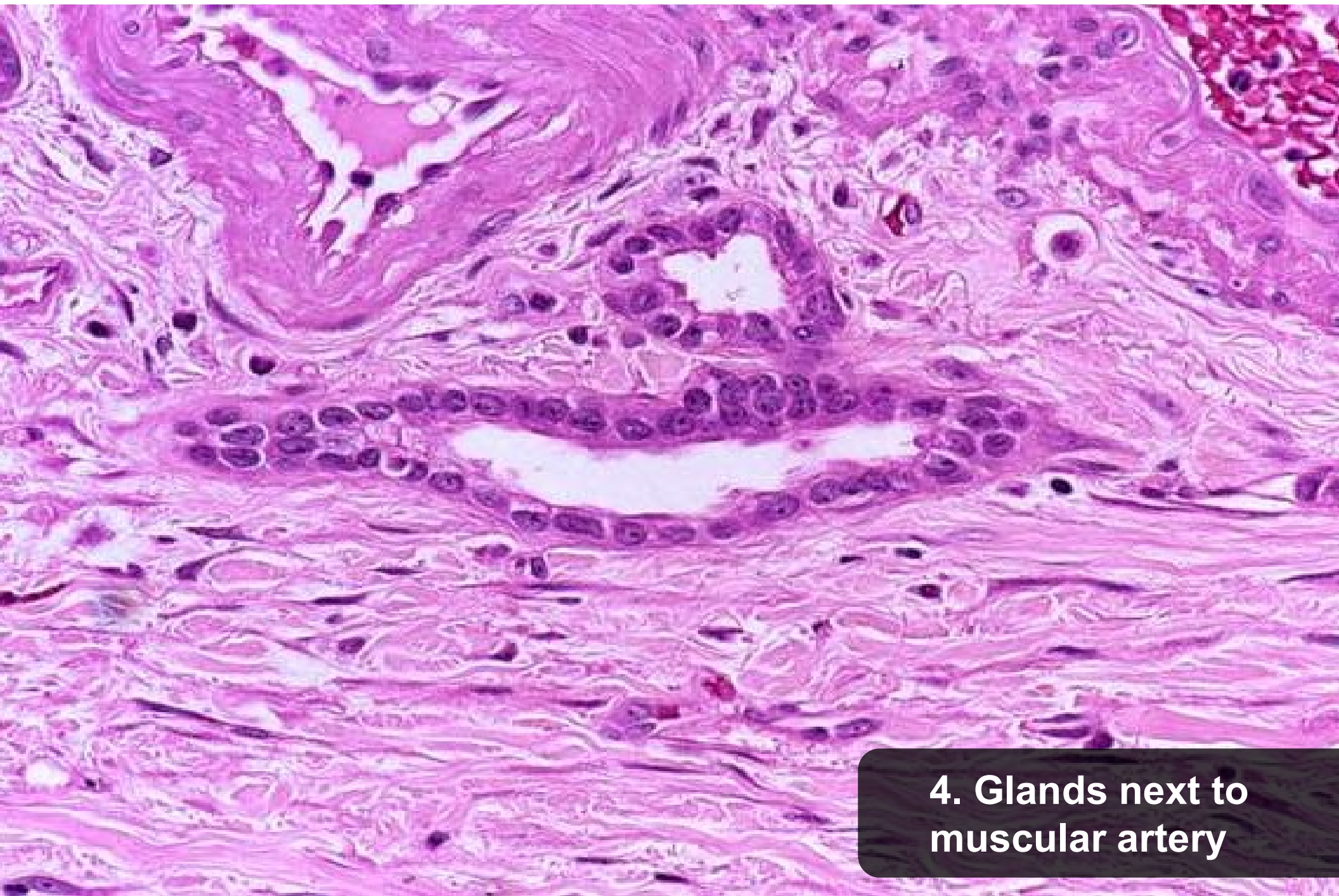
2. Luminal necrosis and incomplete lumina

**3. Four-fold variation in
nuclear size in a single
gland**

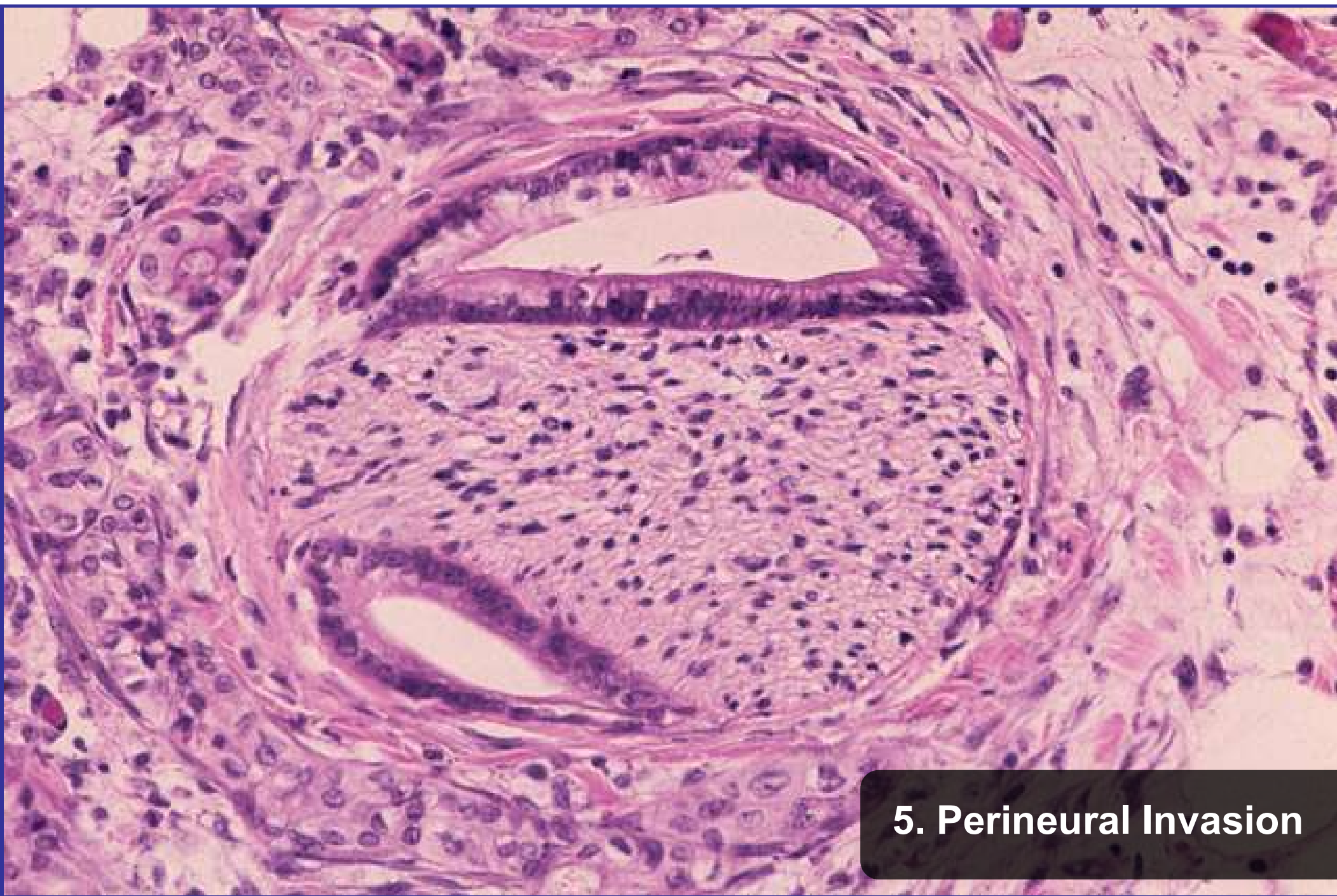




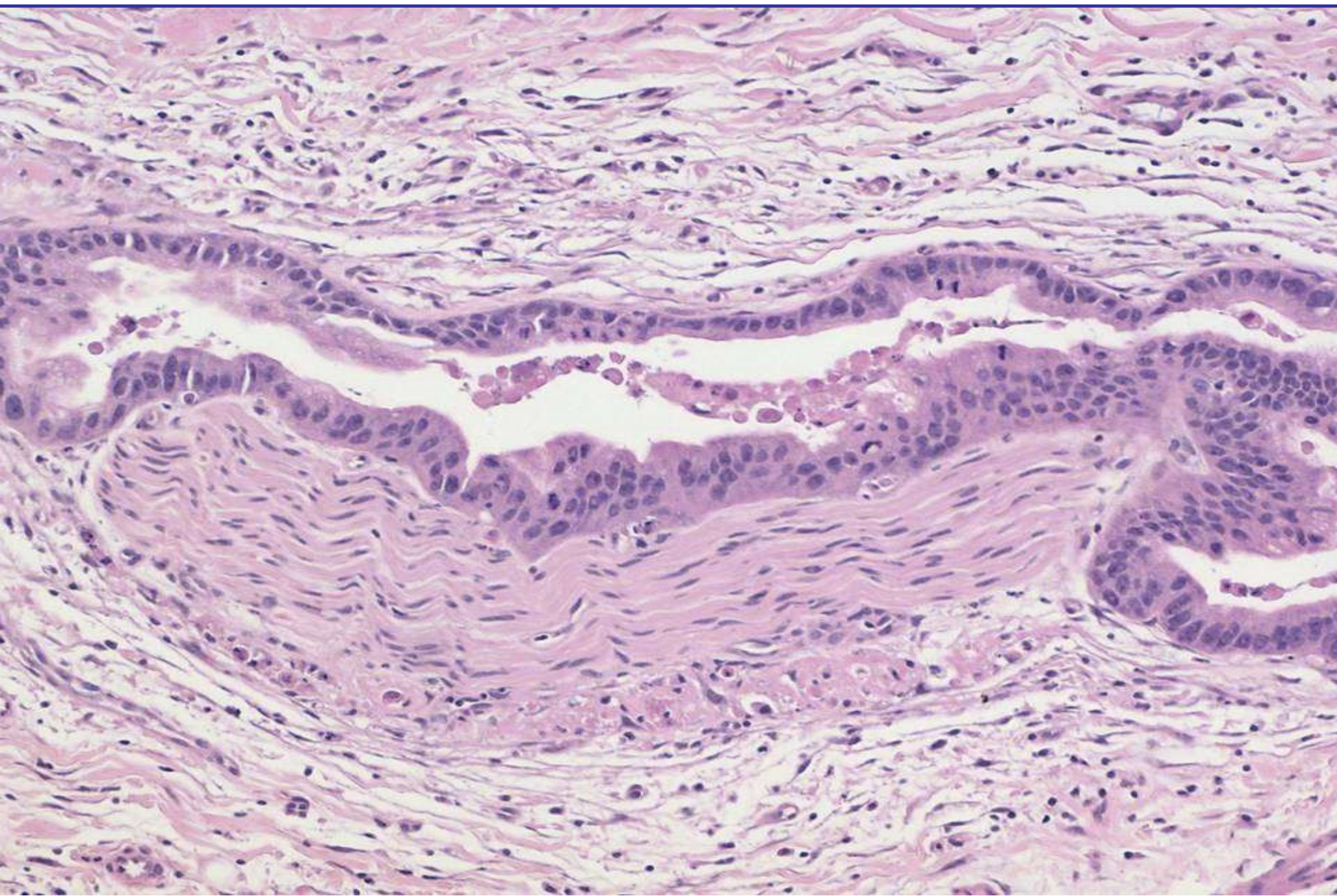
**Chronic Pancreatitis-
muscular vessels at
periphery of lobules**

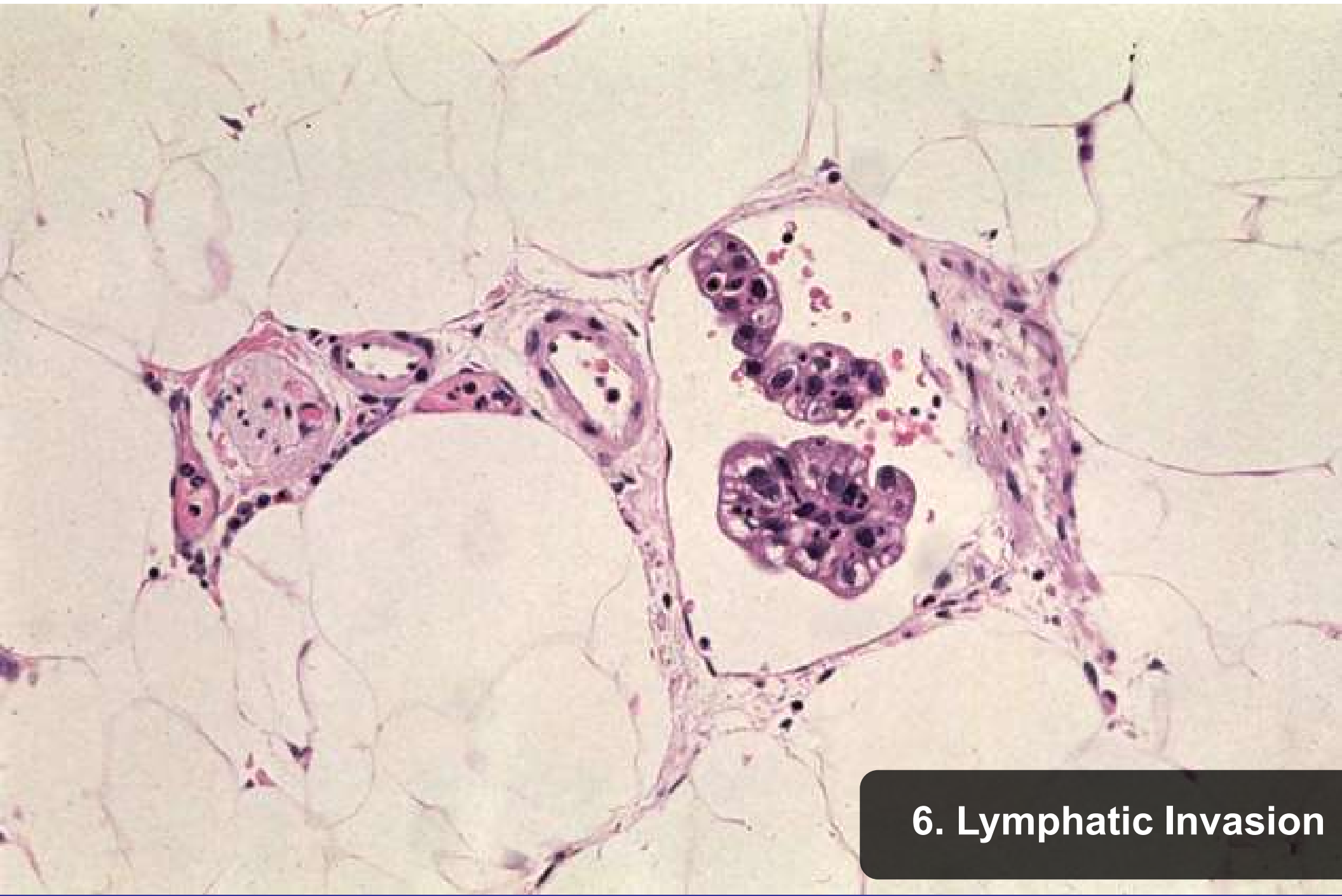

4. Glands next to muscular artery

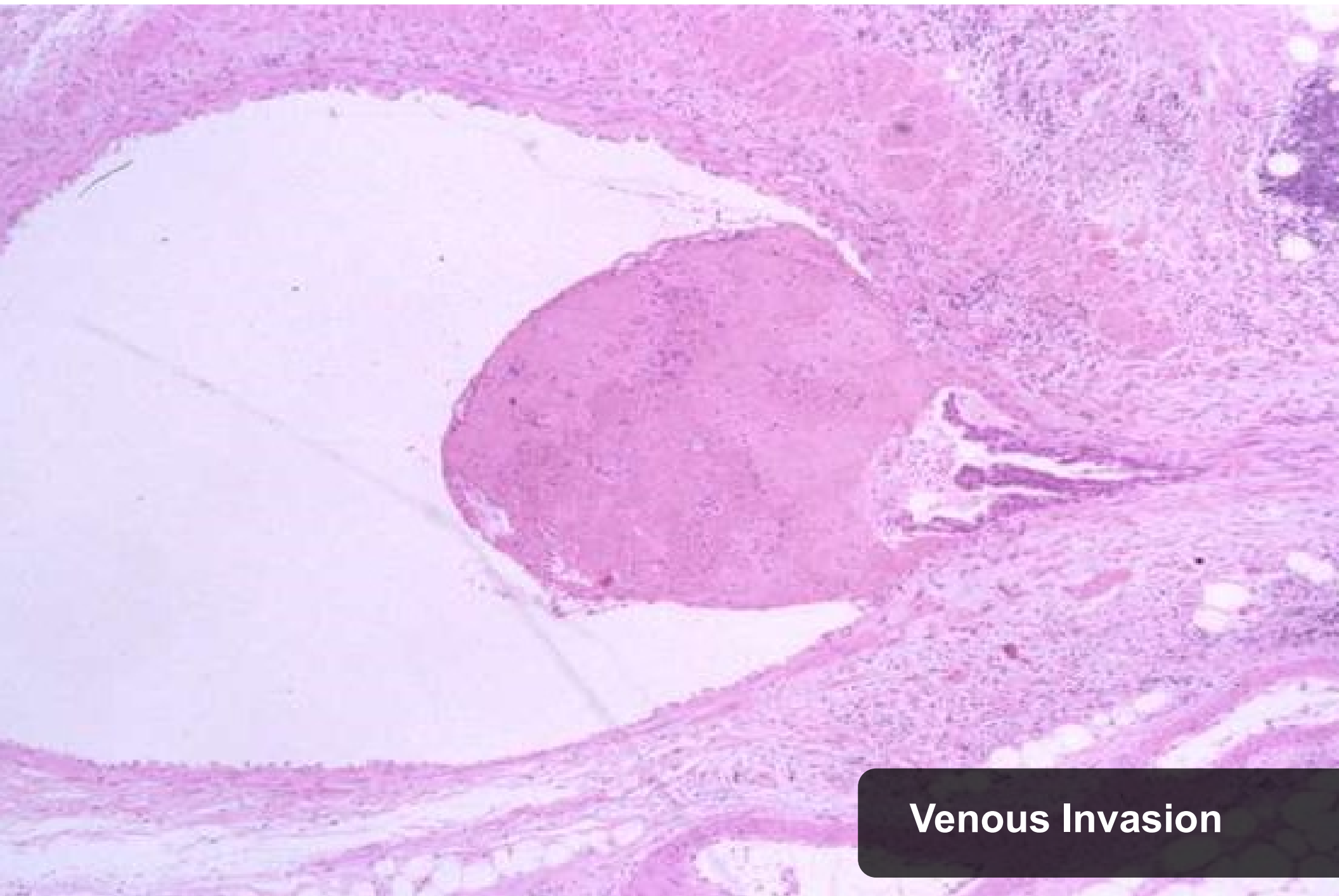


5. Perineural Invasion



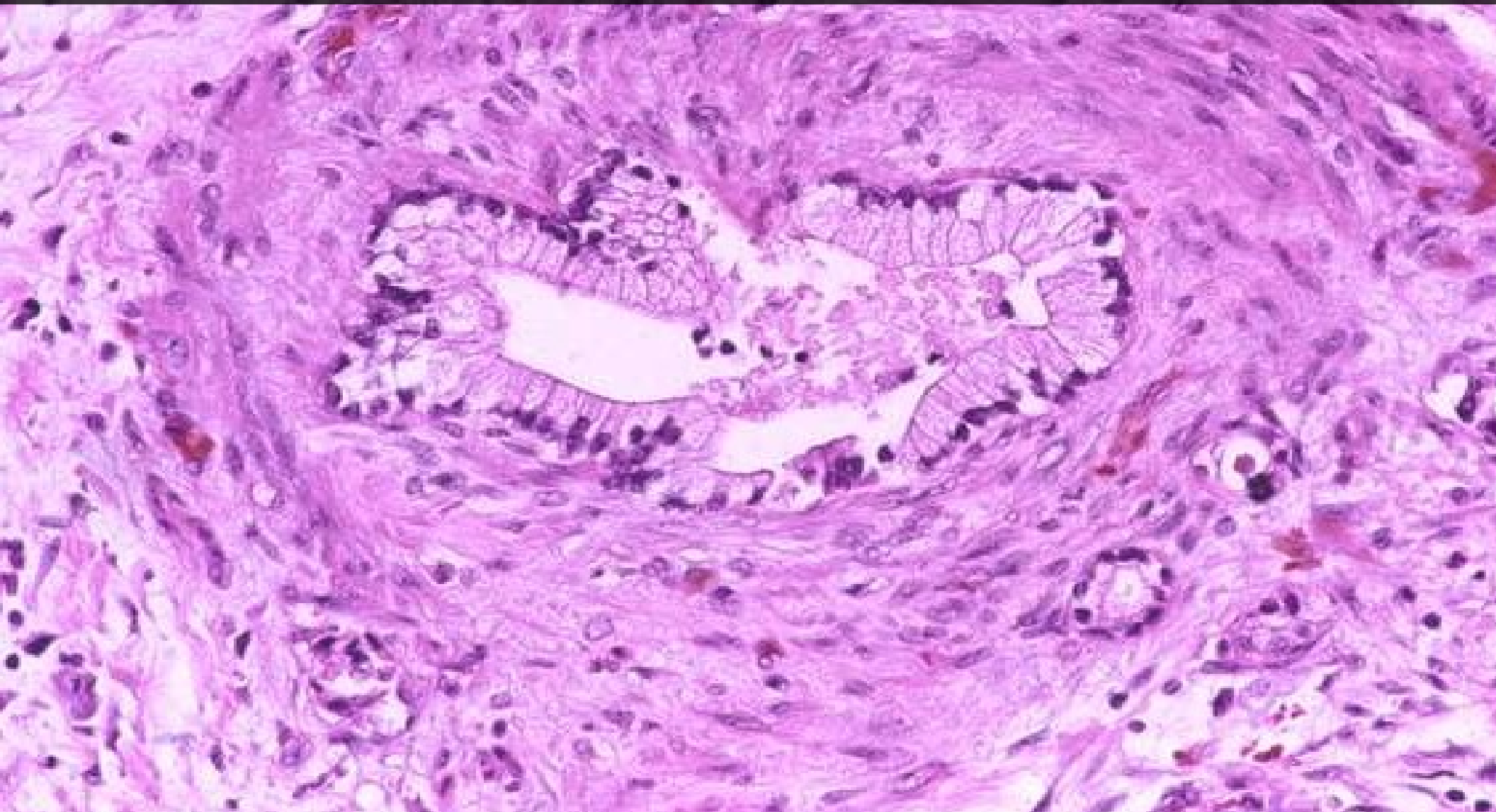


6. Lymphatic Invasion

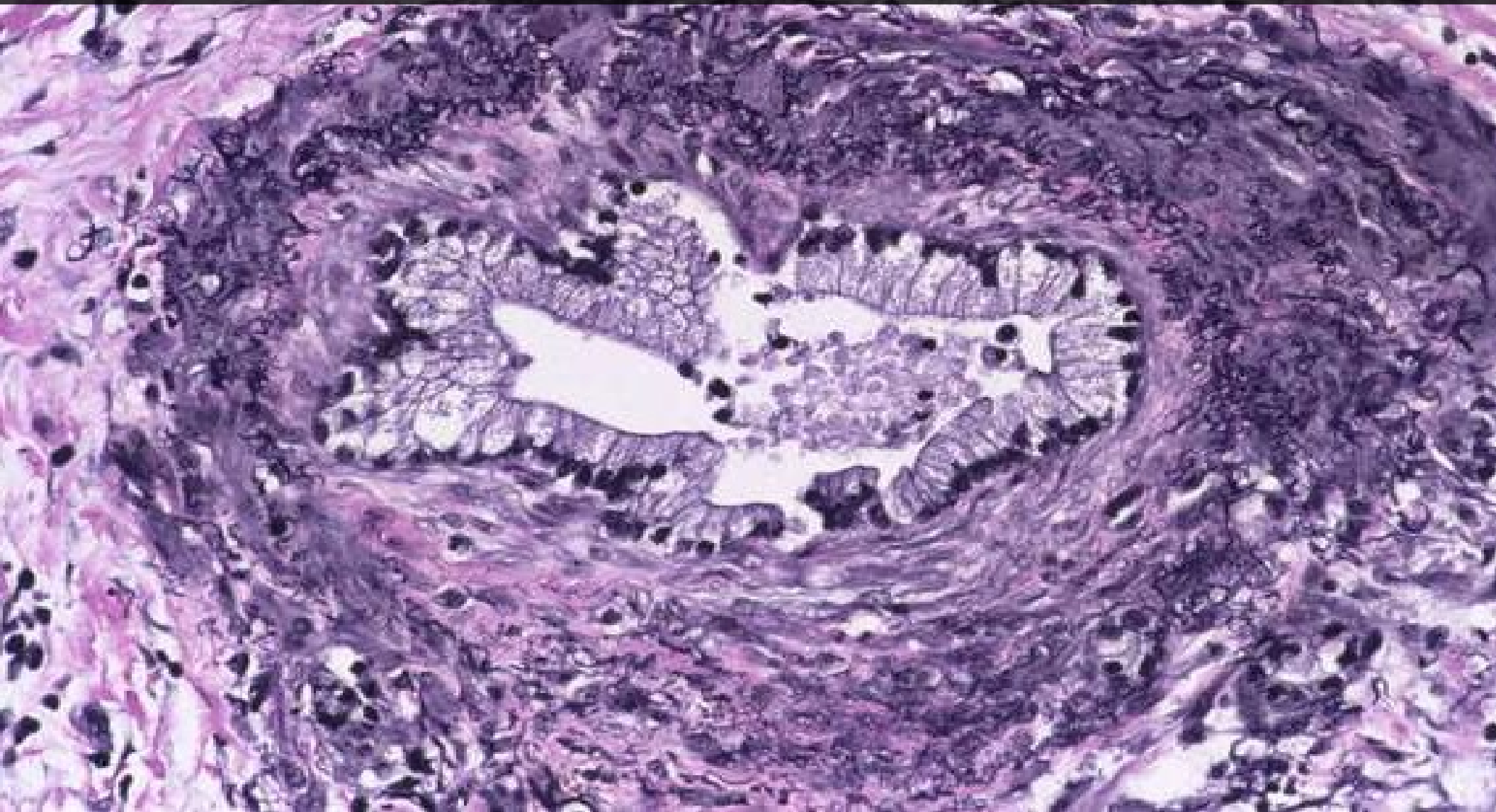


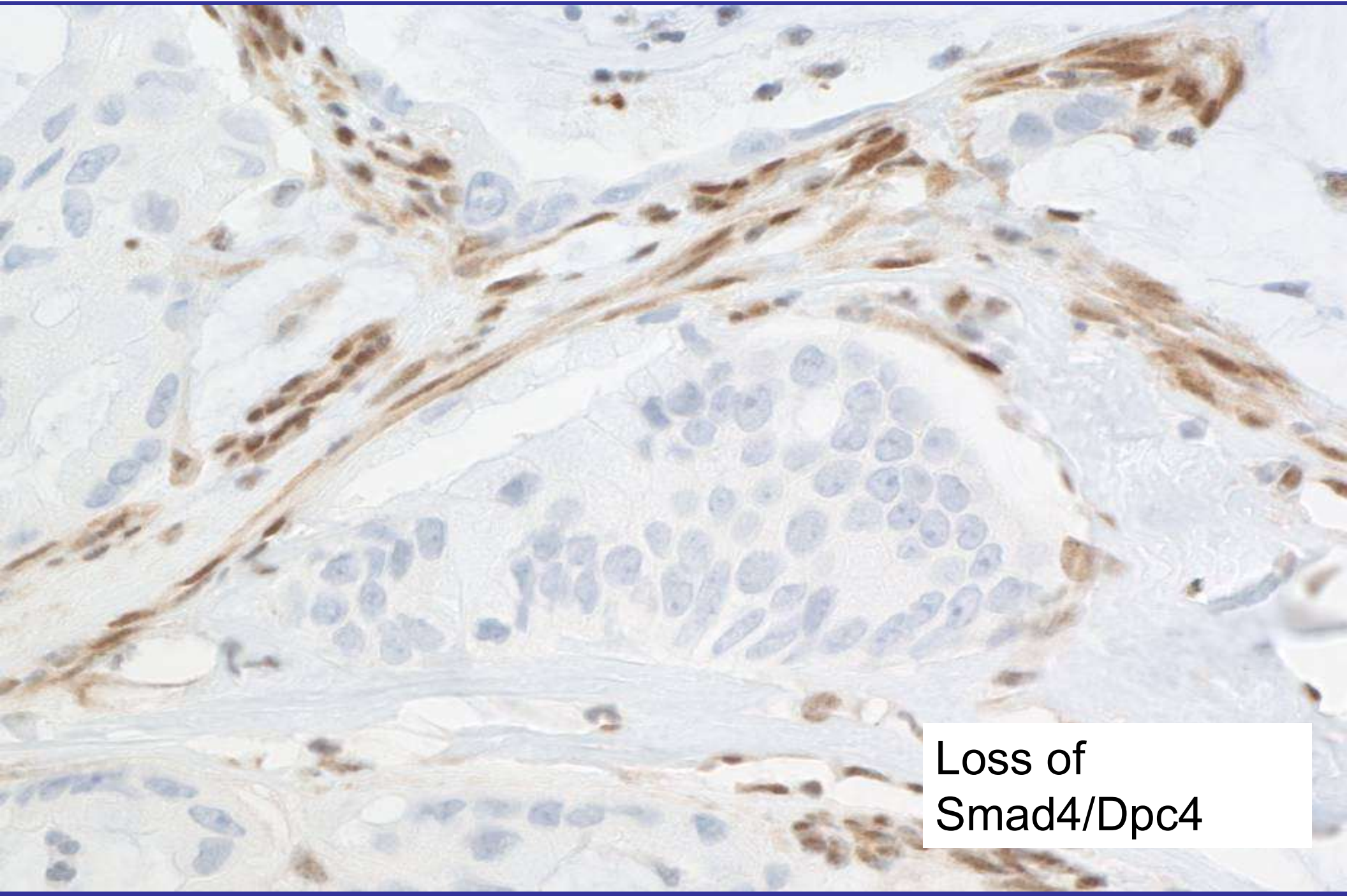
Venous Invasion

Venous Invasion Mimicking PanIN

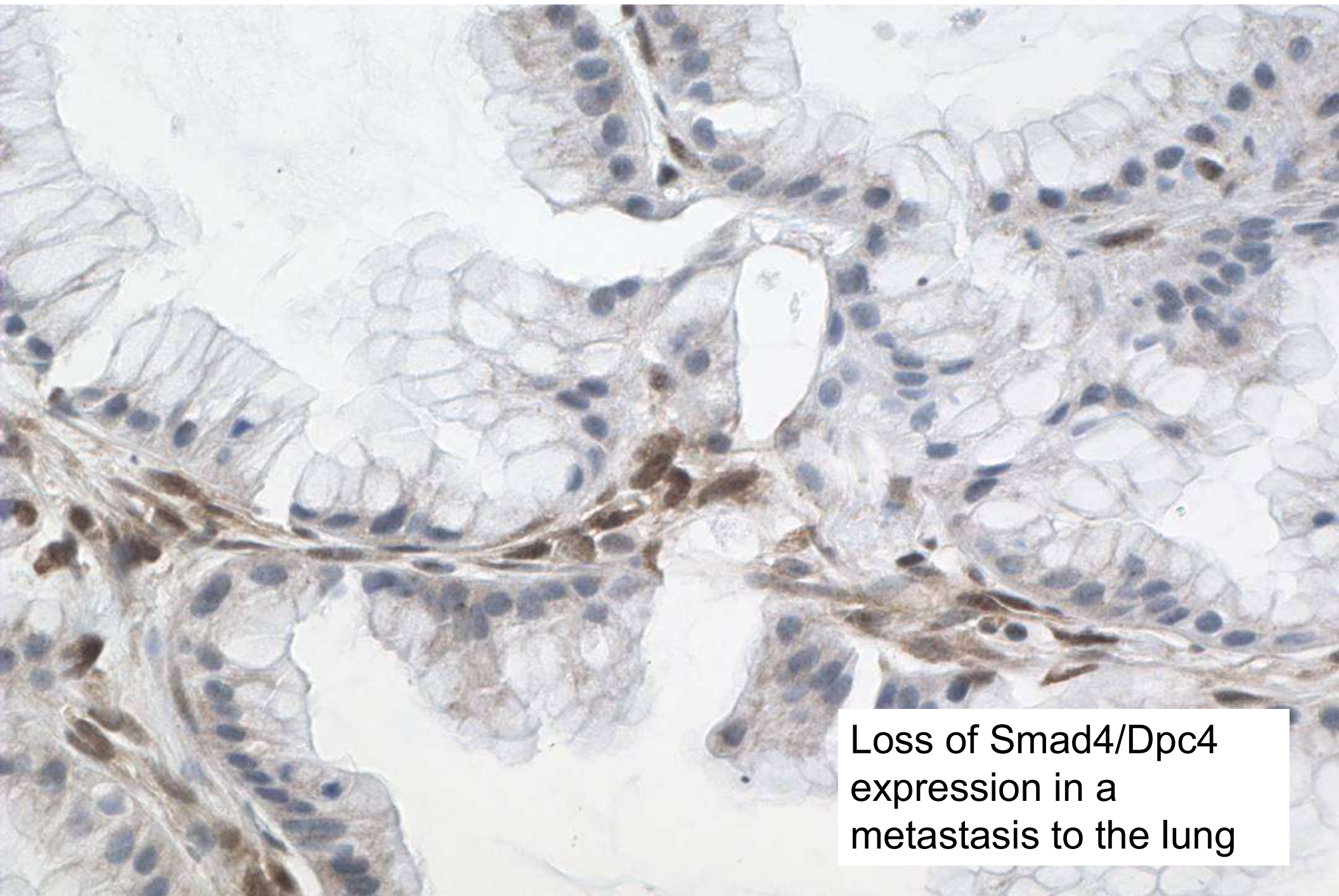


Venous Invasion Mimicking PanIN





Loss of
Smad4/Dpc4



Loss of Smad4/Dpc4 expression in a metastasis to the lung


Features Supporting Adenocarcinoma

1. Haphazard growth pattern*
2. Glands next to muscular vessels*
3. Perineural or vascular invasion*
4. Nuclear variation > 4:1*
5. Necrotic glandular debris
6. Incomplete lumina
7. Gland touching fat
8. Loss of dpc4 expression, expression of CEA, mesothelin

Variants of Infiltrating Ductal Adenocarcinoma

“Pancreatic cancer is actually 4 separate diseases, 'breakthrough' research finds”

- “Pancreatic cancer is at least four separate diseases each with a different cause and needing a different treatment, scientists have discovered.”
- “The findings of this research are incredibly exciting for anyone affected by pancreatic cancer...”



BBC News
Sydney Morning Herald
Syracuse.com

Pathologists Recognize Eight Variants of Ductal Adenocarcinoma

- **Adenocarcinoma**

1. Adenosquamous
2. Colloid
3. Hepatoid
4. Medullary
5. Signet ring
6. Tubular (ductal)
7. Undifferentiated
8. Undifferentiated carcinoma with osteoclast-like giant cells

**Millions of Dollars worth
of whole genome
sequencing misses 4 of
the 8 types of pancreatic
cancer**

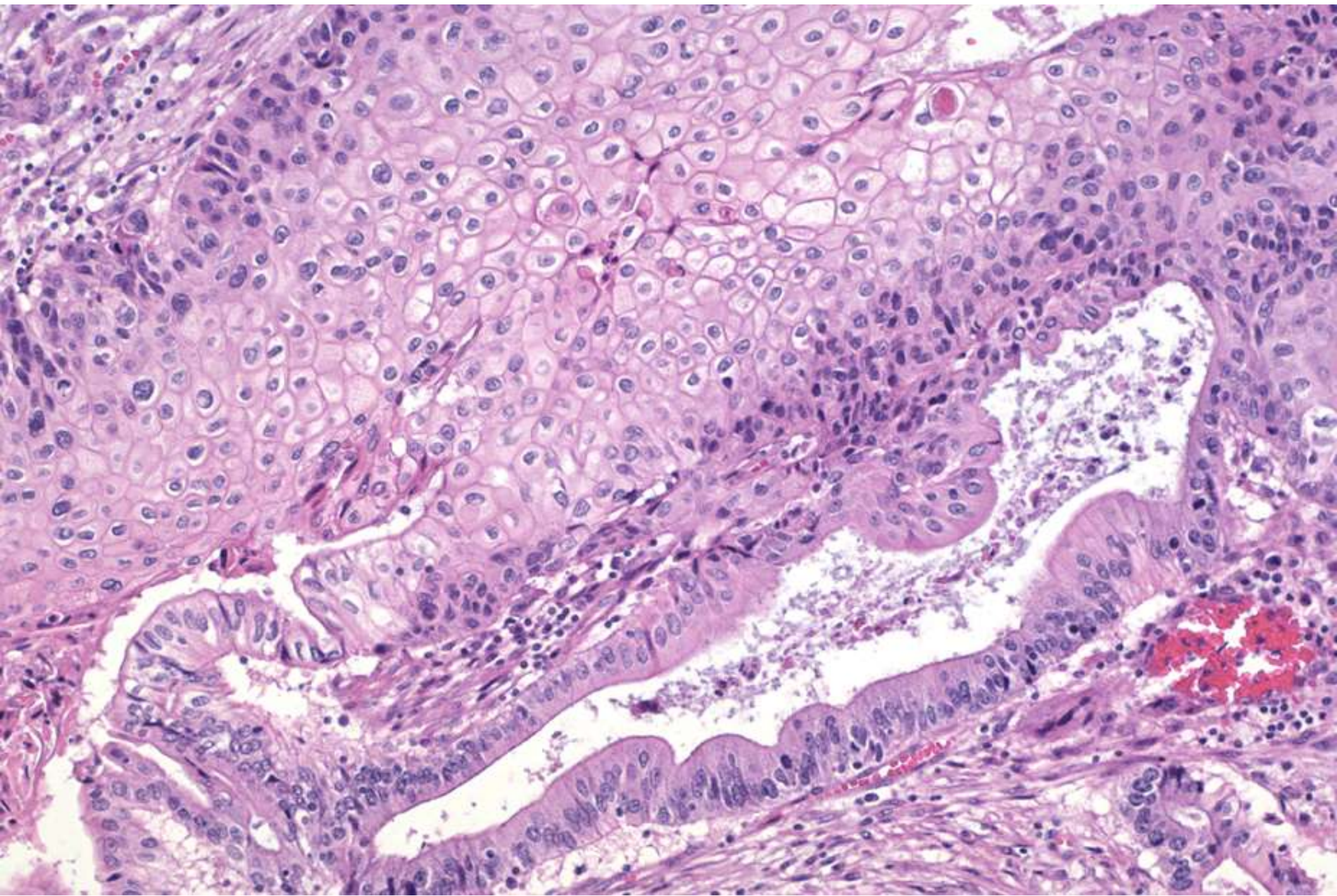
**An Understanding of
Molecular Genetics
has Validated and in
Some Instances
Enhanced the
Classification of
Pancreatic Neoplasms**

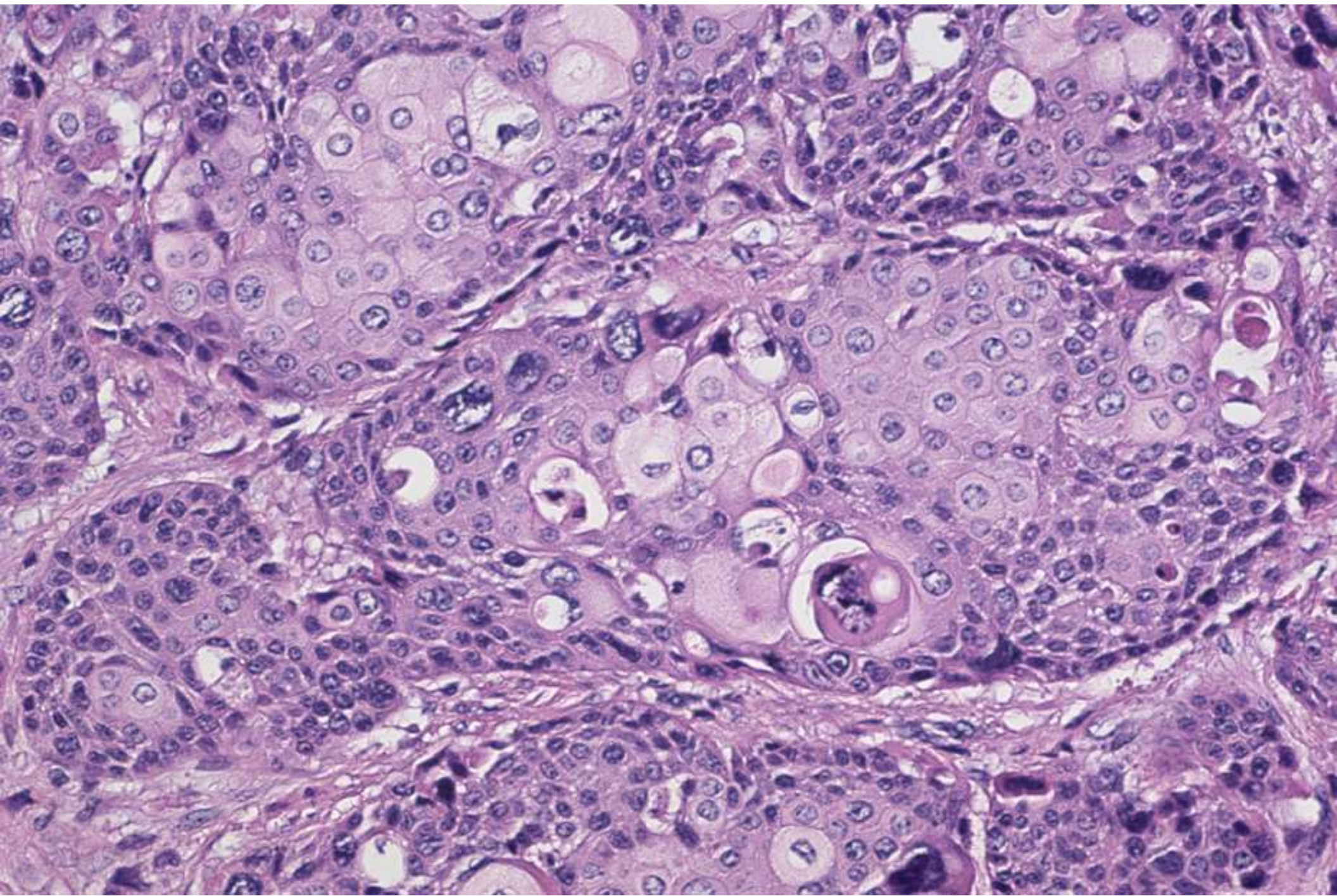
Ductal Adenocarcinoma and Related Neoplasms

- **Adenocarcinoma**
 1. Adenosquamous
 2. Colloid
 3. Hepatoid
 4. Medullary
 5. Signet ring
 6. Tubular (ductal)
 7. Undifferentiated
 8. Undifferentiated carcinoma with osteoclast-like giant cells

Adenosquamous Carcinoma

- A malignant epithelial neoplasm of the pancreas with significant components of both glandular and squamous differentiation
- The squamous component should comprise at least 30% of the neoplasm
- Account for 3-4% of the malignancies of the exocrine pancreas
- The median survival is only six months, and few patients survive beyond a year


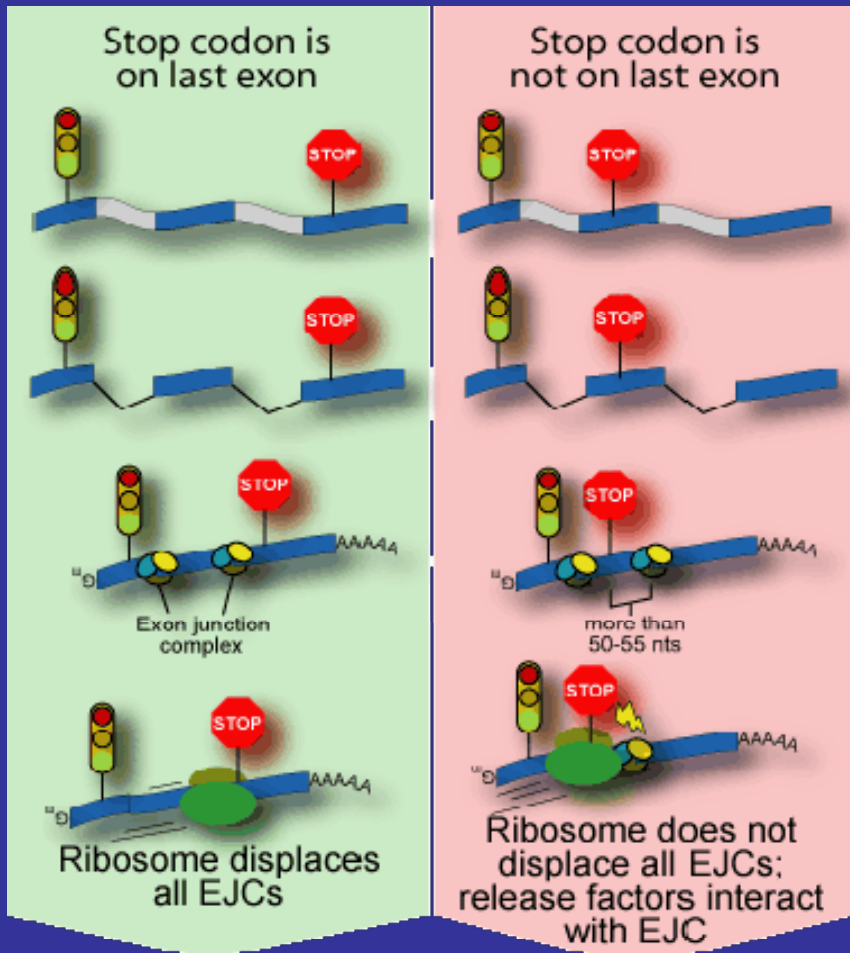




Adenosquamous Carcinoma

- Genetics- *KRAS*, *SMAD4* and *TP53* mutations (same as those in tubular/ductal adenocarcinoma).
- 80% harbor inactivating mutations in the *UPF1* gene (nonsense-mediated RNA decay).
- The squamous component overexpresses markers of squamous differentiation including p63.
- Therapy- inclusion of a platinum agent in the adjuvant regimen improves survival (HR =2.4; 95% CI, 1.0-5.8; P=0.04)

Brody et al, Modern Pathology, 2009; 22:651-9
Wild et al, J Gastrointest Oncol, 2015; 6:115-125
Liu et al, Nature Medicine, 2014; 20:596-8.

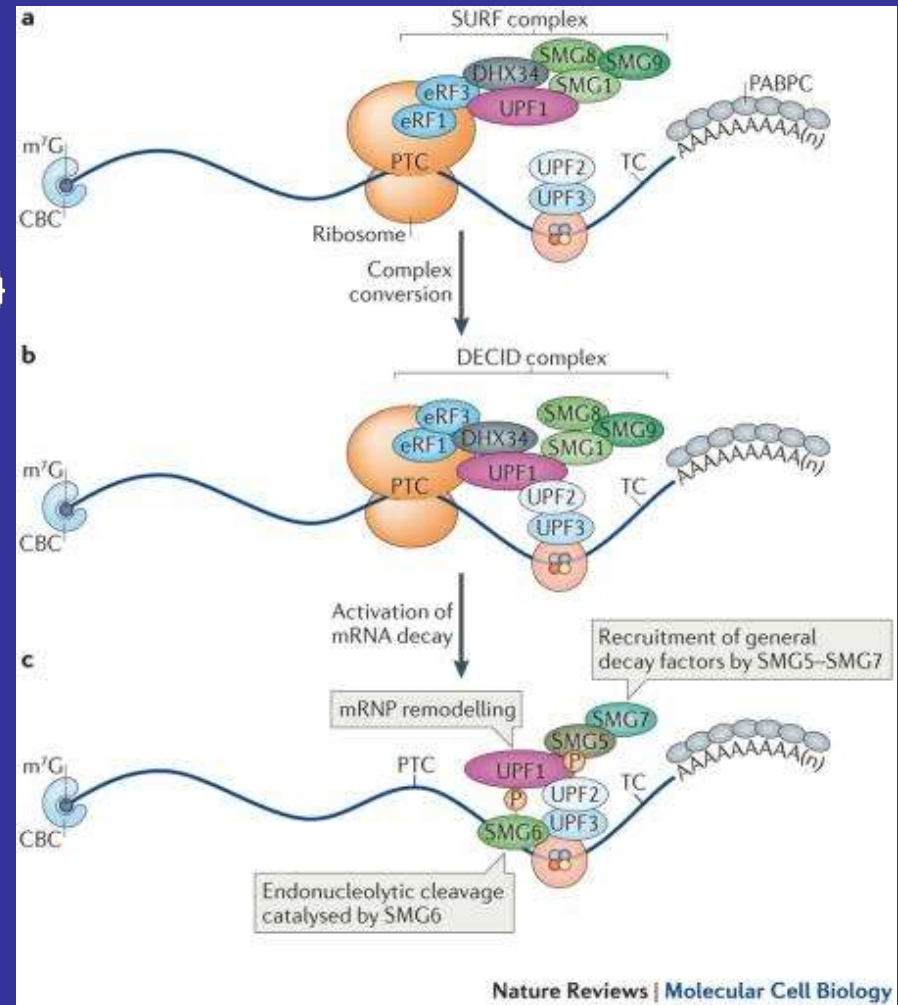


Translation of protein

Lewis et al.,
PNAS



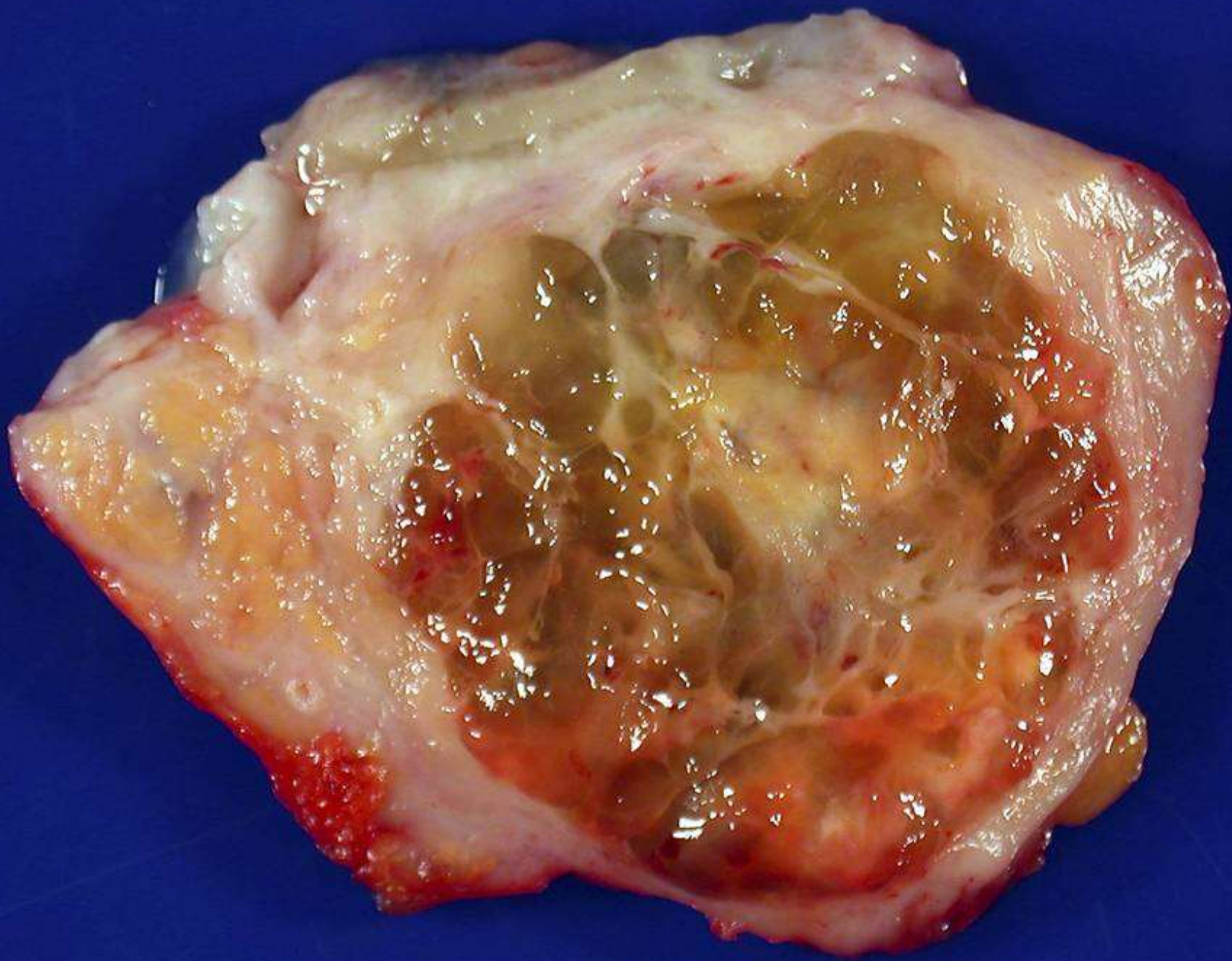
Transcript is degraded by NMD pathway

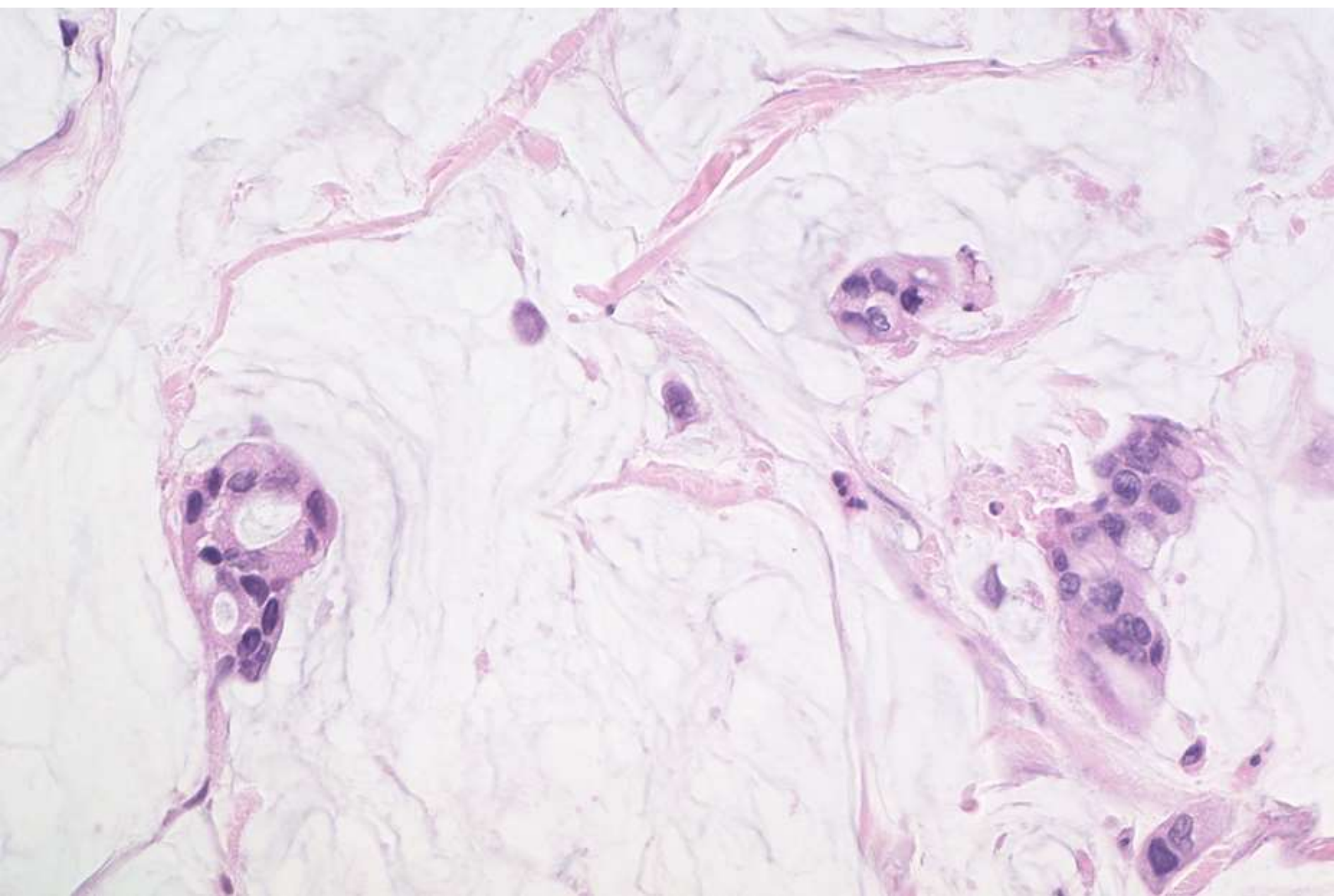


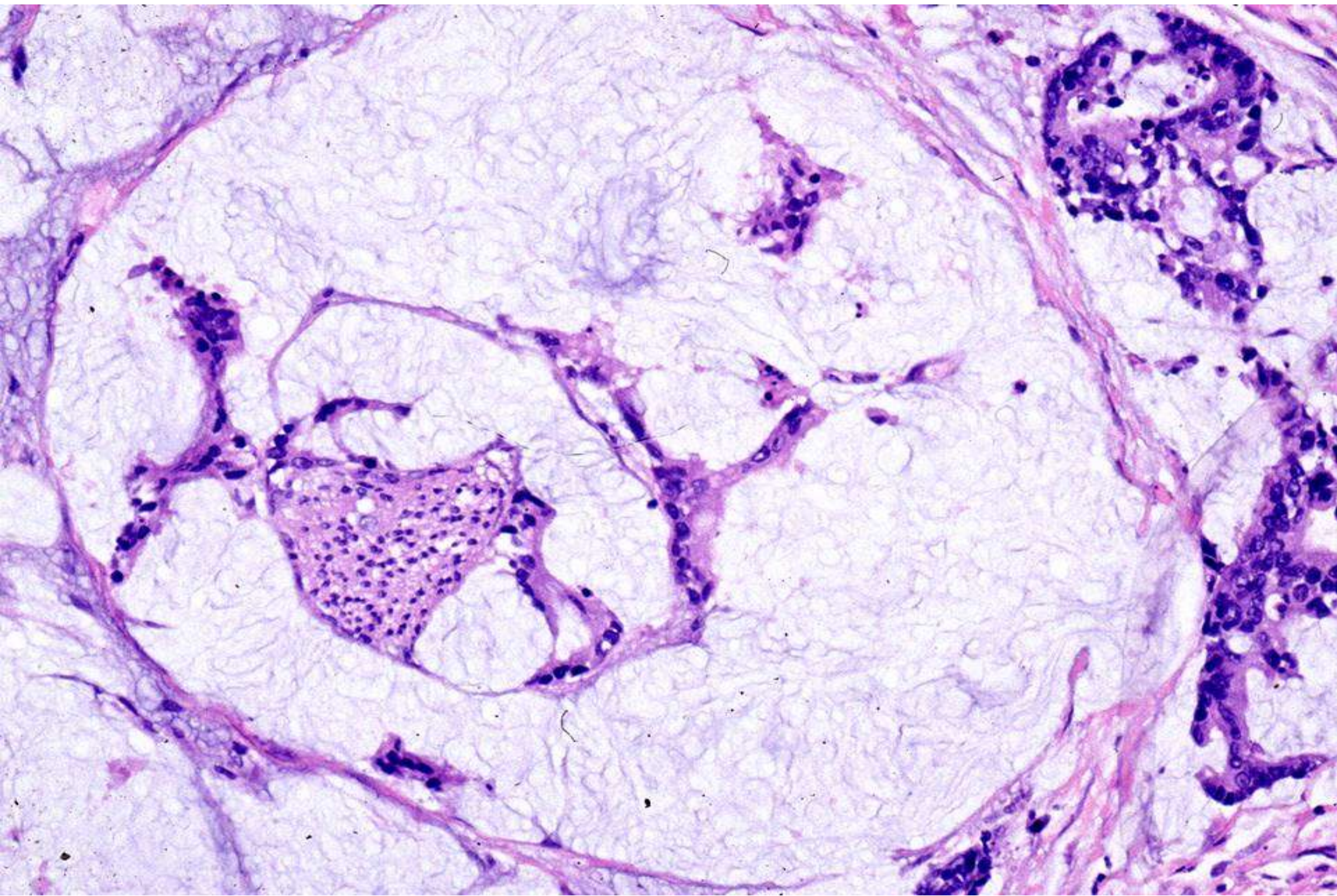
Nature Reviews
Molecular Cell Biology
Volume: 17, Pages:41-54

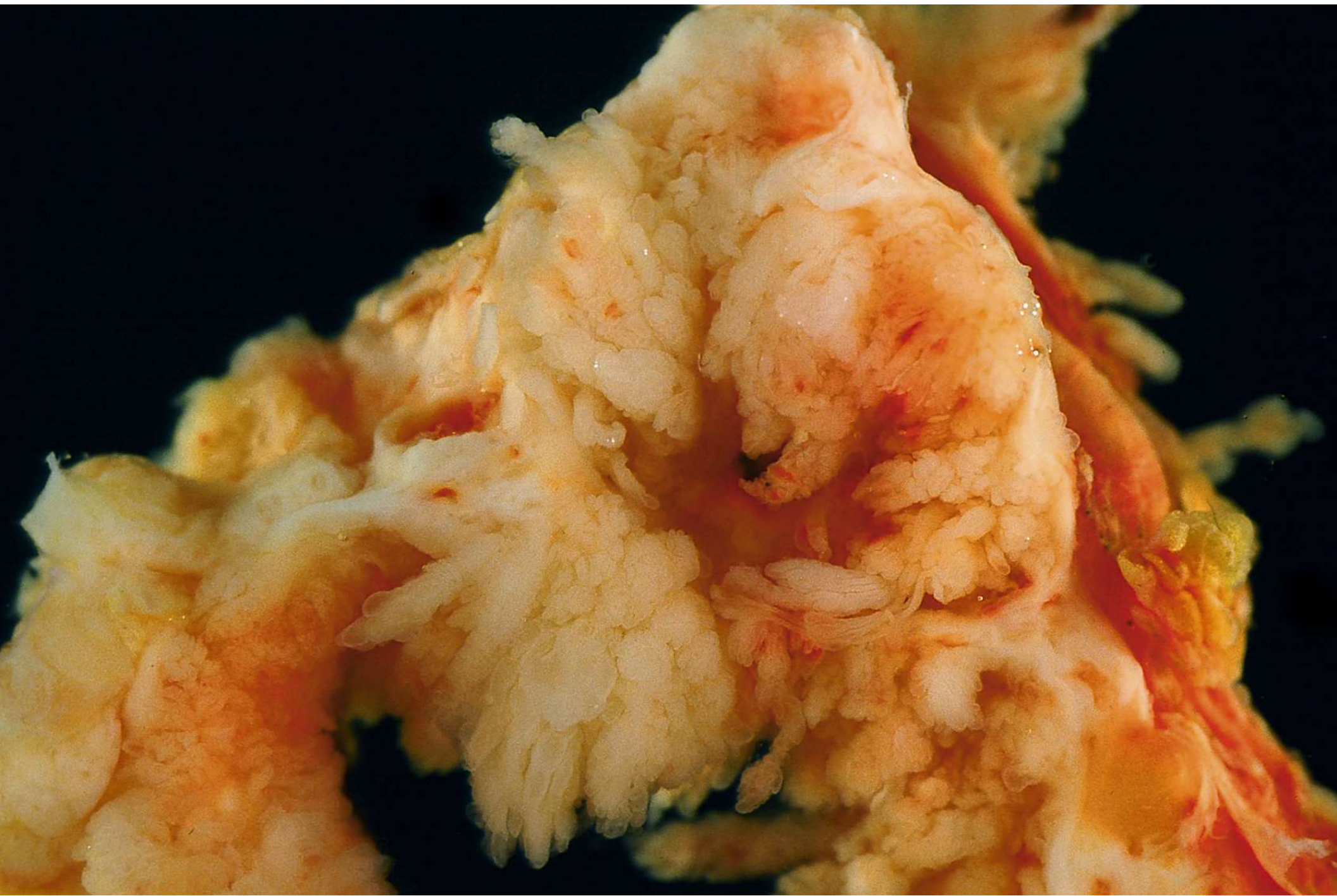
Colloid Carcinoma

- An infiltrating adenocarcinoma characterized by mucin producing neoplastic epithelial cells suspended (“floating”) in large pools of extracellular mucin
- The colloid component should comprise at least 80% of the neoplasm
- 1-3% of the malignancies of the exocrine pancreas
- Grossly soft gelatinous
- Almost always associated with an IPMN
- 5-year survival rates as high as 57%









Genetics of IPMNs

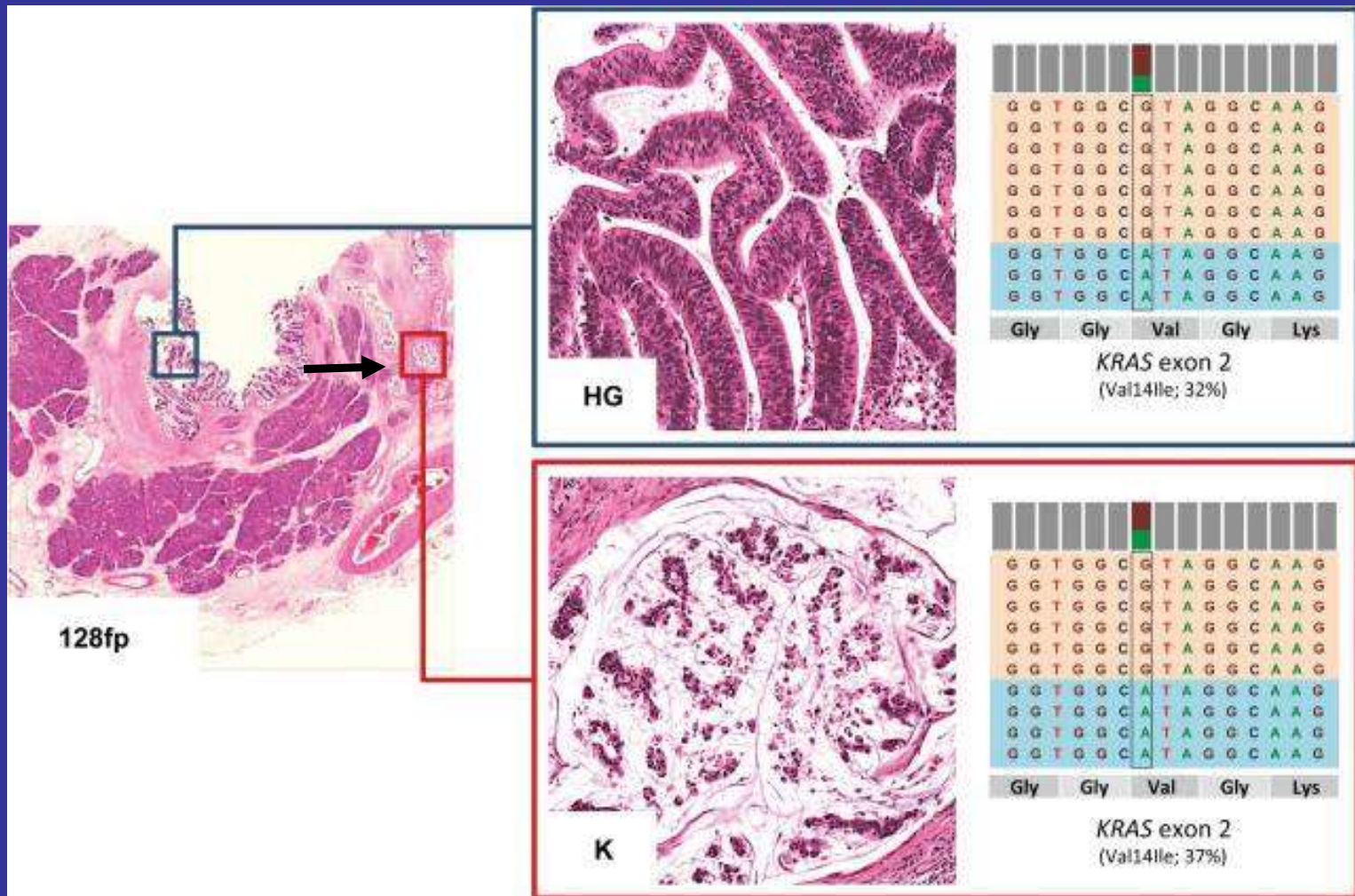
- Targeted sequencing of >50 genes in a panel of 48 intraductal papillary neoplasms.
- *GNAS* and/or *KRAS* mutations were found in 44/48 (92%) of the IPMNs.
- *RNF43* was the third most commonly mutated gene.
- *TP53* and *SMAD4* in high-grade dysplasia/invasive carcinoma.

Scarpa et al, J Pathol 2014; 233:
217–227

J. Wu et al, PNAS 2011

J. Wu et al, Sci Trans Med 2011

Colloid Carcinomas Share Genetic Alterations In the IPMNs From Which They Arose

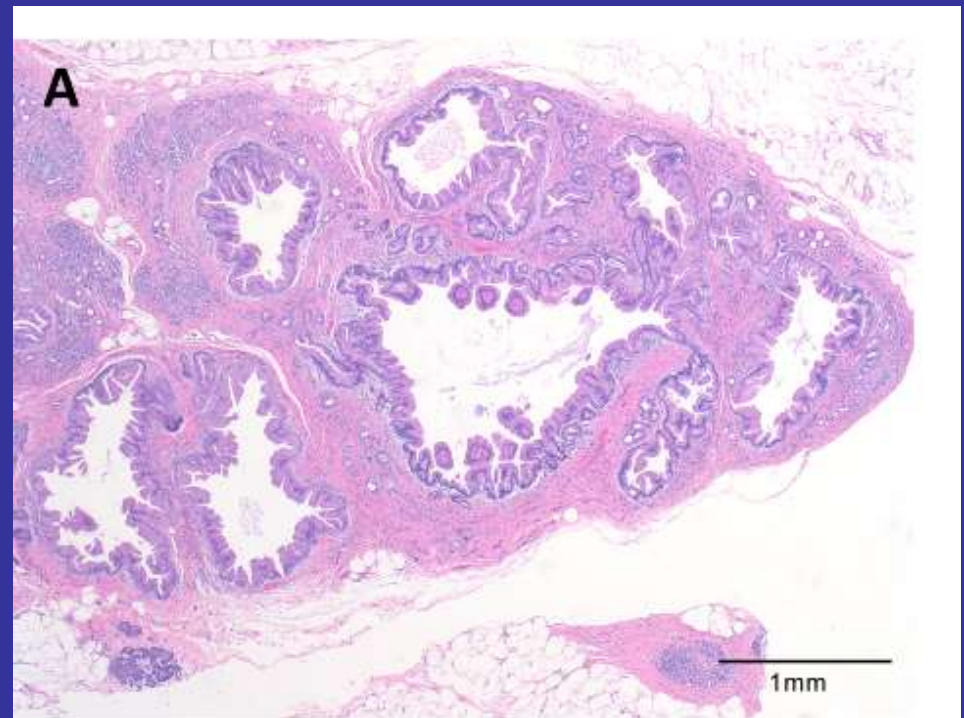


Scarpa, J Pathol. 2014 Jul; 233(3): 217–227.

**Rather than Replacing
the Pathology,
Genetics Can be Used
as a Tool to help
Understand Pathology**

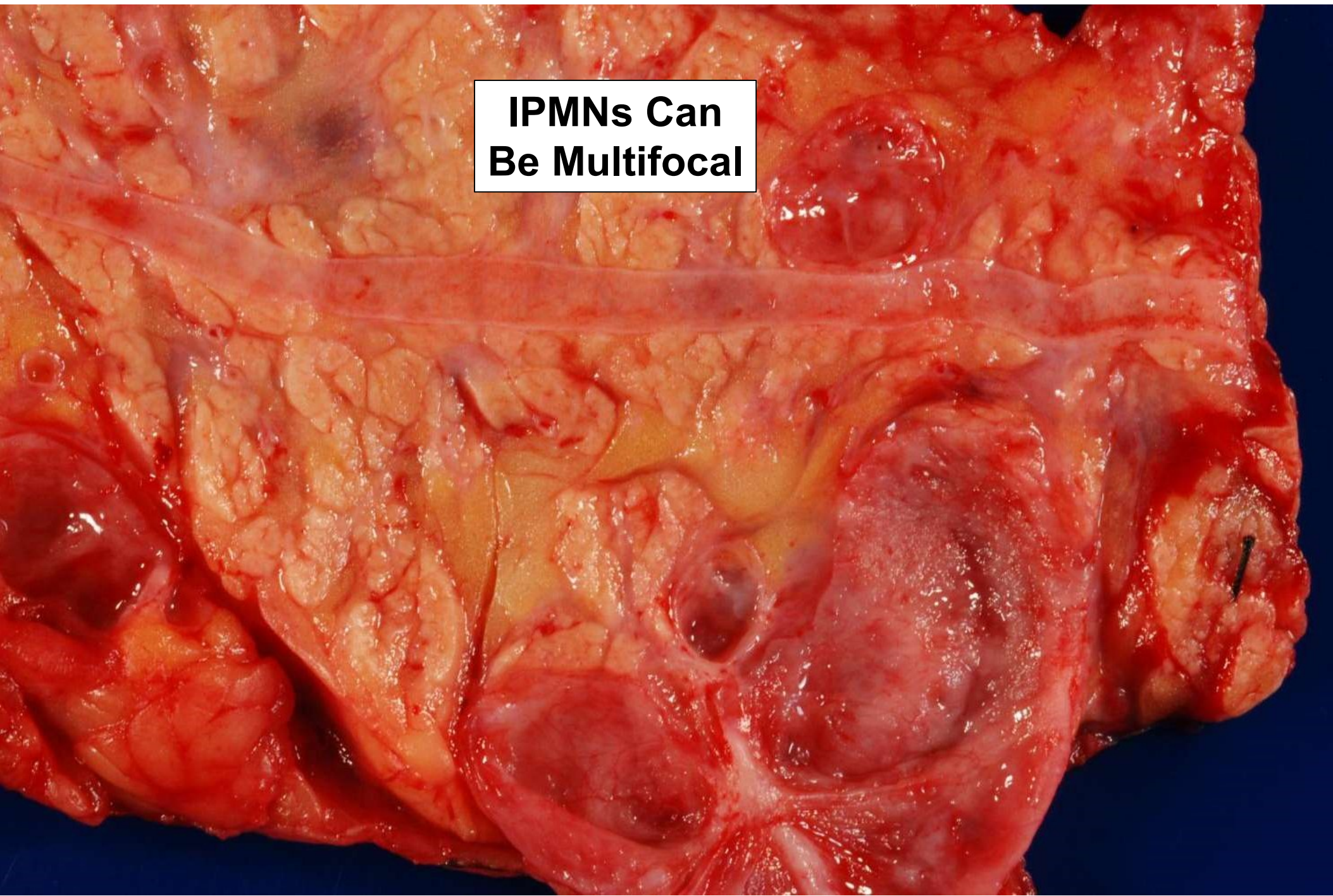
A Tool for Pathologists: PanIN vs. IPMN

- What do we do with the grey zone between PanIN (<0.5cm) and IPMN (<1cm)?
- Mutational analysis revealed *KRAS* codon 12 mutations in all of these inbetween lesions, and 33% harbored *GNAS* codon 201 mutations.
- The presence of *GNAS* mutations in these lesions suggests that a fraction of these are in fact small IPMNs (“incipient IPMNs”).

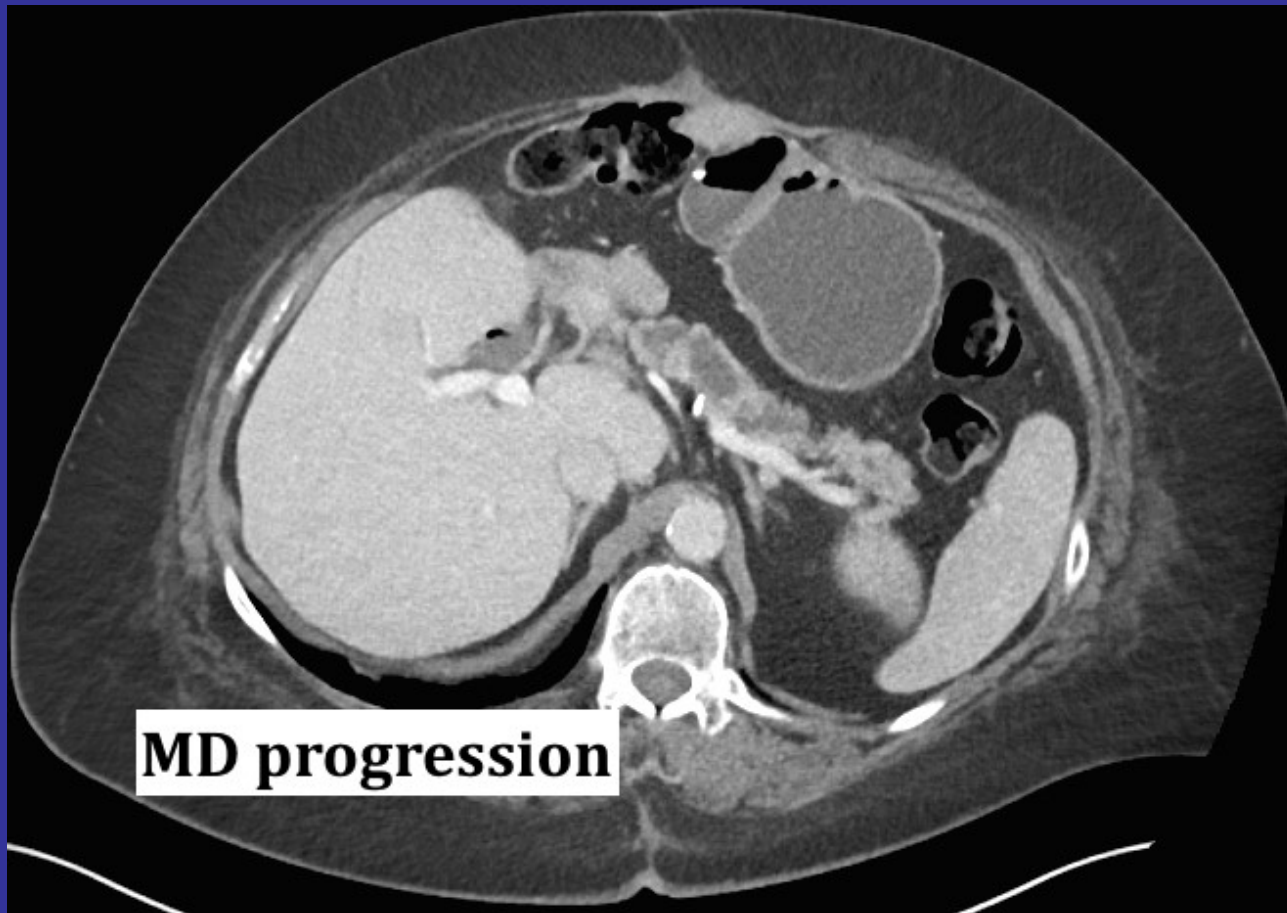


Matthaei, Am J Surg
Pathol 2014;38:360–363

IPMNs Can Be Multifocal

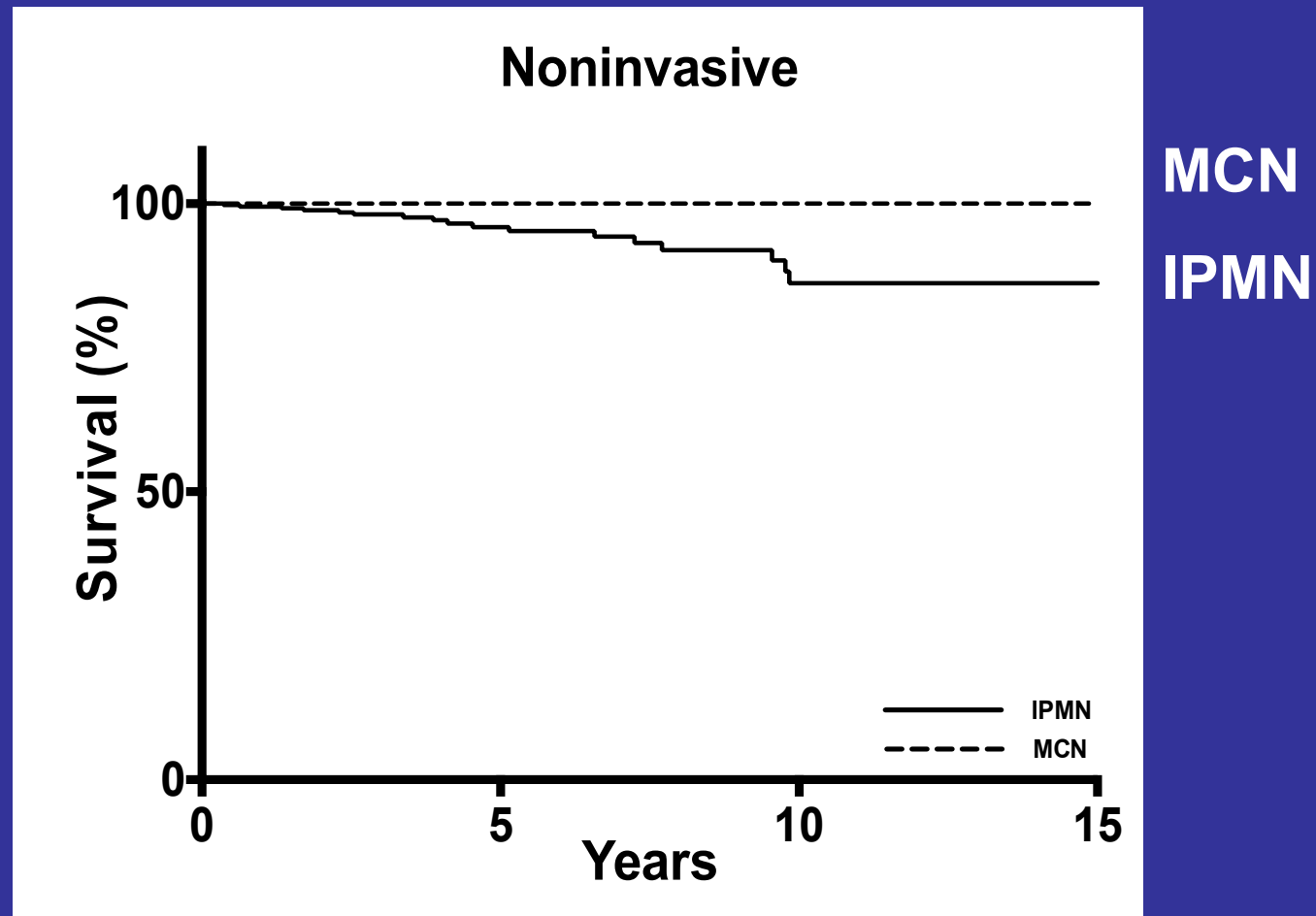


Recurrence of Disease in the Remnant Pancreas is a Big Problem for Patients with an IPMN



A. Pea, Annals of

Multifocality is Clinically Important Kaplan-Meier Survival



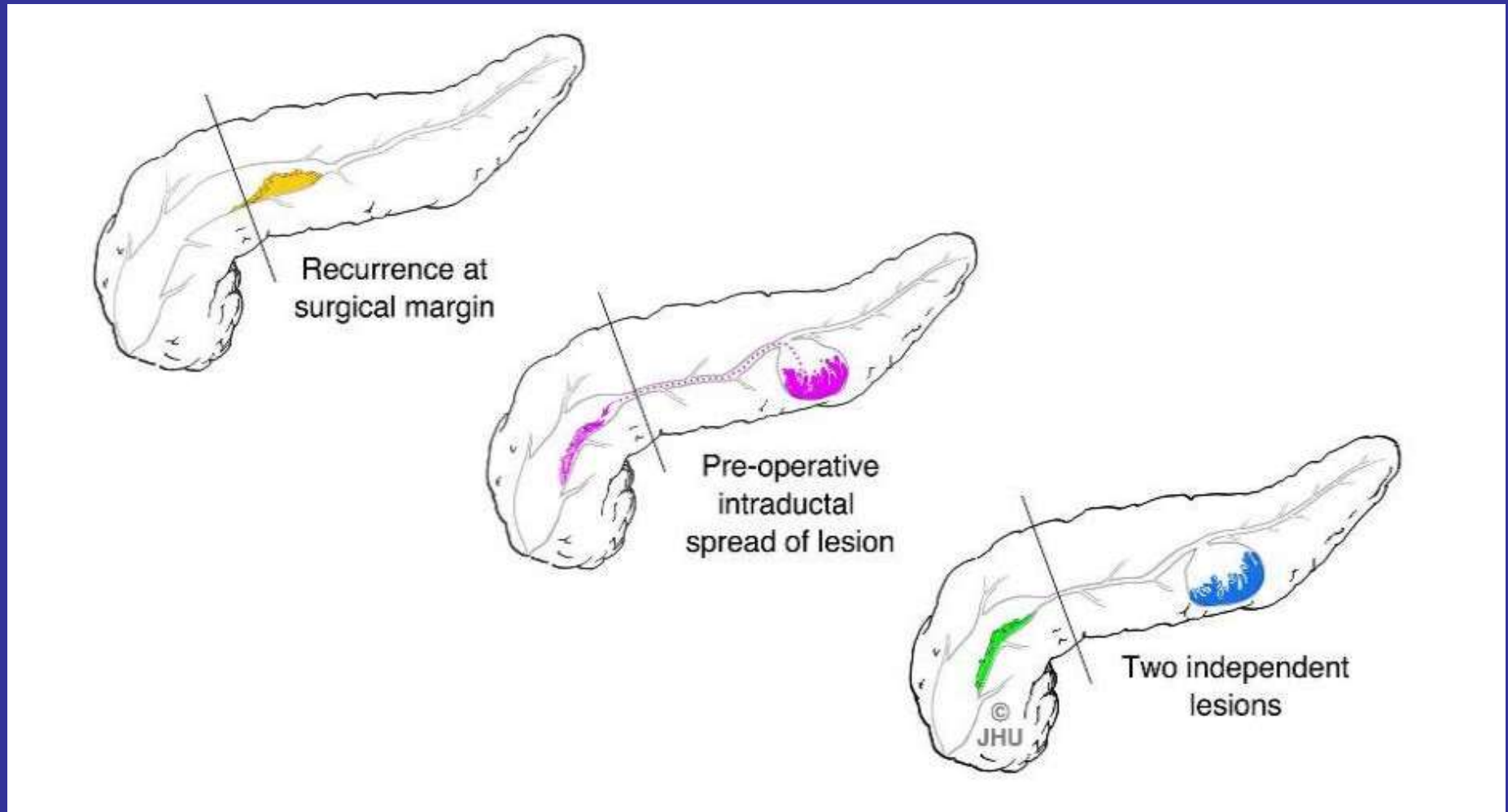
A. Pea, Annals of Surgery, 2016

Synchronous and Metachronous Disease

- Genetic analyses have revealed three mechanisms underlying local progression in the remnant pancreas:
- (1) residual microscopic disease at the resection margin,
- (2) intraparenchymal/Intraductal spread of neoplastic cells, leading to an anatomically separate but genetically related recurrence, and
- (3) multifocal disease with genetically distinct lesions.

A. Pea, Annals of Surgery, 2016

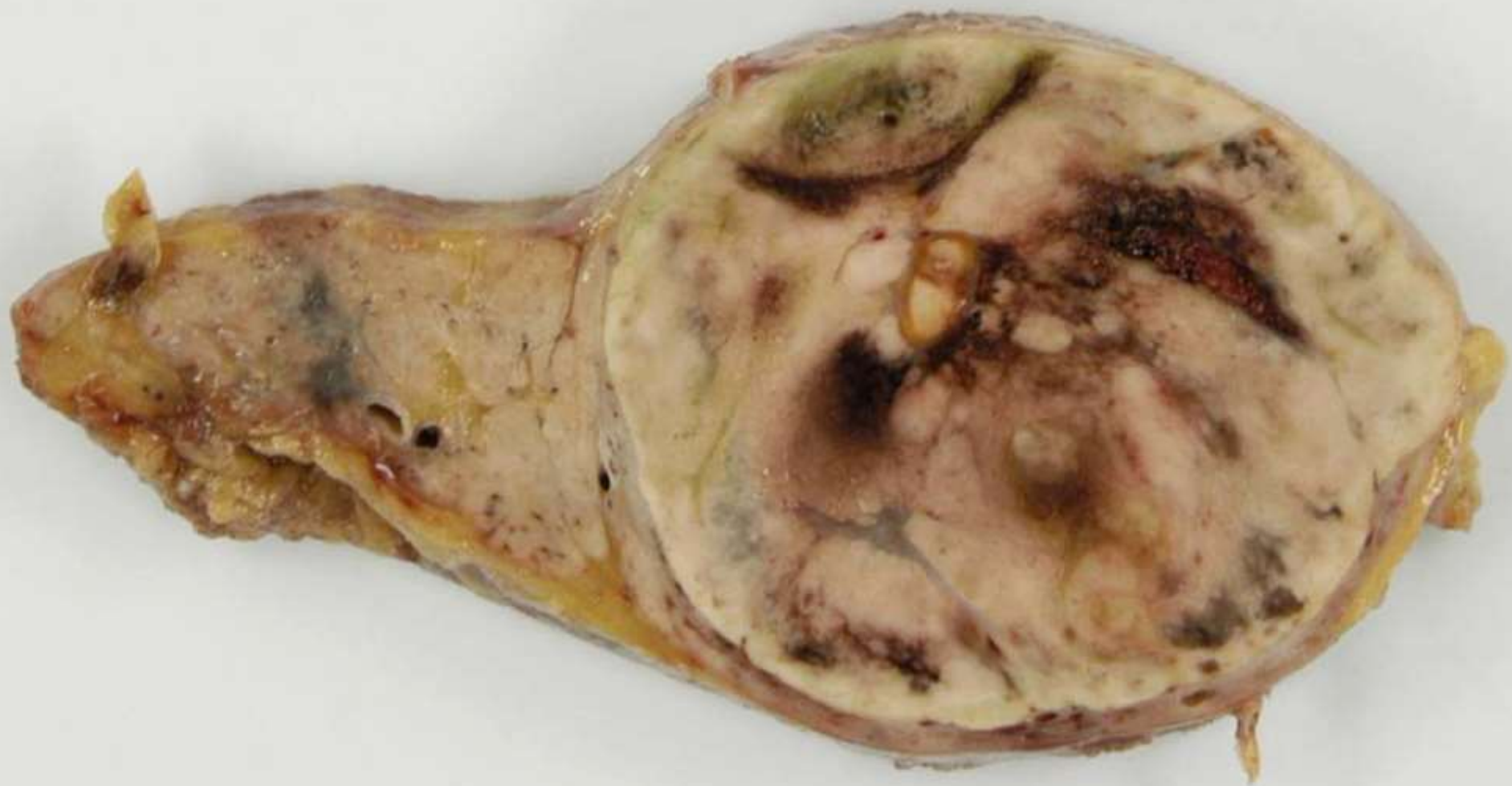Clinical Implications

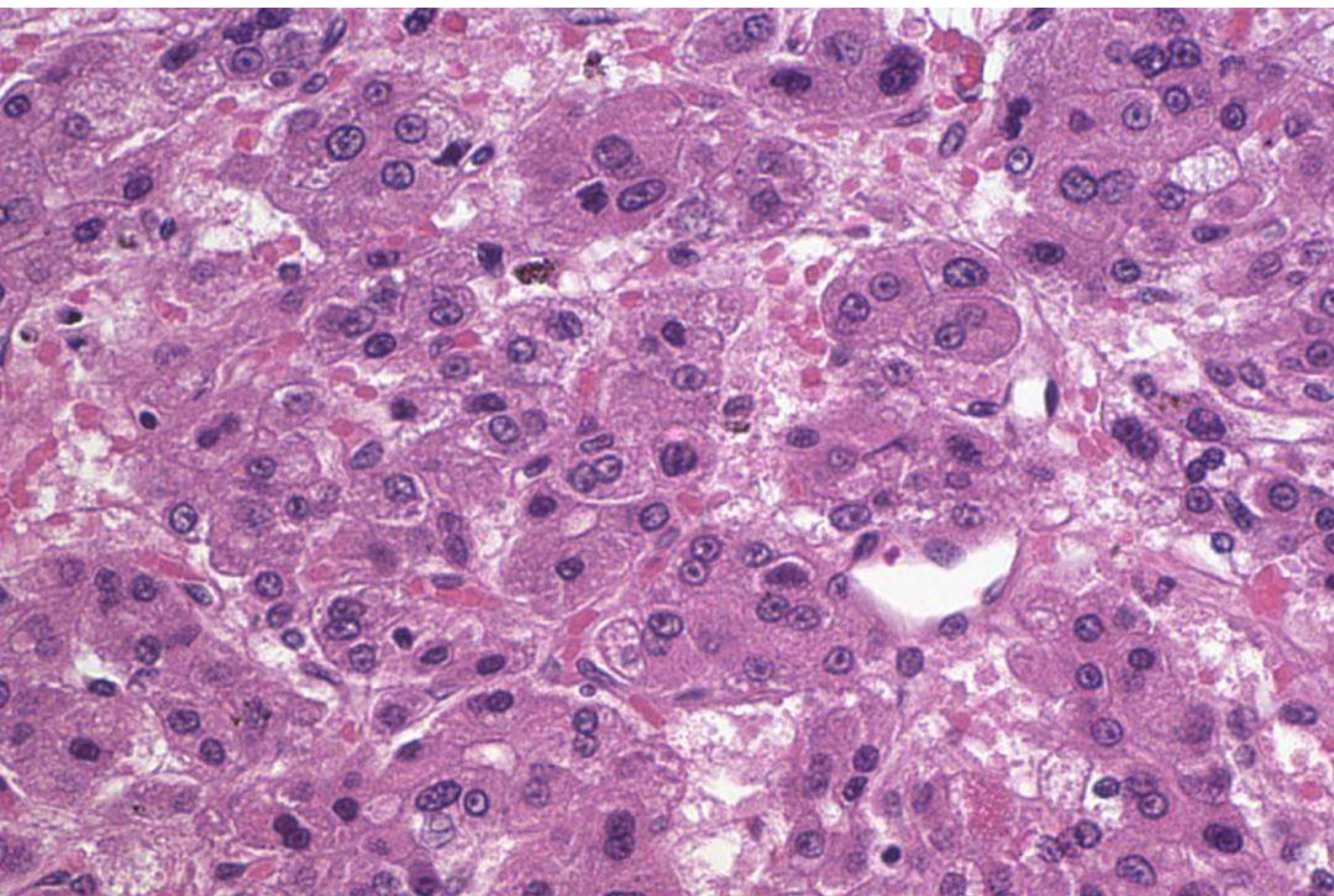


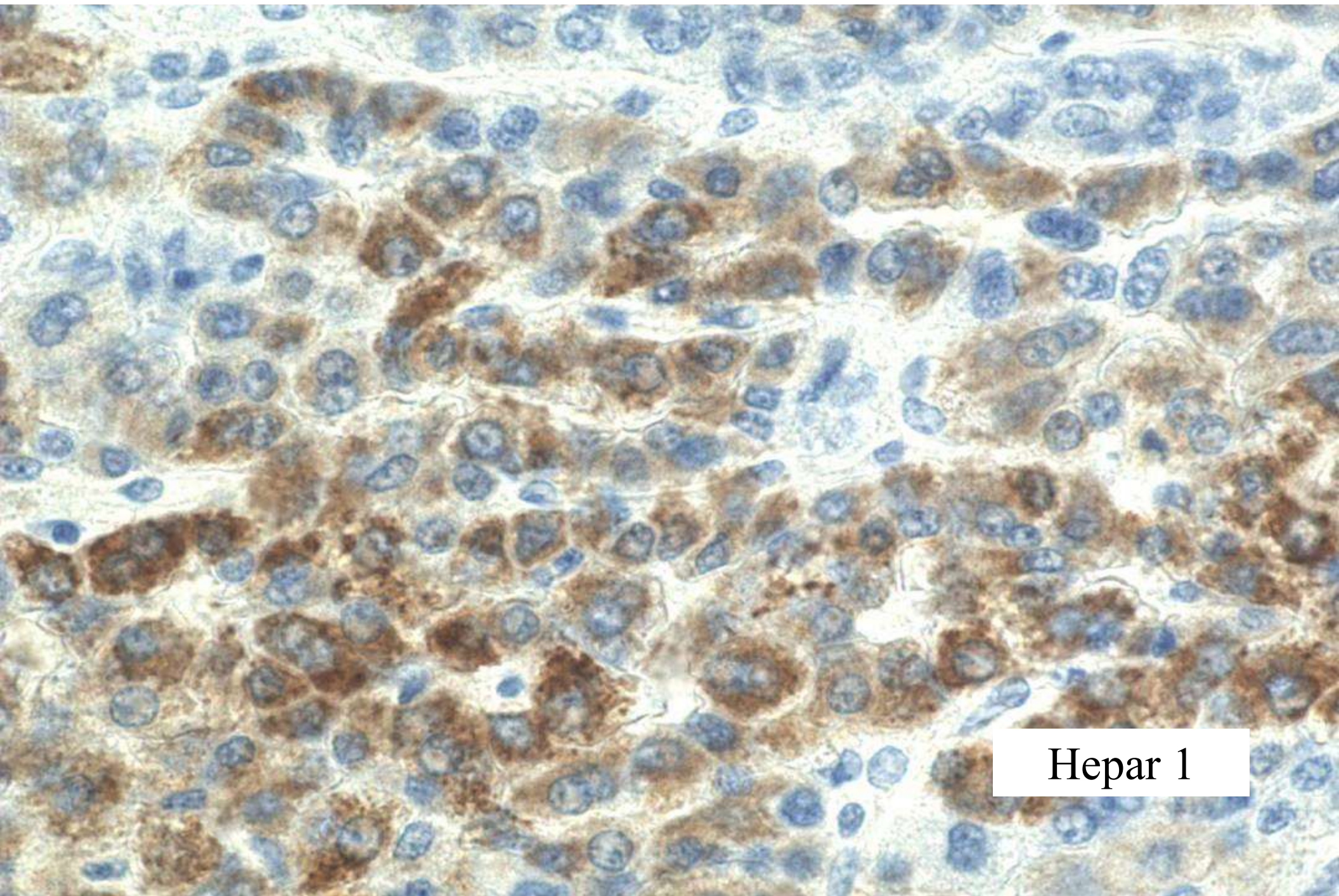
A. Pea, Annals of Surgery, 2016

Hepatoid Carcinoma

- A malignant epithelial neoplasm in which a significant component shows hepatocellular differentiation
- Only a handful have been reported
- Large polygonal cells with abundant eosinophilic cytoplasm
- The cells form trabecula and may have a sinusoidal vascularity
- Immunolabeling for polyclonal carcinoembryonic antigen and for CD10 produce a canalicular pattern of labeling in some cases



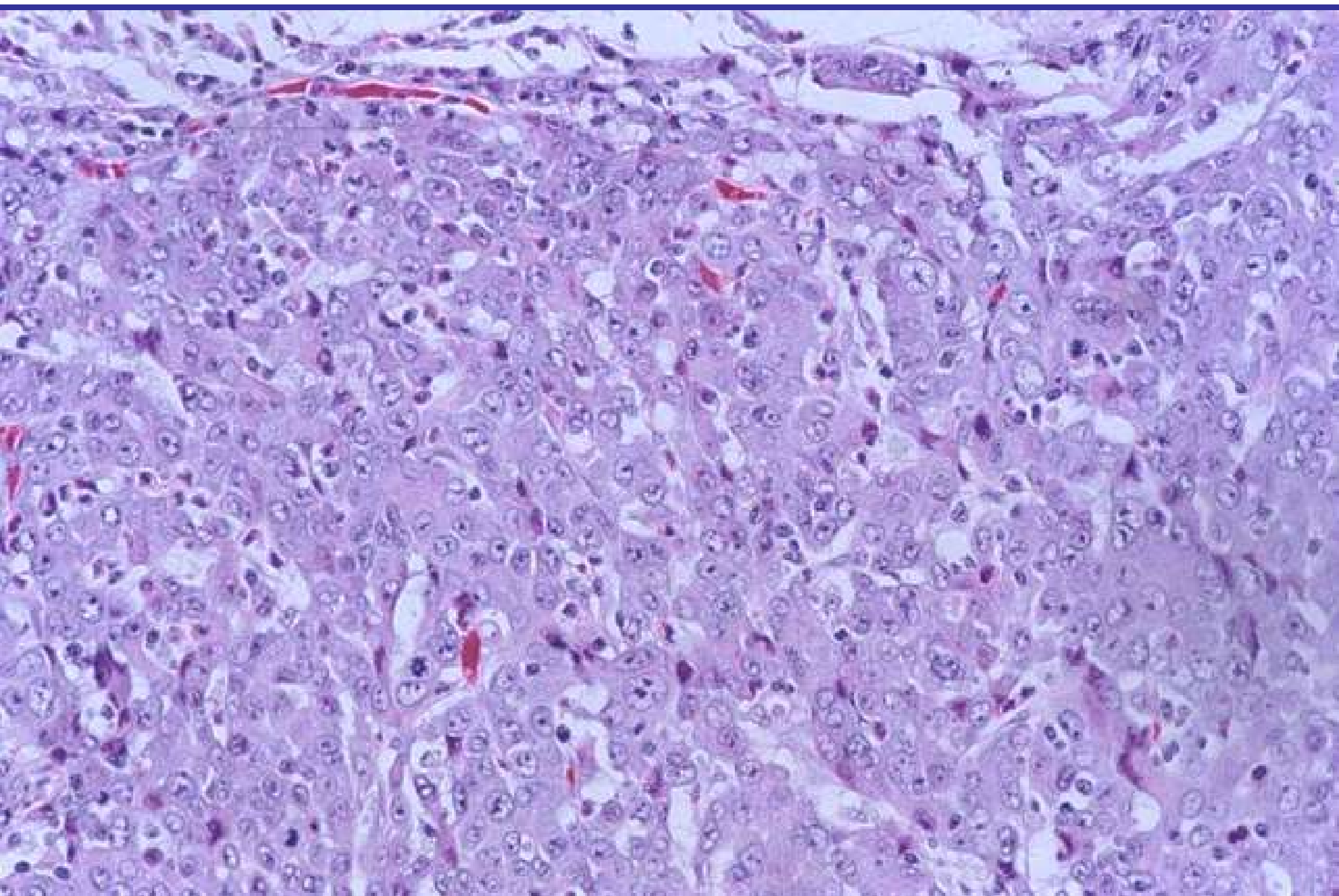


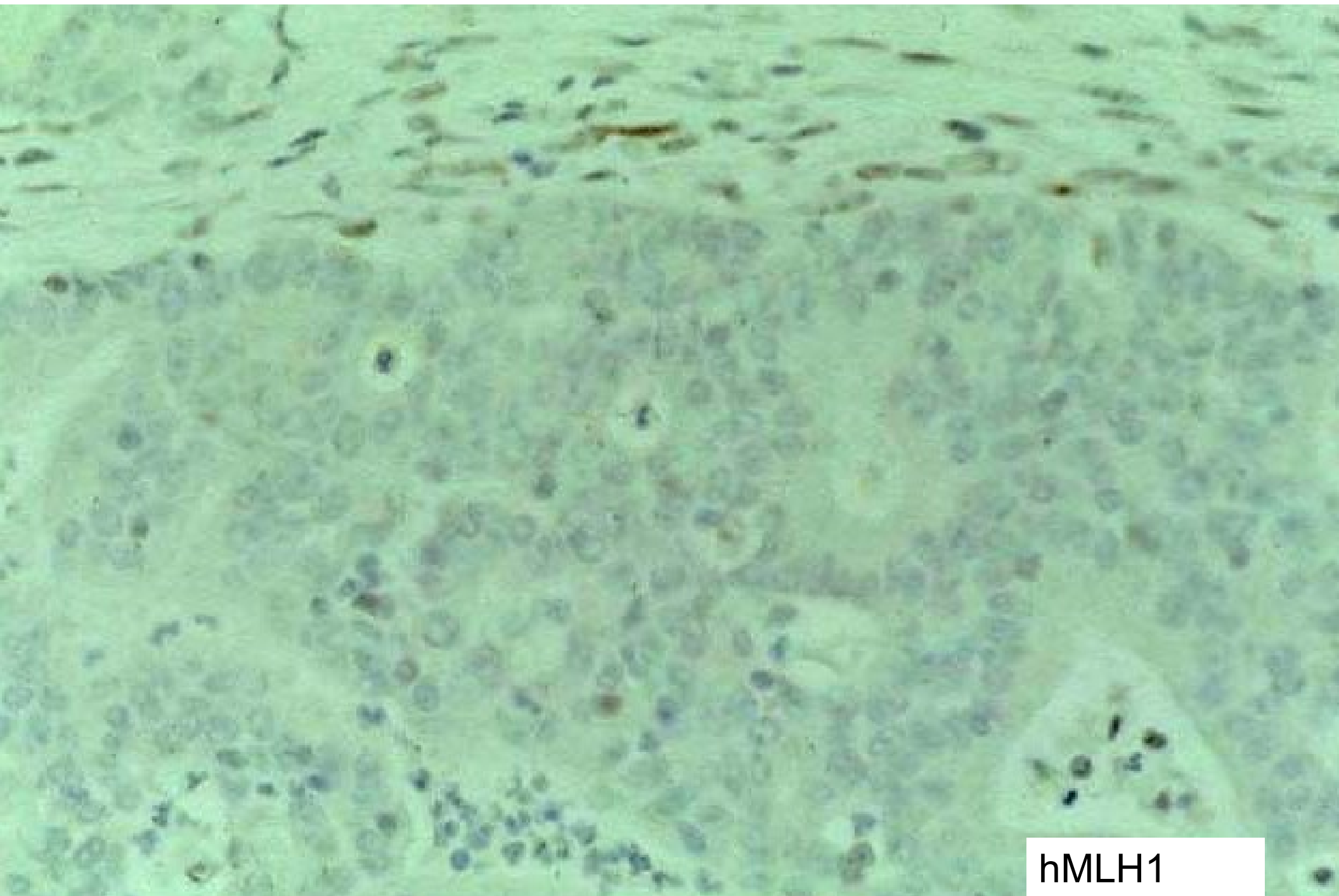


Hepar 1

Medullary Carcinoma

- A malignant epithelial neoplasm characterized by poor differentiation, pushing borders, a syncytial growth pattern and necrosis
- May have prominent intratumoral lymphocytes
- Immunolabeling for Mlh1 and Msh2 reveals loss of expression of one of these DNA mismatch repair proteins in many of the cancers
- Many, but not all, carcinomas with medullary histology have microsatellite instability
- *KRAS* wild-type, 33% *BRAF* mutations
- Family history of cancer
- Trend towards longer survival



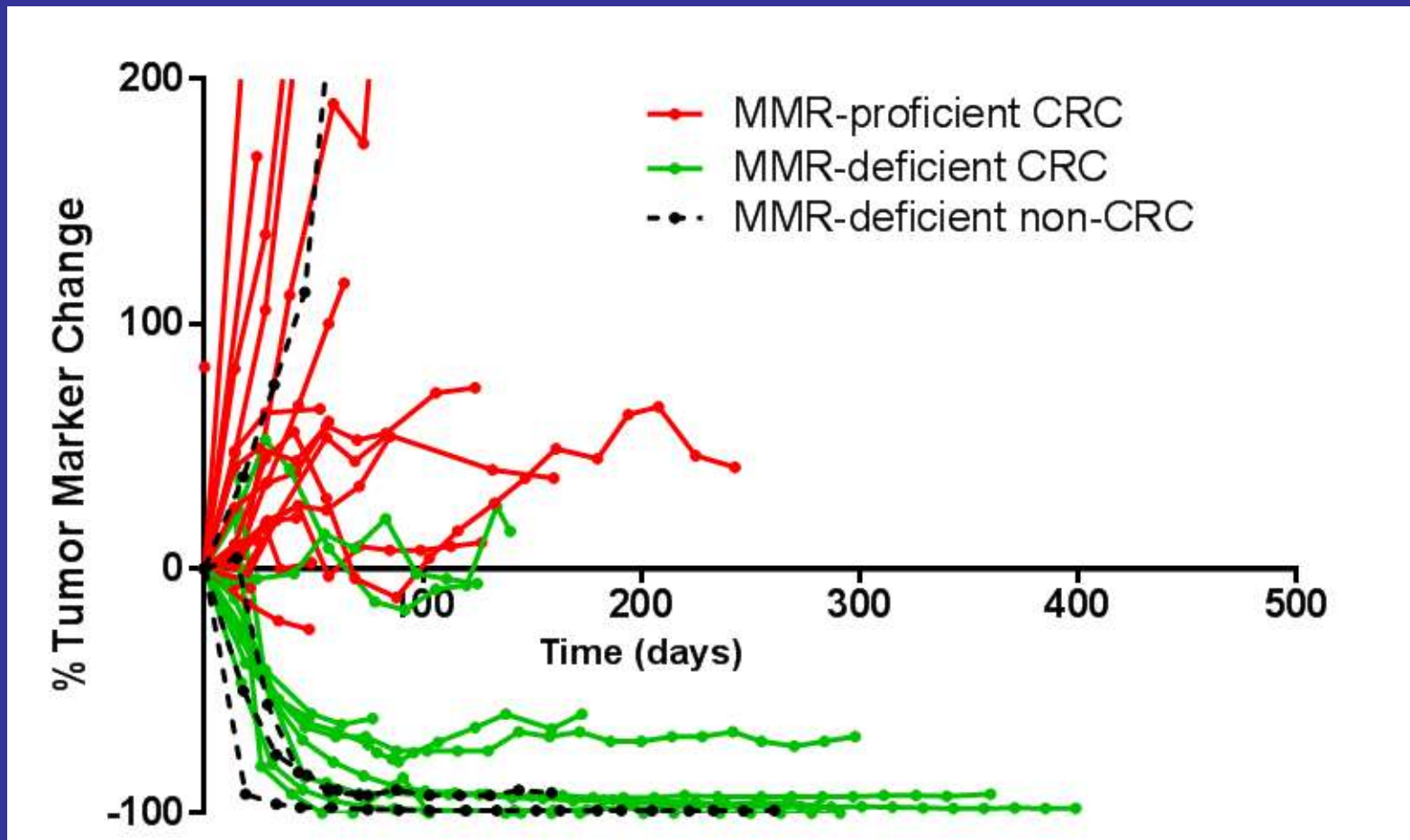


hMLH1

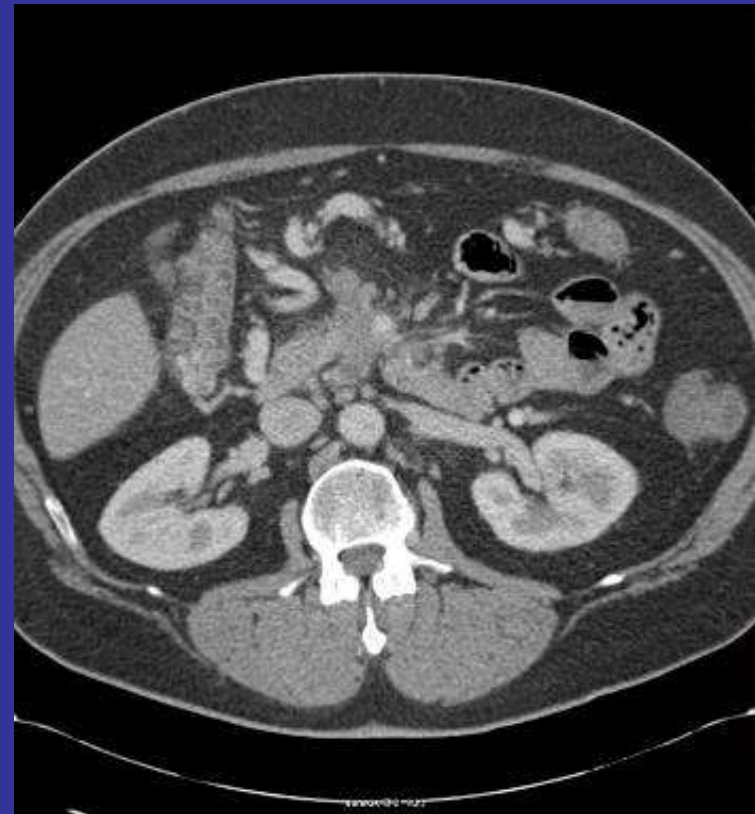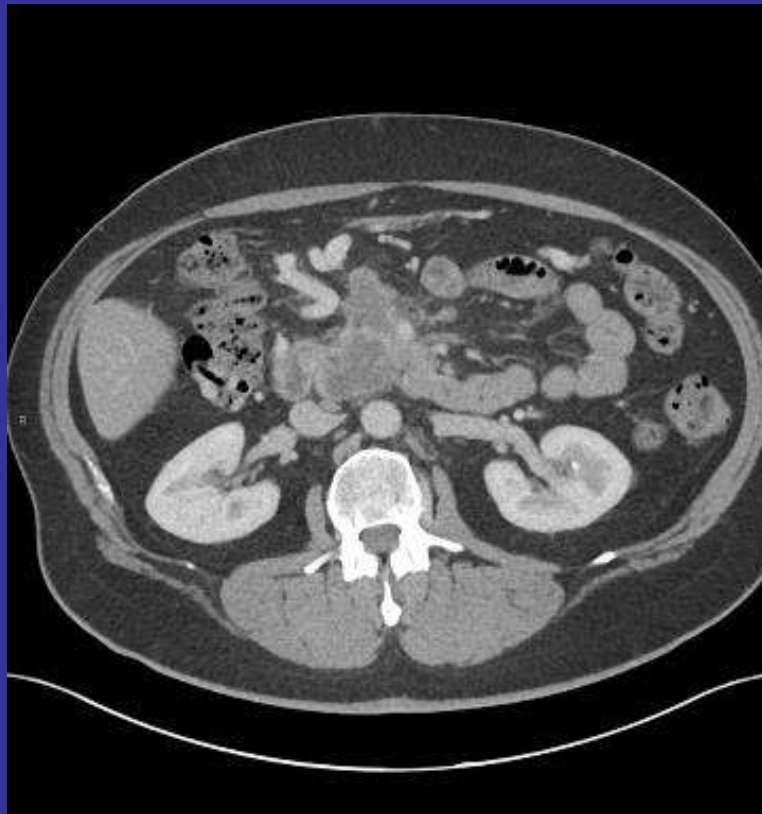1 2 3 4 5 6 7 8 9
N I N I N I N I N I N I N I N I



Microsatellite Instability and Response to Pembrolizumab

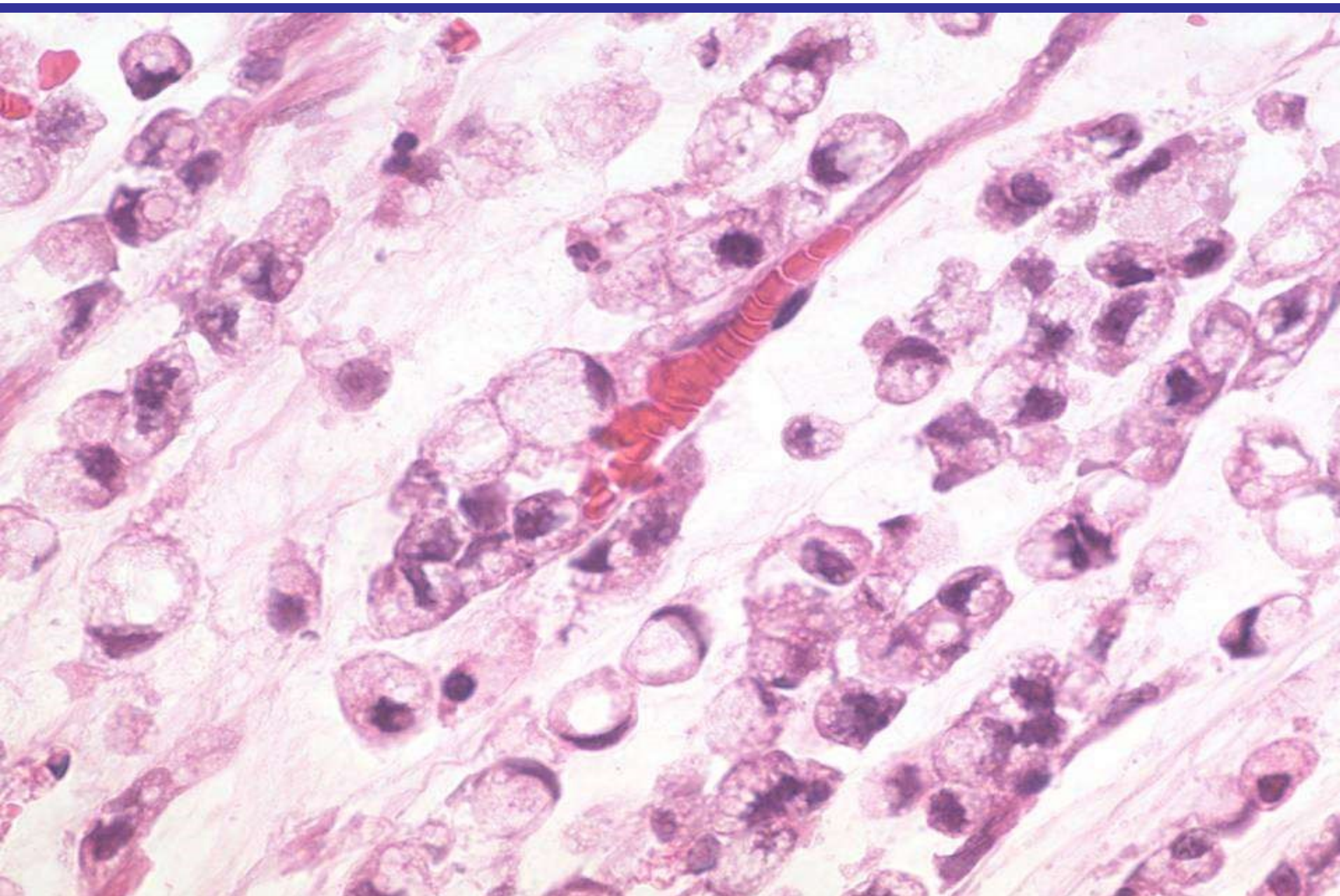


Microsatellite Instability and Response to Pembrolizumab



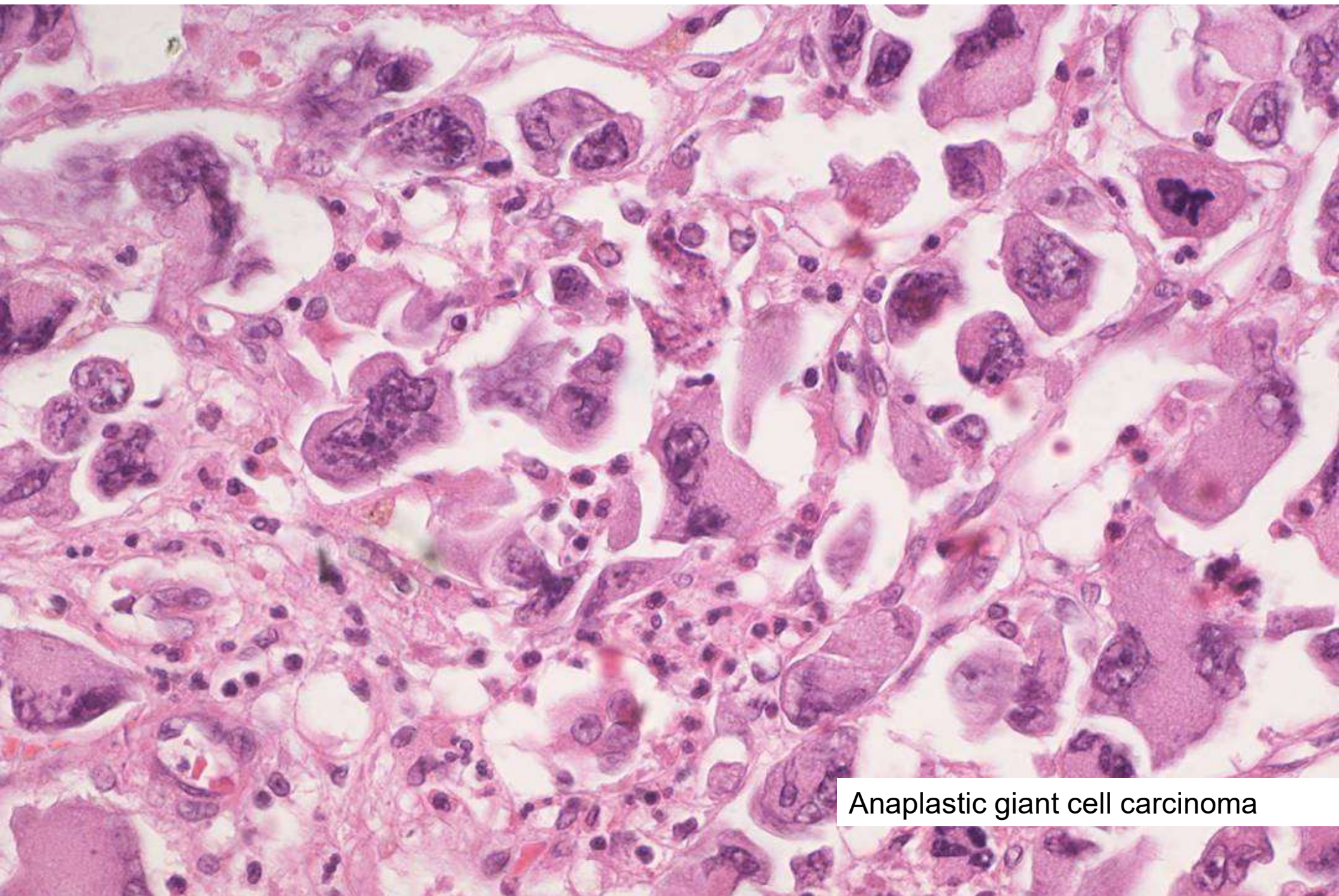
Signet Ring Carcinoma

- A malignant epithelial neoplasm in which the predominant component is composed of infiltrating round non-cohesive (isolated) cells containing intracytoplasmic mucin
- At least half of the neoplasm consist of signet ring cells
- Metastases to the pancreas from a gastric or mammary primary need to be excluded

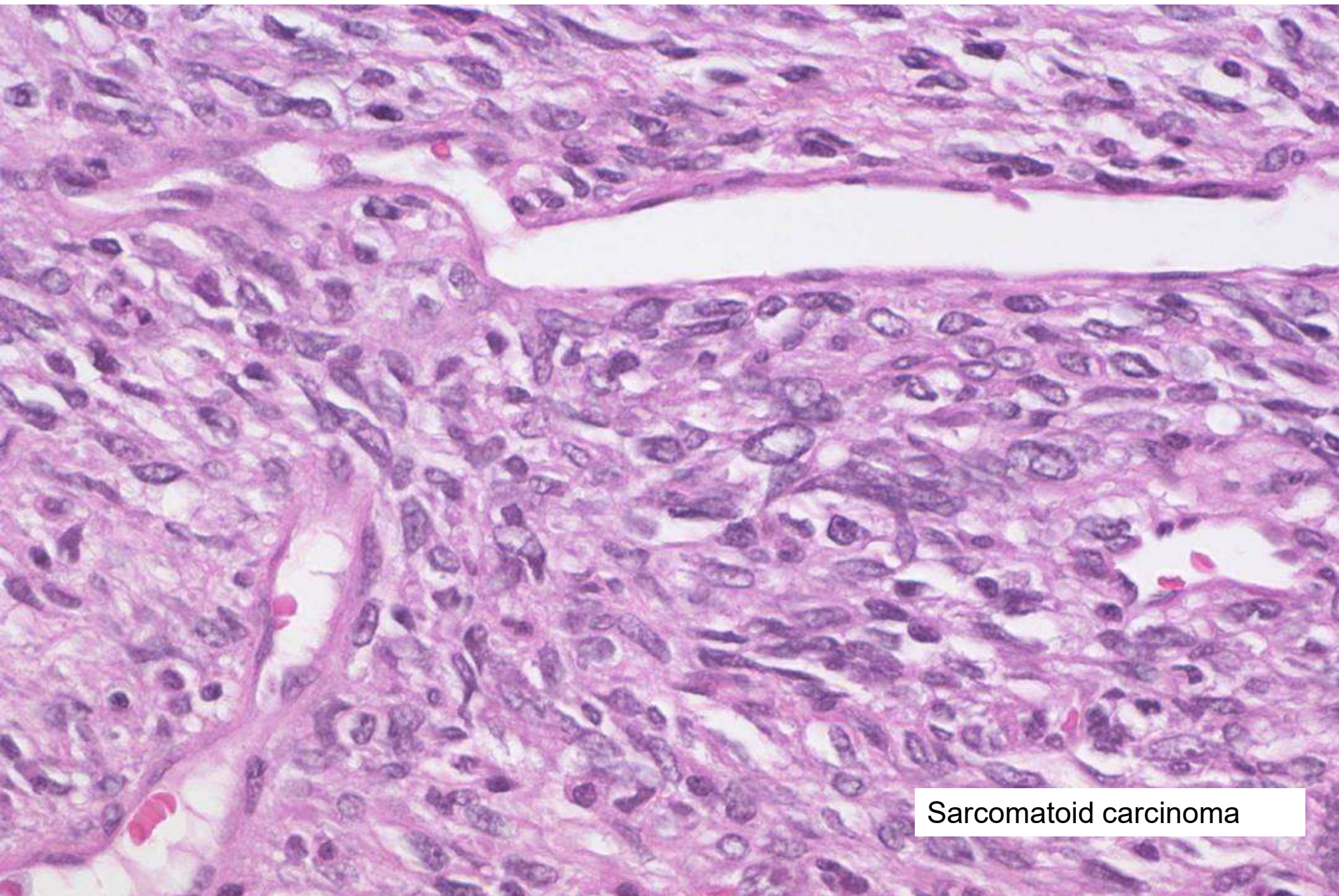


Undifferentiated Carcinoma

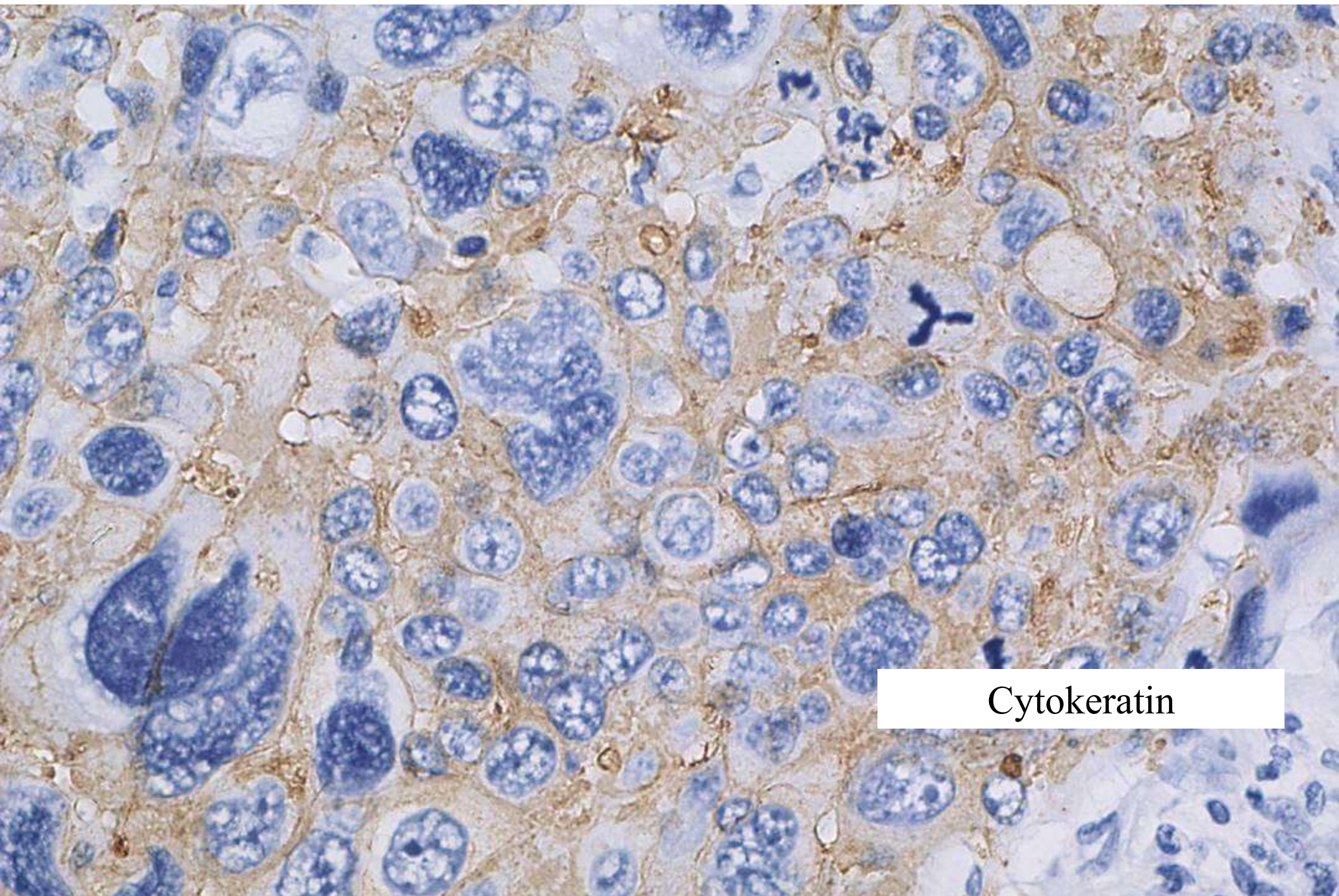
- A malignant epithelial neoplasm with a significant component showing no glandular structures or other features to indicate a definite direction of differentiation
- Range from pleomorphic epithelioid mononuclear cells containing abundant eosinophilic cytoplasm admixed with bizarre frequently multinucleated giant cells, to relatively monomorphic spindle cells
- May arise de novo or they may occur in association with a mucinous cystic neoplasm or other pancreatic neoplasms
- Mean survival of 5.2 months after diagnosis



Anaplastic giant cell carcinoma



Sarcomatoid carcinoma



Cytokeratin

E-cadherin Expression

	<u>E-cadherin loss</u>
<u>Noncohesive carcinoma</u>	
Undifferentiated carcinoma	
-Anaplastic	14/15 (93%)
- UCOCGC	6/6 (100%)
Overall	20/21 (95%)*
<u>Cohesive carcinoma</u>	
Ductal adenocarcinoma	
-Moderate	0/24 (0%)
-Poor	0/13 (0%)
Colloid carcinoma	
-Moderate	0/1 (0%)
-Poor	0/1 (0%)
Overall	0/39 (0%)*

Loss of E-cadherin Expression is Seen in Undifferentiated Carcinomas

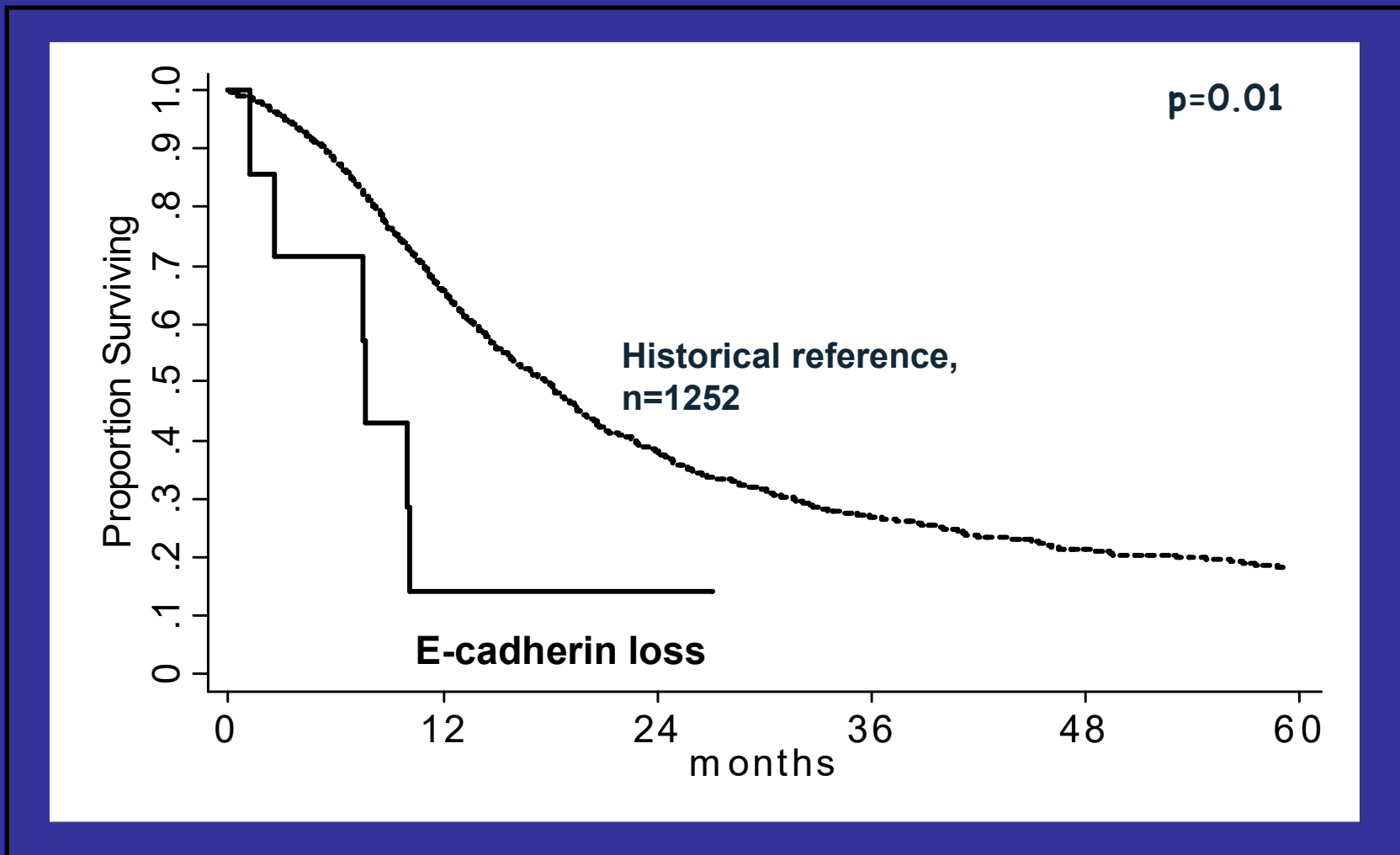
p<0.001

The image shows a histological section of tissue stained for E-cadherin. The tissue is composed of glandular structures, likely from the colon or stomach. The glandular epithelium is stained brown, indicating the presence of E-cadherin. The surrounding stroma contains many small, blue-stained nuclei, representing non-neoplastic cells. The glandular structures are well-organized and maintain their architecture, which is characteristic of well-differentiated cancer. The brown staining is localized to the cell membranes of the glandular epithelium, showing that E-cadherin is intact in this type of cancer. In contrast, the surrounding stroma and non-neoplastic cells show no brown staining, indicating that E-cadherin is not expressed in these cells. The overall appearance is that of a well-differentiated adenocarcinoma with intact E-cadherin expression.

E-cadherin is lost

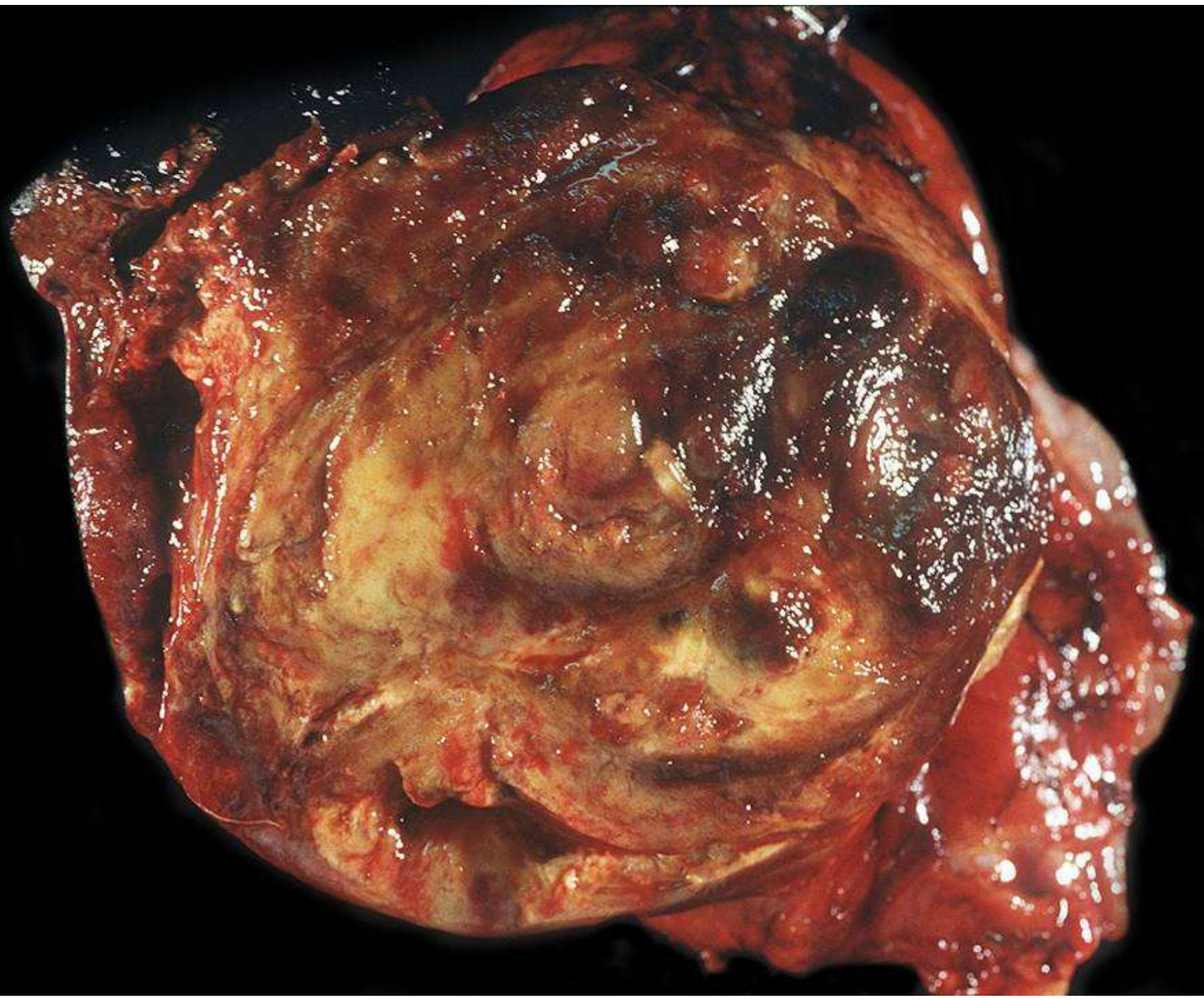
Well-differentiated Cancer=
E-cadherin is intact

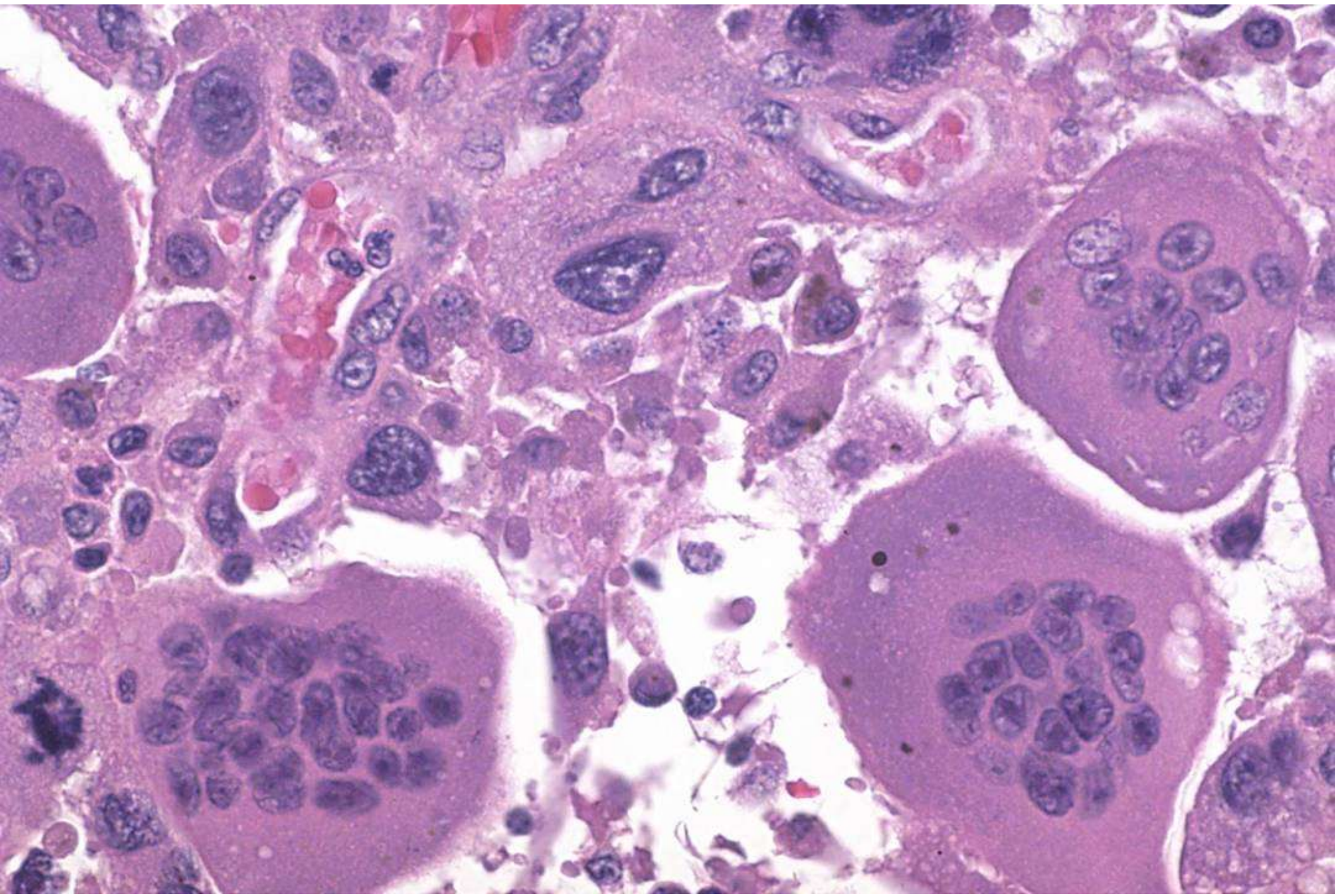
E-cadherin Loss is Associated with Poor Prognosis

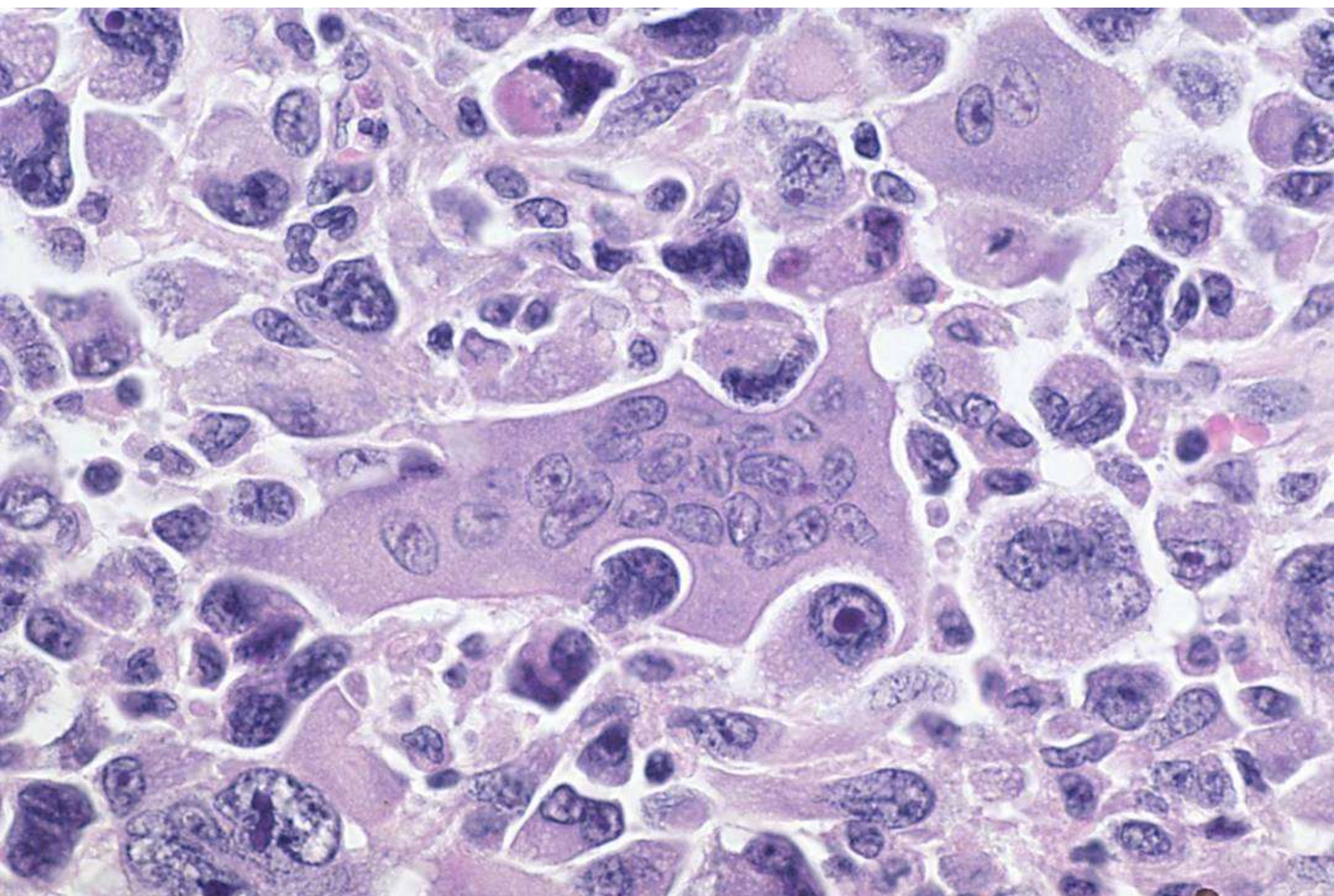


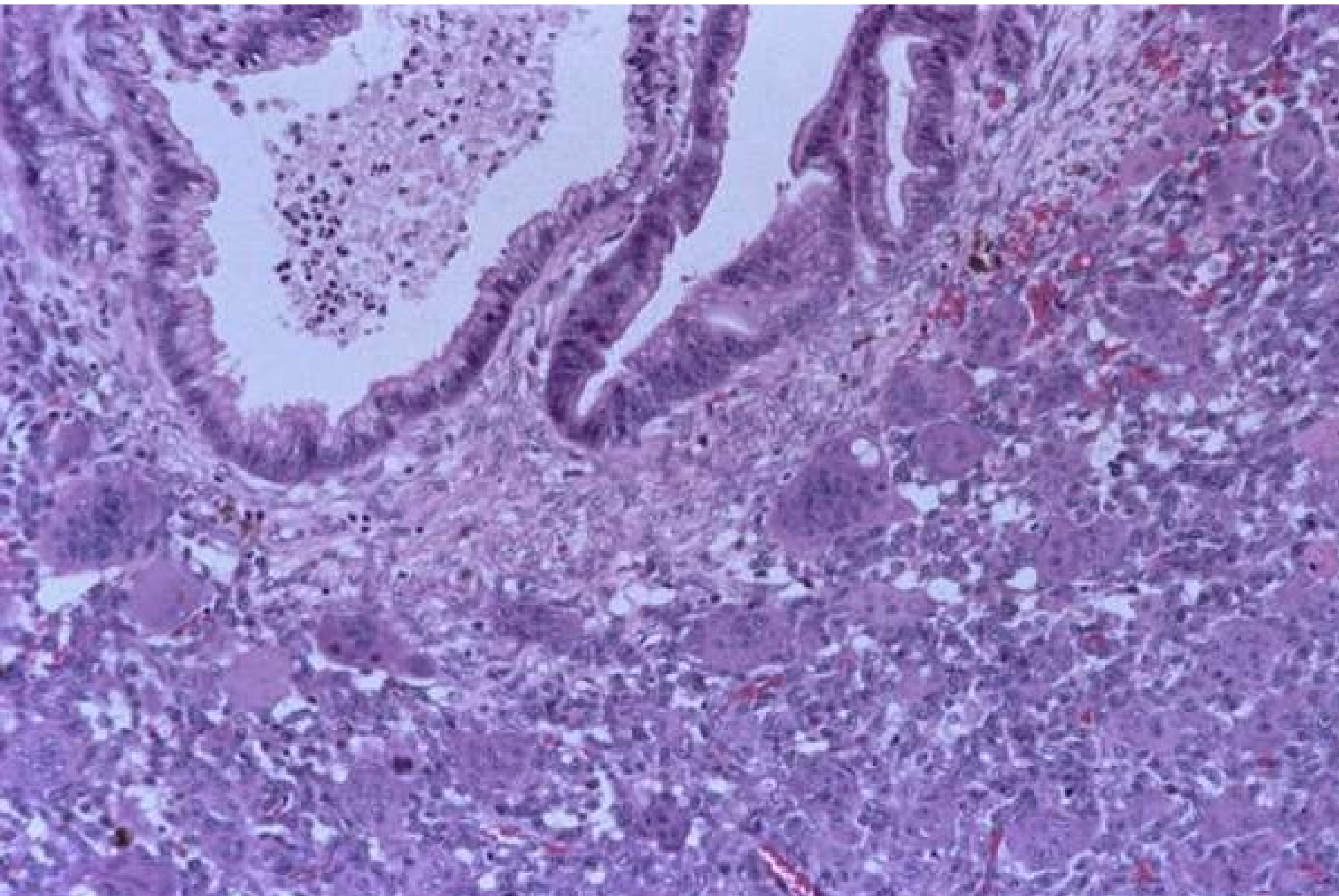
Undifferentiated Carcinoma with Osteoclast-like Giant Cells

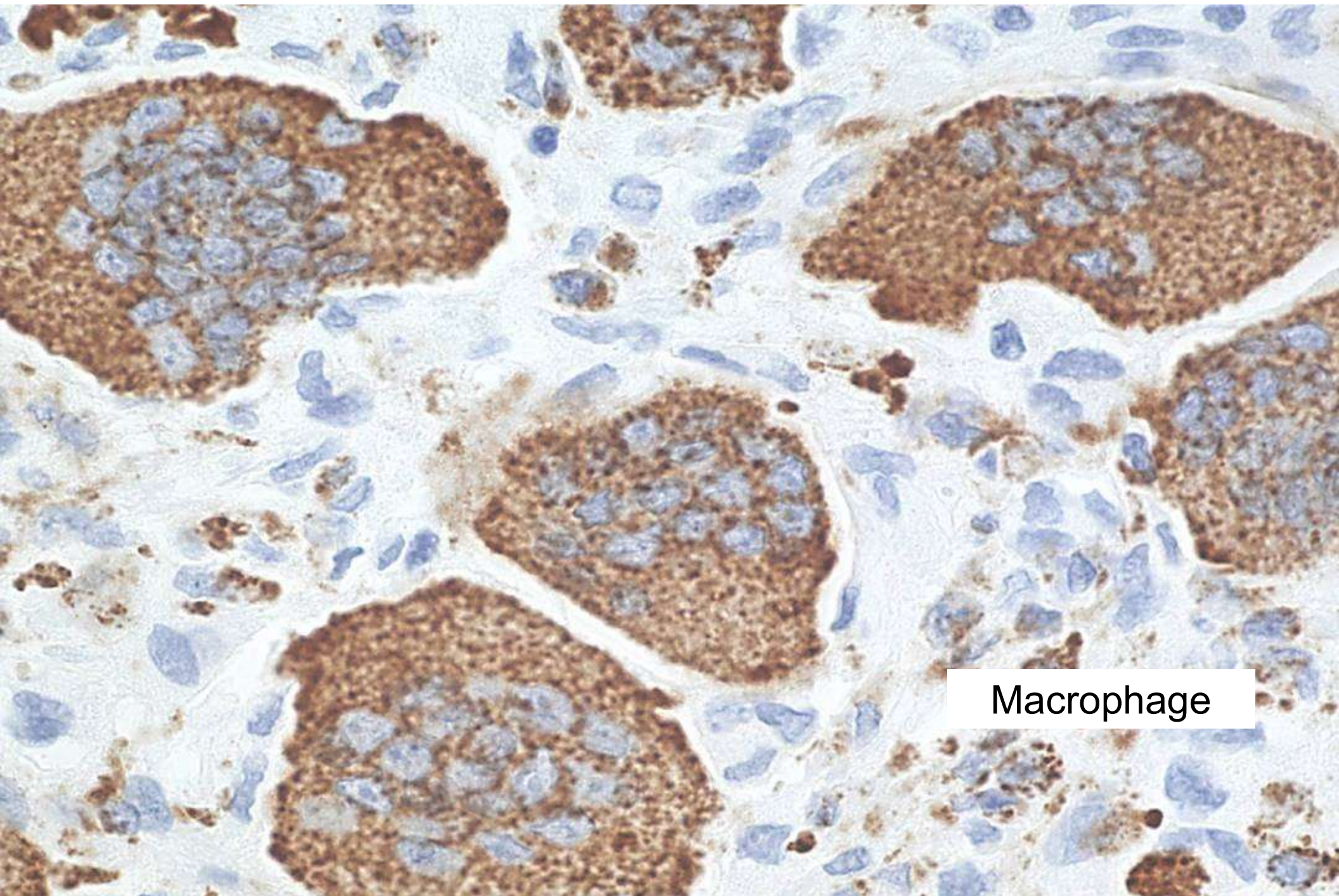
- Malignant epithelial neoplasm composed of large benign appearing multinucleated giant cells admixed with atypical neoplastic mononuclear cells
- The atypical mononuclear cells variably express markers of epithelial differentiation
- The osteoclast-like giant cells express markers of histiocytic differentiation
- Molecular analyses suggest that the osteoclast-like giant cells are reactive
- Highly aggressive neoplasms with a mean survival of only 12 months



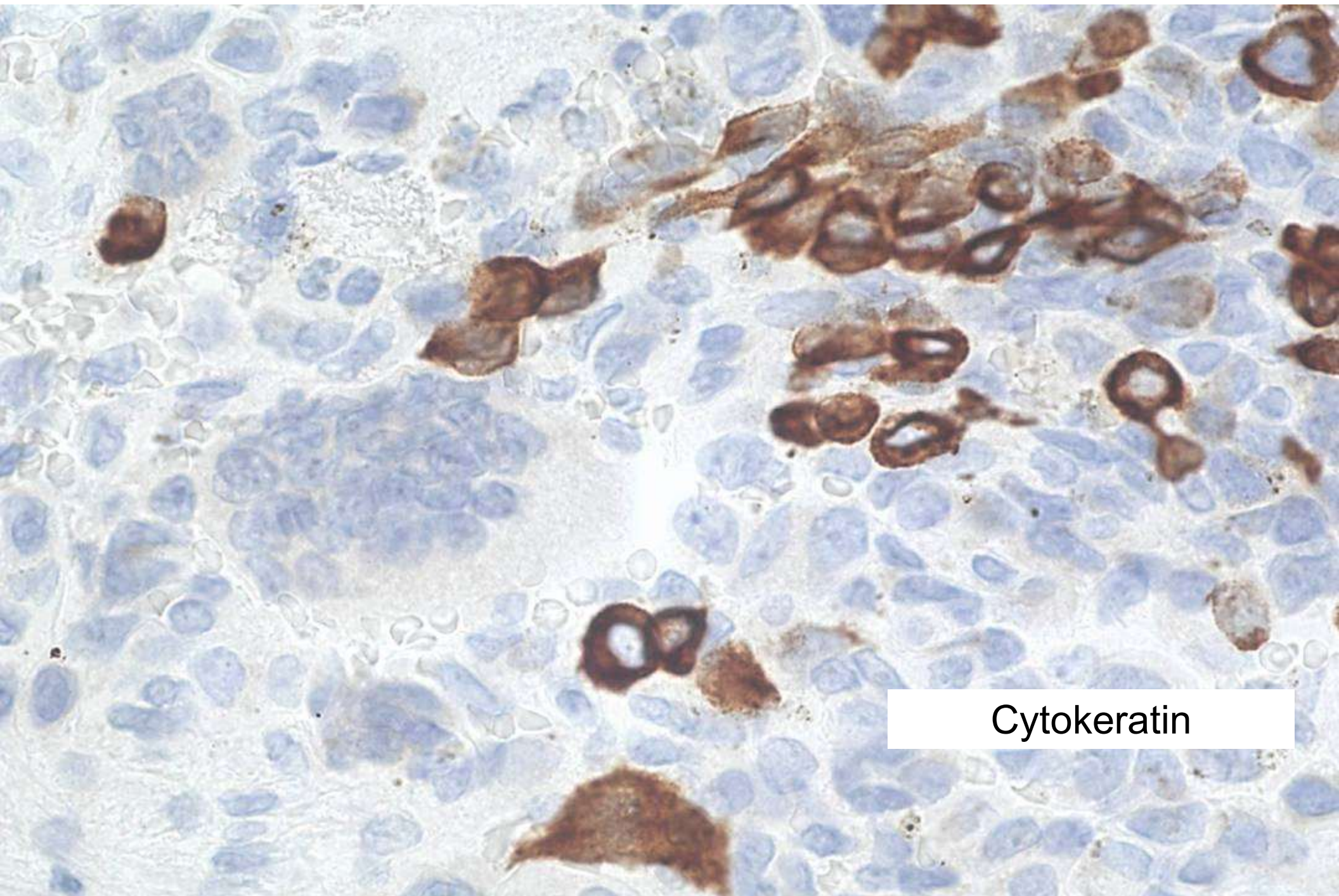




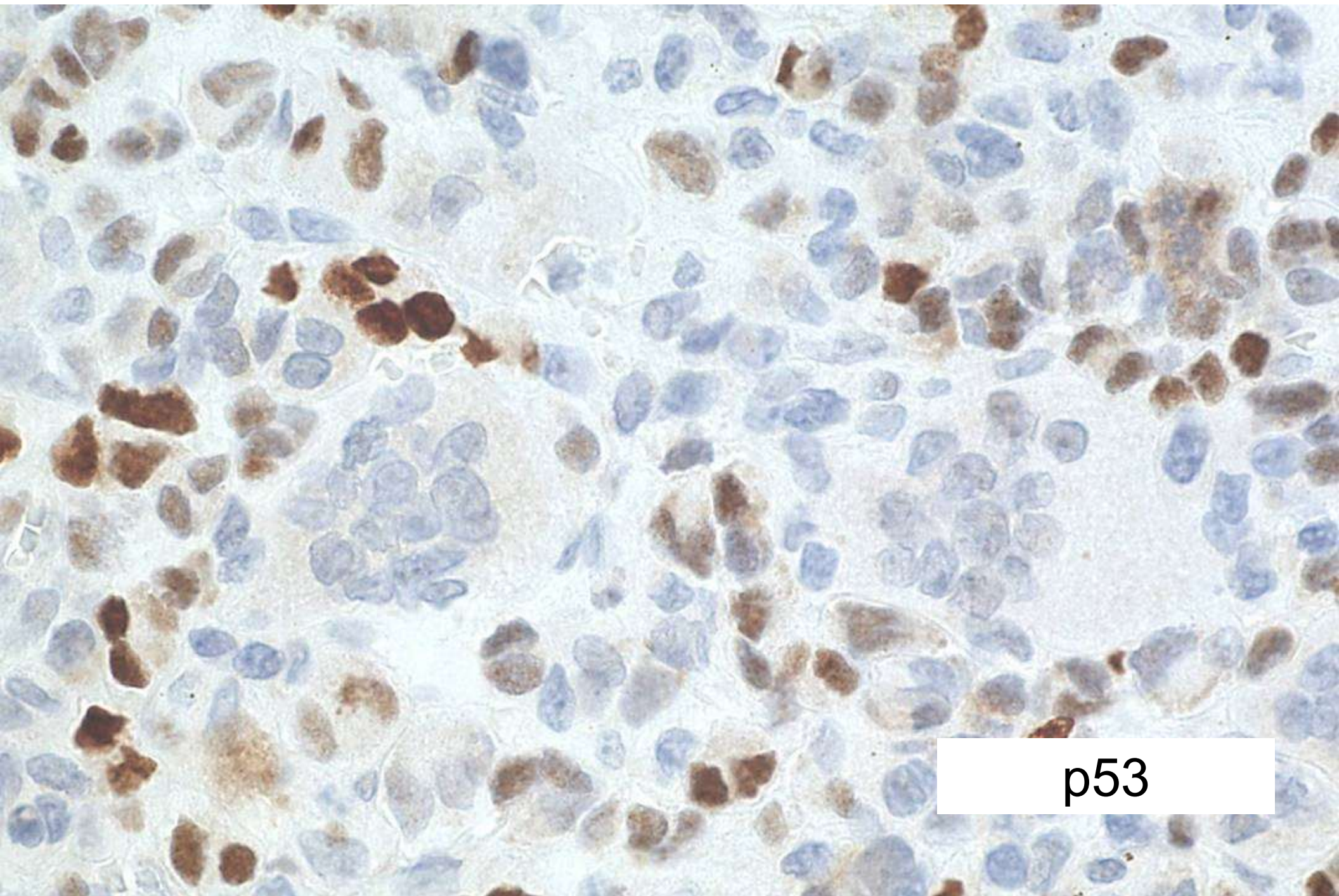




Macrophage



Cytokeratin



p53

JO. BAPTISTÆ
MORGAGNI

P. P. P. P.

DE SEDIBUS, ET CAUSIS
MORBORUM
PER ANATOMEN INDAGATIS

LIBRI QVINQUE.

*DISSECTIONS, ET ANIMADVERSIONES, NUNC PRIMUM EDITAS,
COMPLECTUNTUR PROPEMODUM INNUMERAS, MEDICIS,
CHIRURGIS, ANATOMICIS PROFUTURAS.*

Multiplex præfixus est Index rerum, & nominum
accuratissimus.

TOMUS PRIMUS

DUOS PRIORES CONTINENS LIBROS.
EDITIO SECUNDA

Ab Auctore recognita, atque a mendis omnibus expurgata.



PATAVII,

MDCCLXV.

*SUMPTIBUS REMONDINIANÆ,
SUPERIORUM PERMISSU, AC PRIVILEGIO.*

Morgagni 1682-1771
UVA.com





Two Non-Neoplastic Lesions That Clinically Mimic Pancreatic Cancer

1. Autoimmune Pancreatitis
(Lymphoplasmacytic sclerosing pancreatitis)
2. Groove Pancreatitis
(paraduodenal wall cyst)

Autoimmune Pancreatitis

A distinctive form of pancreatitis characterized by:

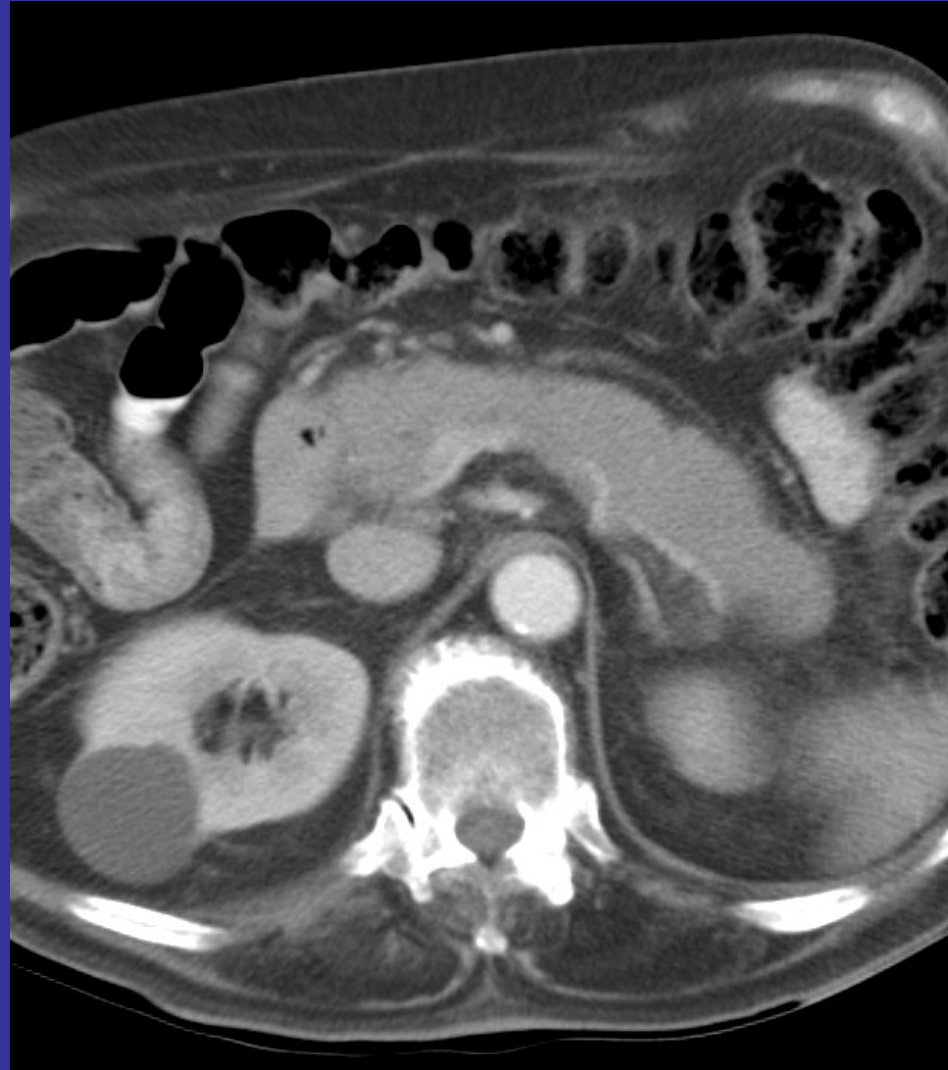1. Intense duct-centric inflammation
2. A mixed inflammatory cell infiltrate
3. Storiform fibrosis
4. Venulitis
5. Increased numbers of IgG4 expressing plasma cells

Autoimmune Pancreatitis

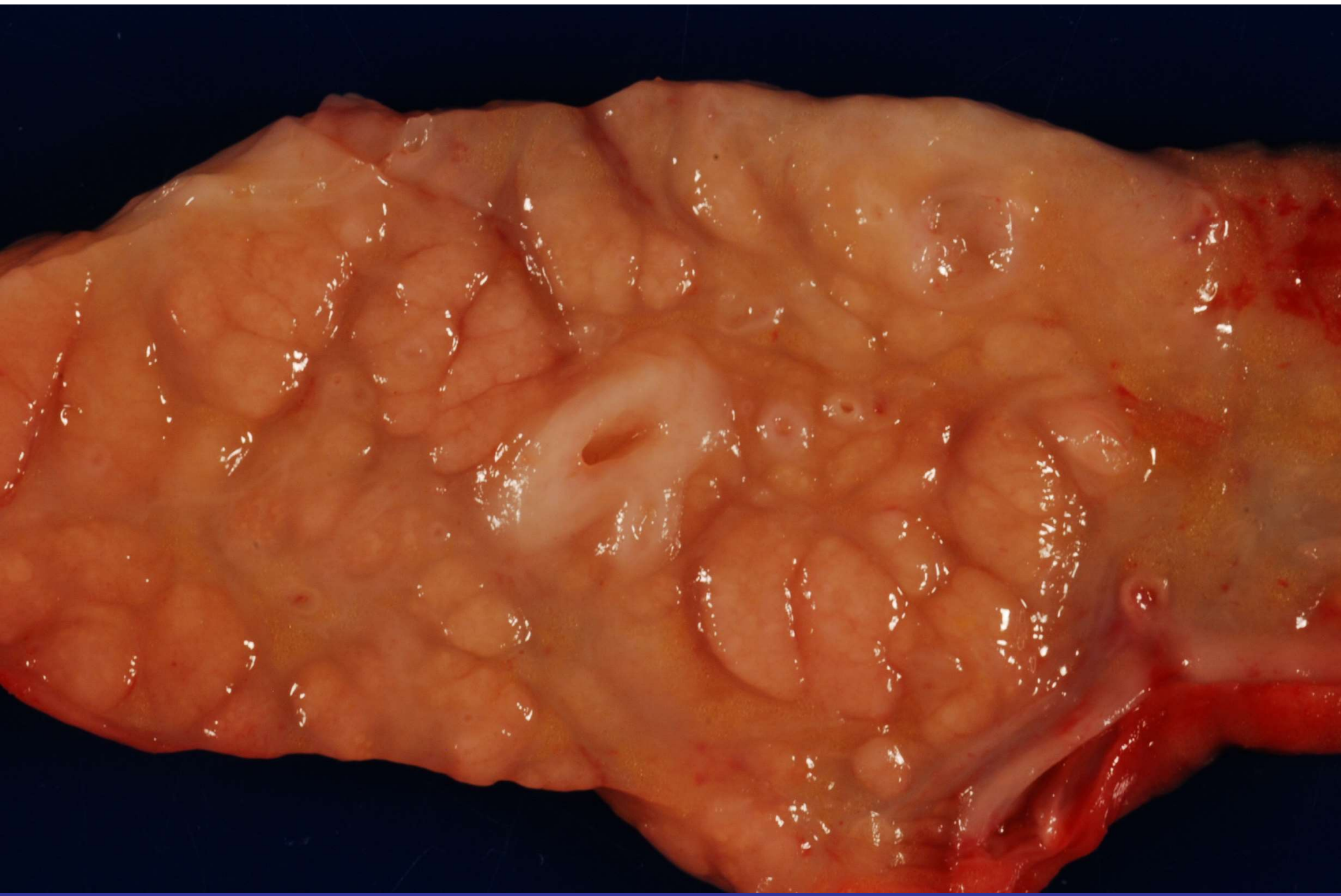
- Male>Female with a 8:3 gender ratio
- Mean age at diagnosis~ 60 years
- Patients typically don't have conventional risk factors for pancreatitis- alcohol abuse
- Jaundice may suggest cancer
- Radiographically diffuse enlargement of the gland (“sausage” appearance)
- Elevated serum IgG4 (not specific)
- Other autoimmune diseases- Sjögrens, IBD

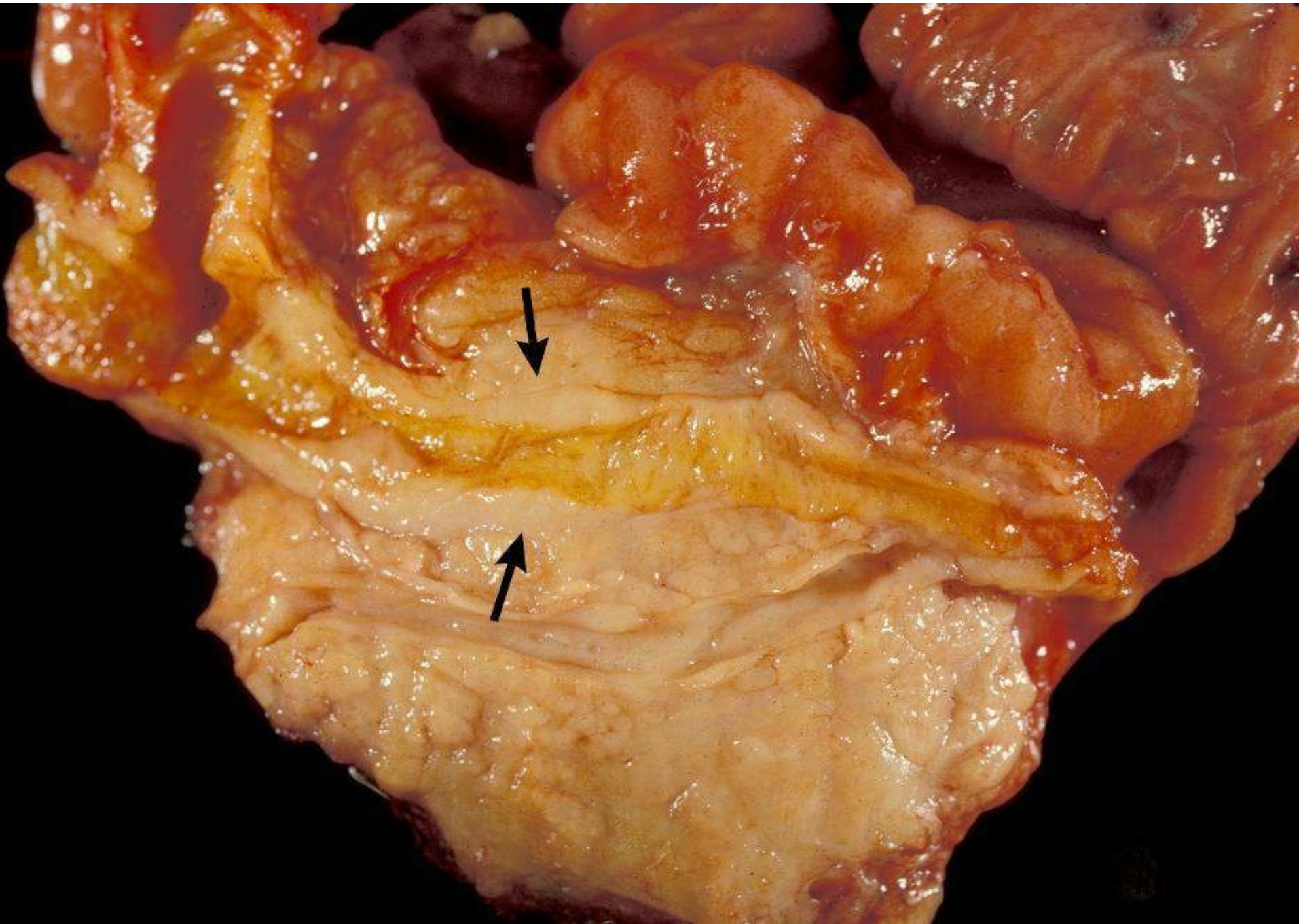
**Lymphoplasmacytic
Sclerosing
Pancreatitis/
Autoimmune
Pancreatitis**

Autoimmune Pancreatitis

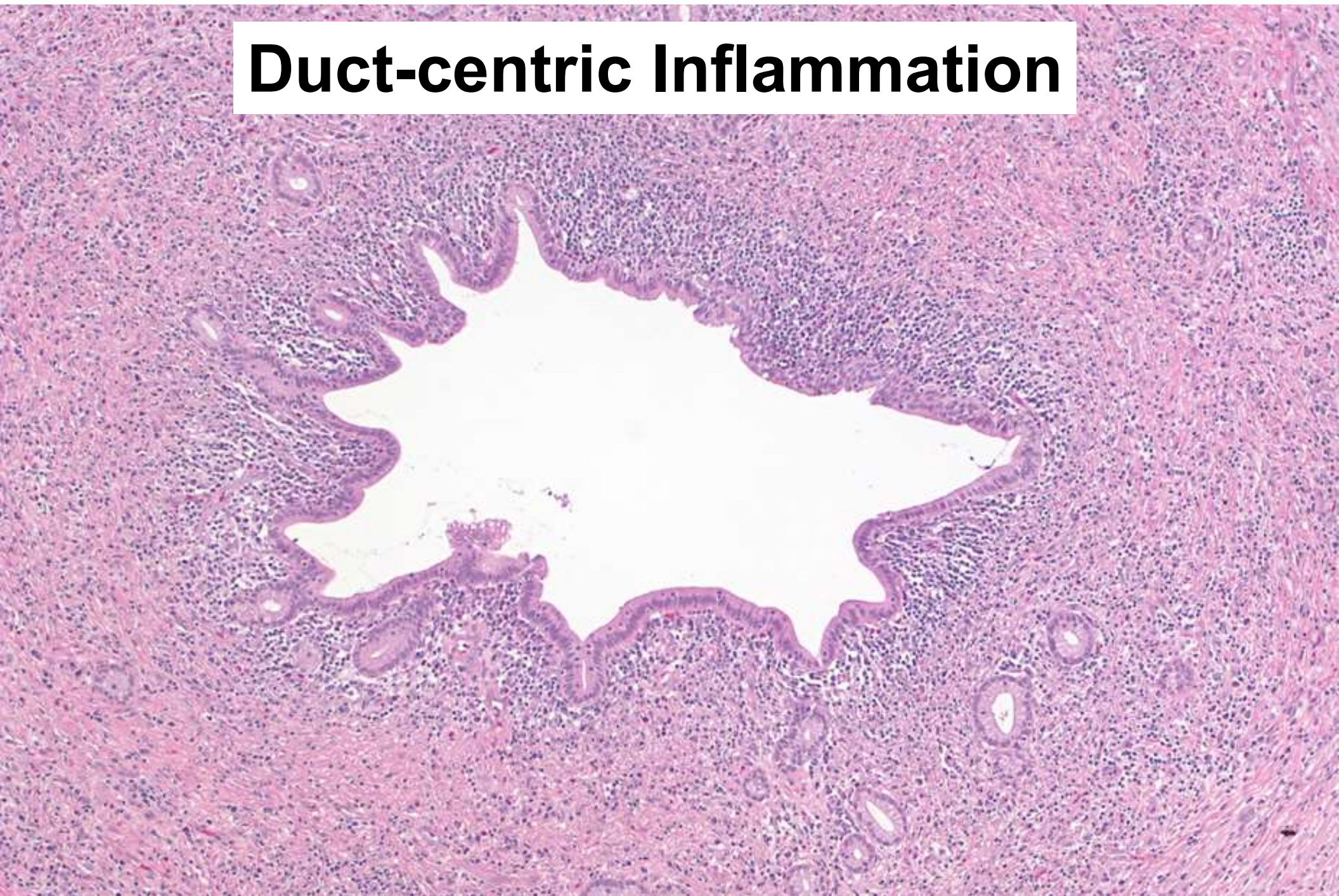


Kawamoto, S. et al. Am. J. Roentgenol. 2004;183:915-921

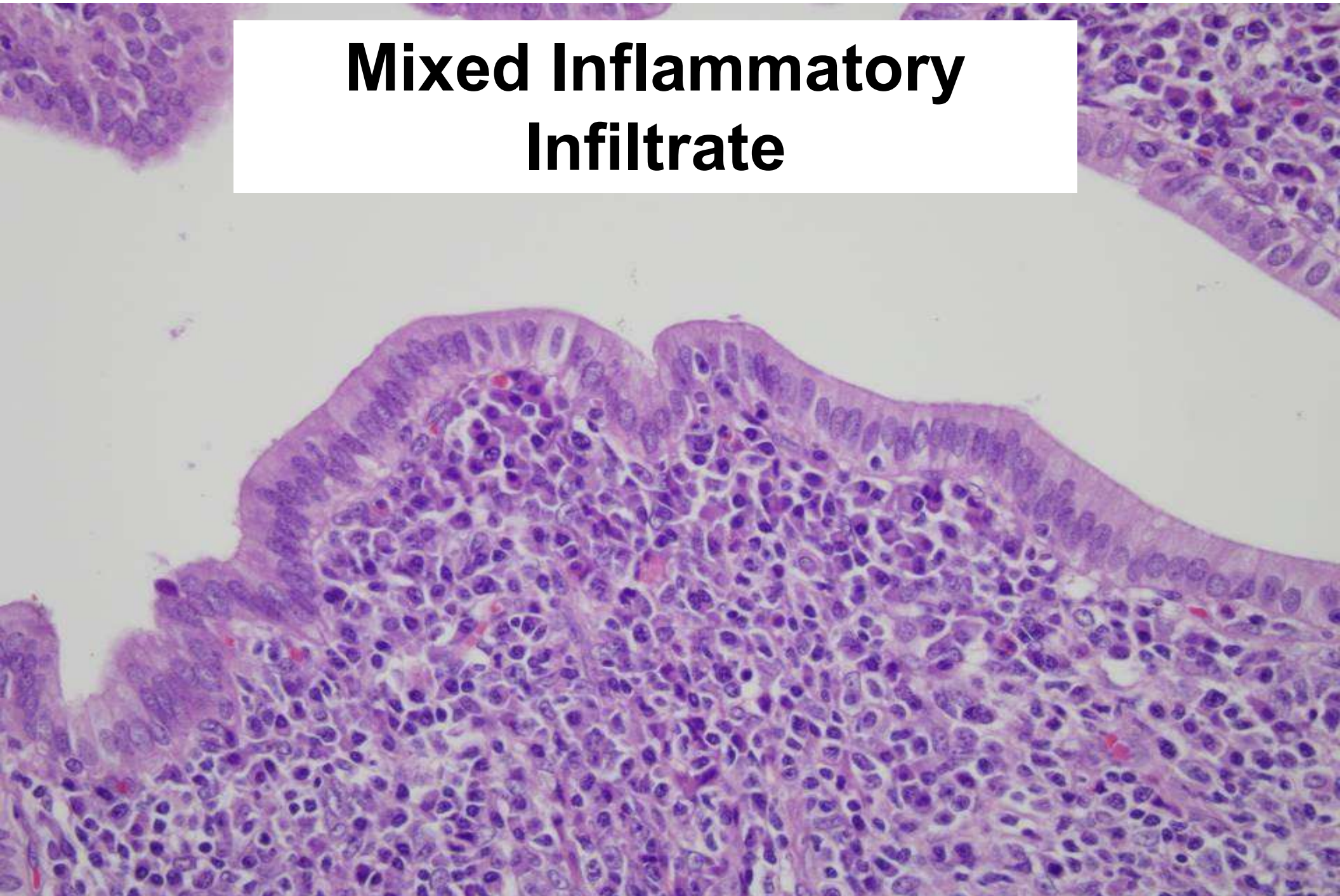




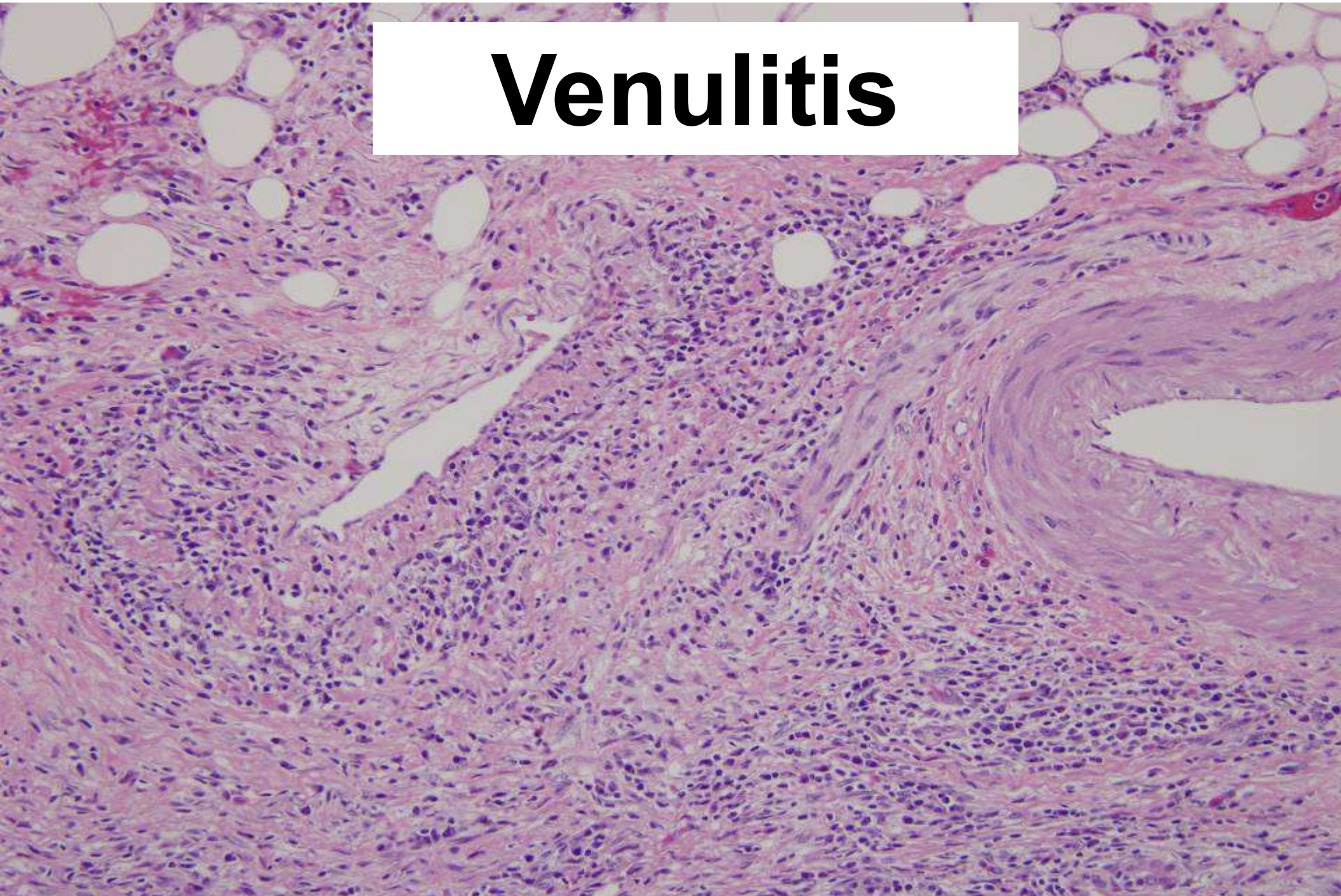
Duct-centric Inflammation



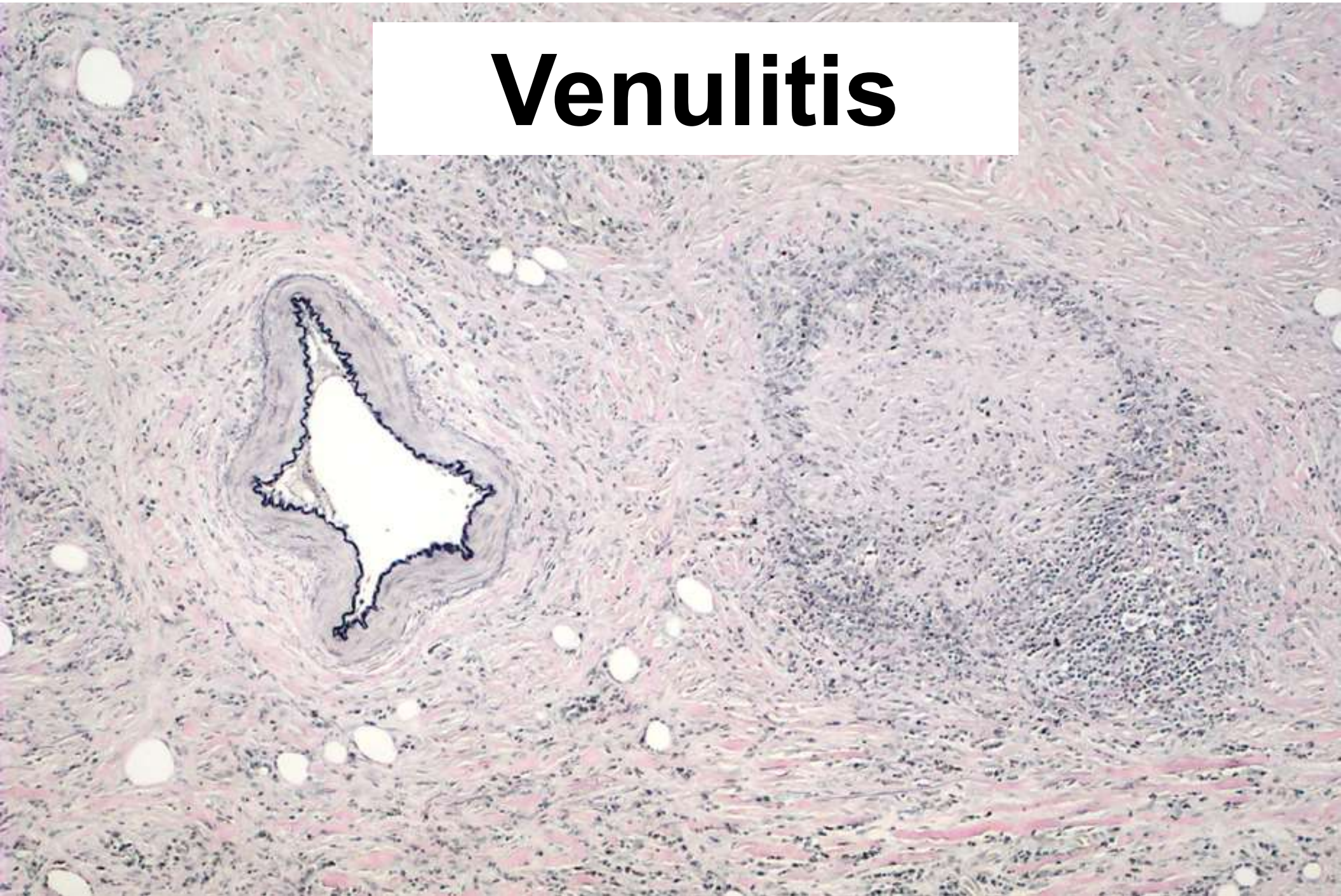
Mixed Inflammatory Infiltrate



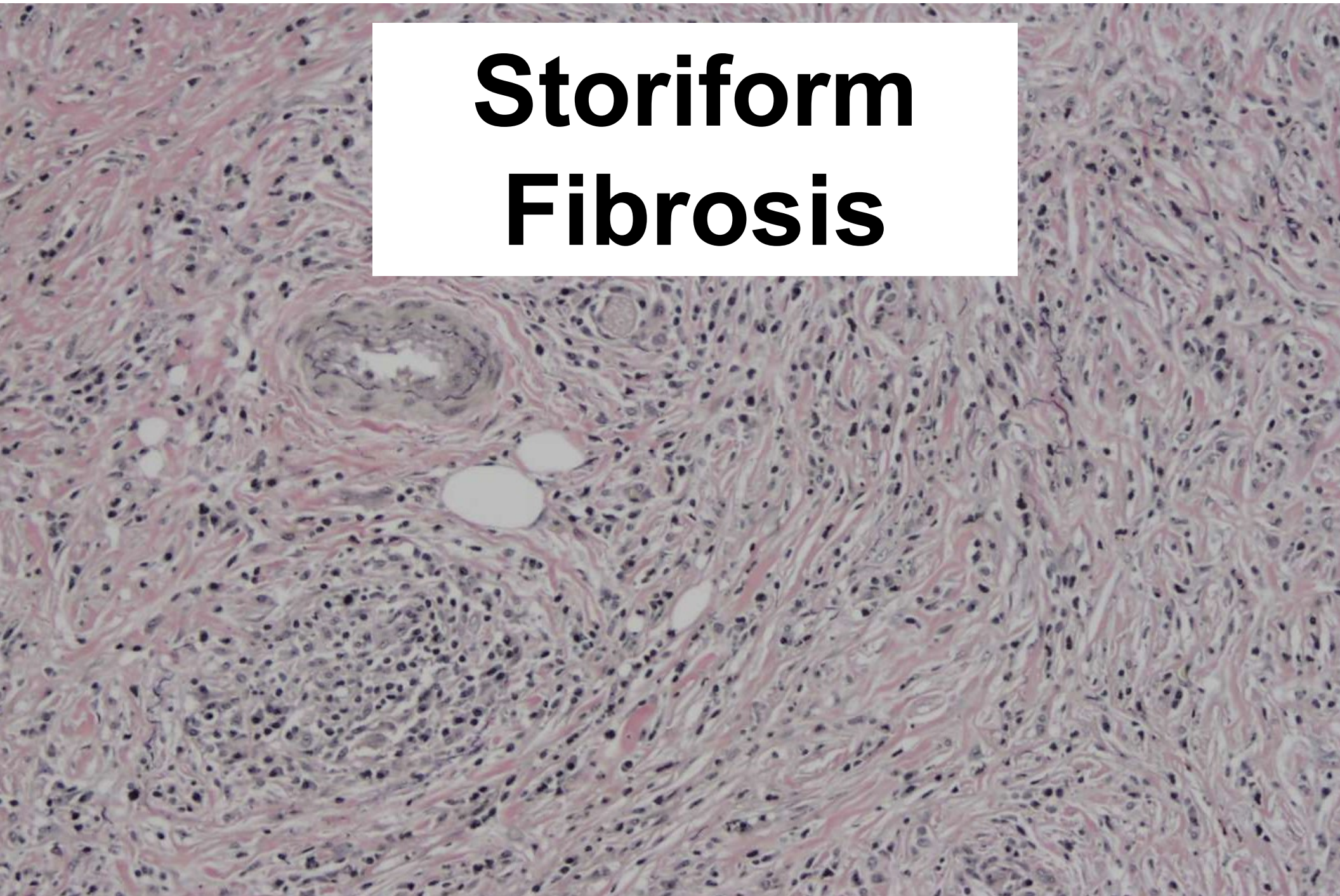
Venulitis



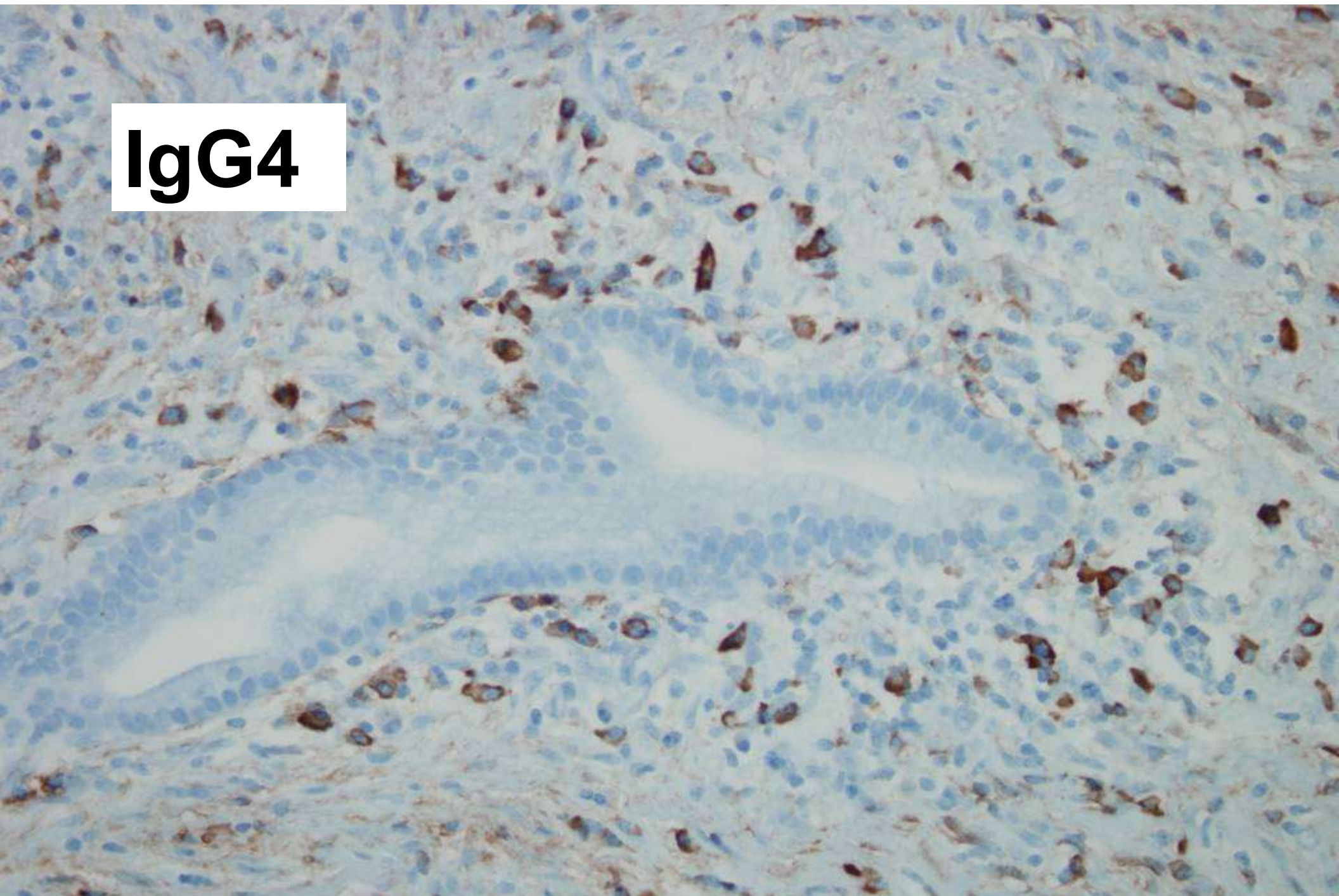
Venulitis



Storiform Fibrosis



IgG4



Autoimmune Pancreatitis

Responds to steroids!

Characteristic histological features
 1. Dense lymphoplasmacytic infiltrate
 2. Fibrosis, usually storiform in character
 3. Obliterative phlebitis

Cases with ≥ 2 pathology features

Cases with 1 pathology feature

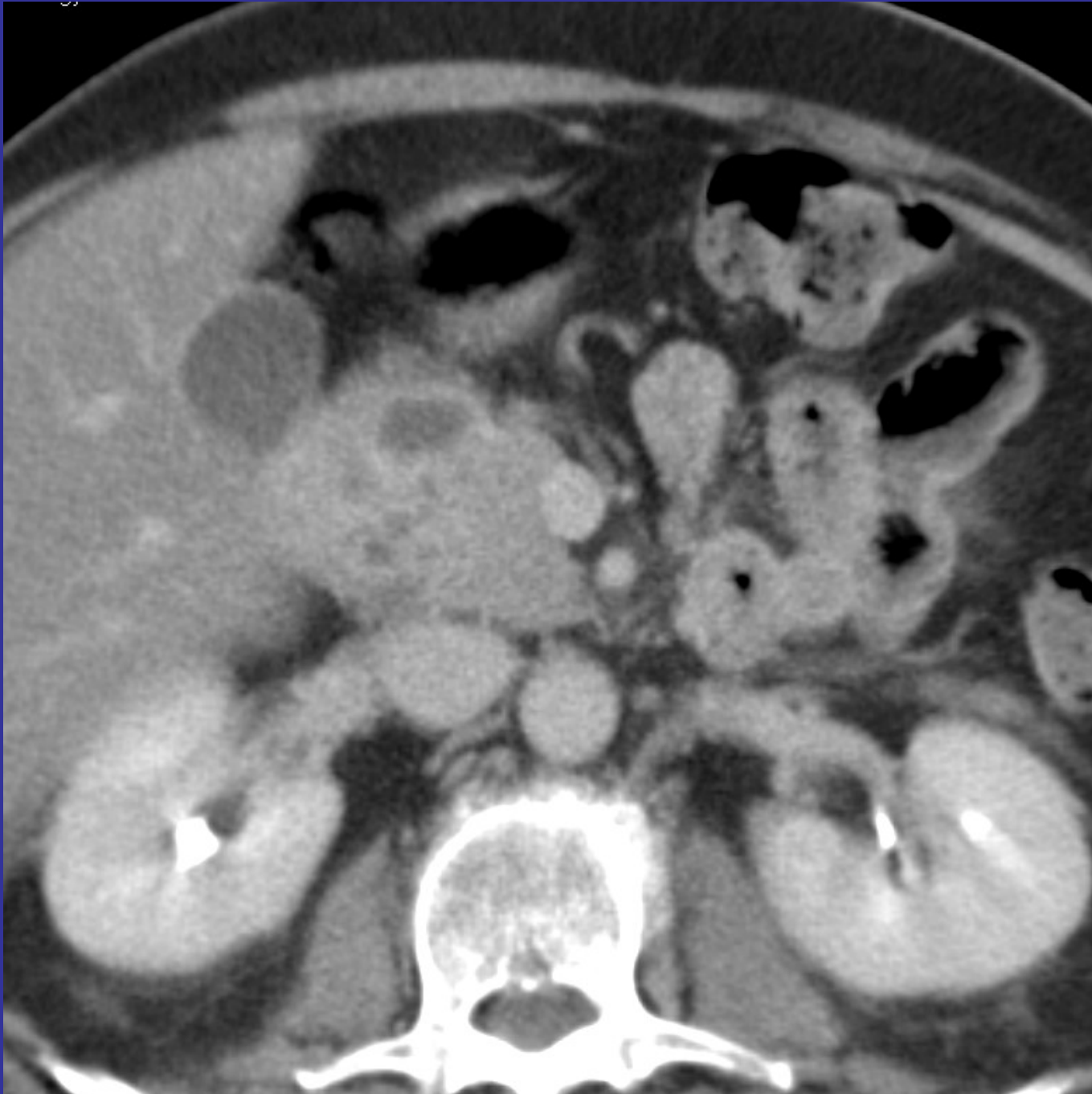	Numbers of IgG4+ plasma cells (/hpf)		Ref
Meningus	>10	>10	55
Lacrimal gland	>100	>100	28
Salivary gland	>100	>100	17,34
Lymph node	>100	>50	27
Lung (surgical specimen)	>50	>50	10,35
Lung (biopsy)	>20	>20	10,35
Pleura	>50	>50	6
Pancreas (surgical specimen)	>50	>50	30,32
Pancreas (biopsy)	>10	>10	56,57
Bile duct (surgical specimen)	>50	>50	49
Bile duct (biopsy)	>10	>10	58,59
Liver (surgical specimen)	>50	>50	49
Liver (biopsy)	>10	>10	12,60
Kidney (surgical specimen)	>30	>30	15
Kidney (biopsy)	>10	>10	61
Aorta	>50	>50	16,51,52
Retroperitoneum	>30	>30	8
Skin	>200	>200	62,63

IgG4+/IgG+ plasma cell ration >40% a mandatory for histological diagnosis of IgG4-RD

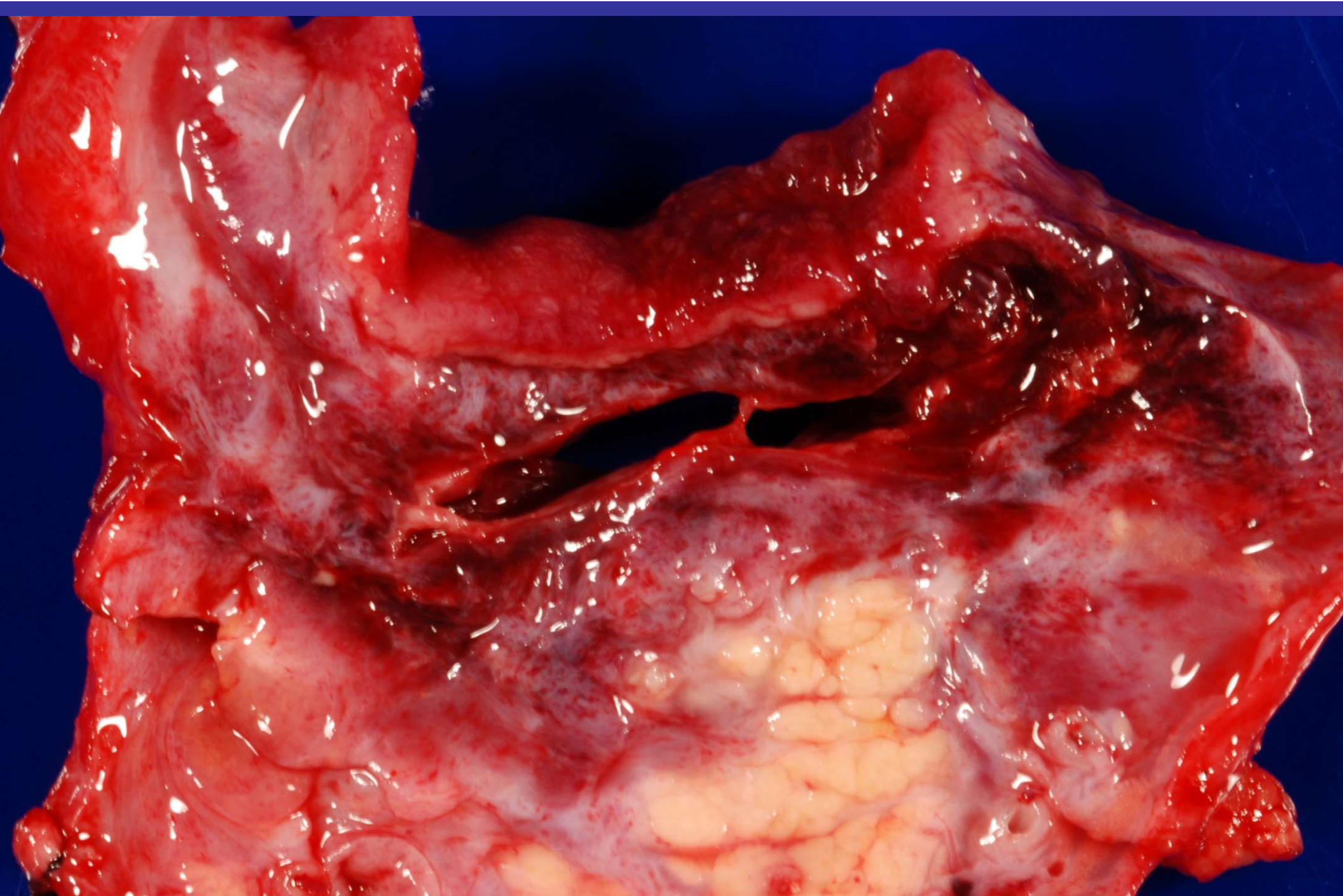
Green boxes = Histologically highly suggestive of IgG4-RD

Orange boxes = Probable histological features of IgG4-RD

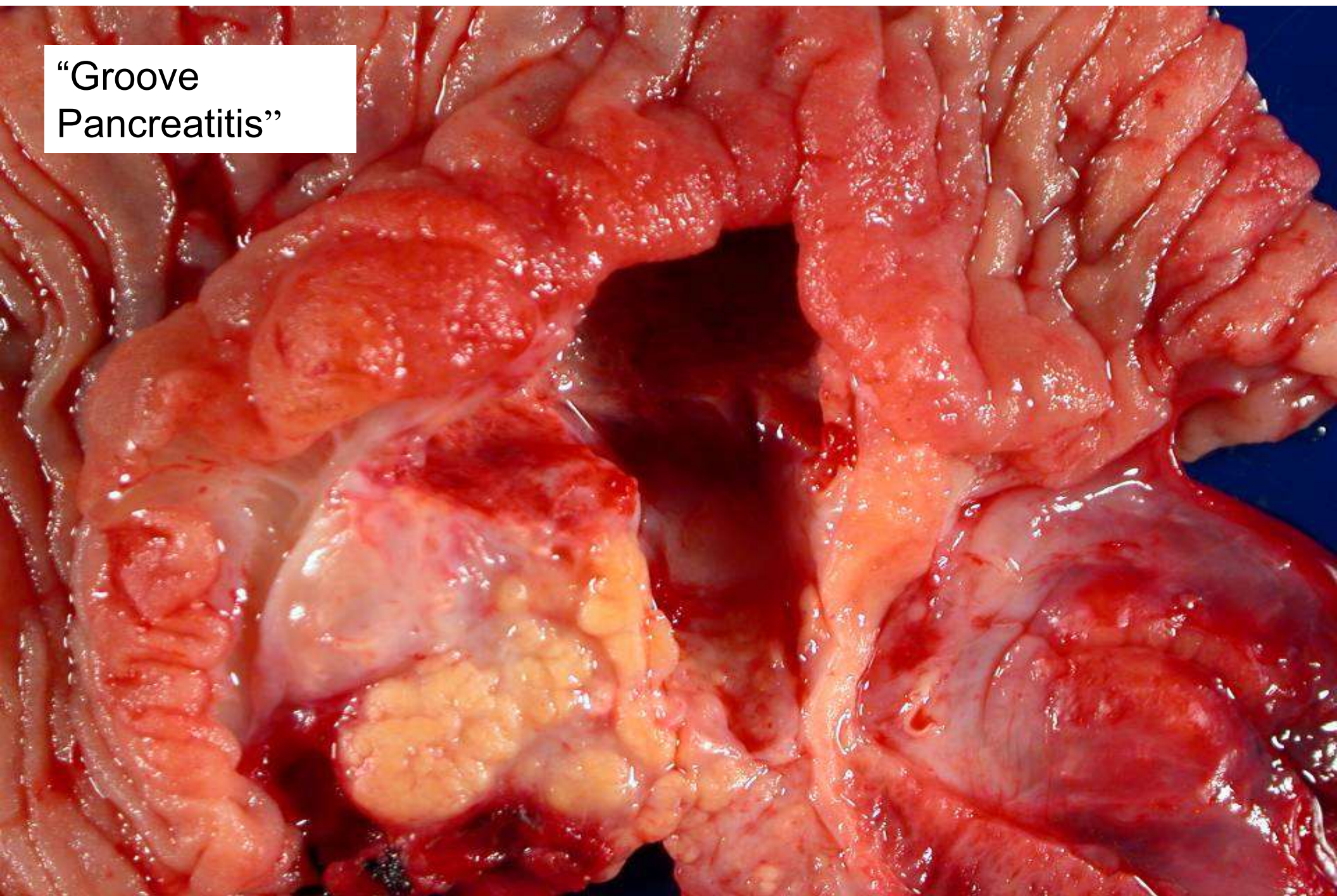
Groove Pancreatitis

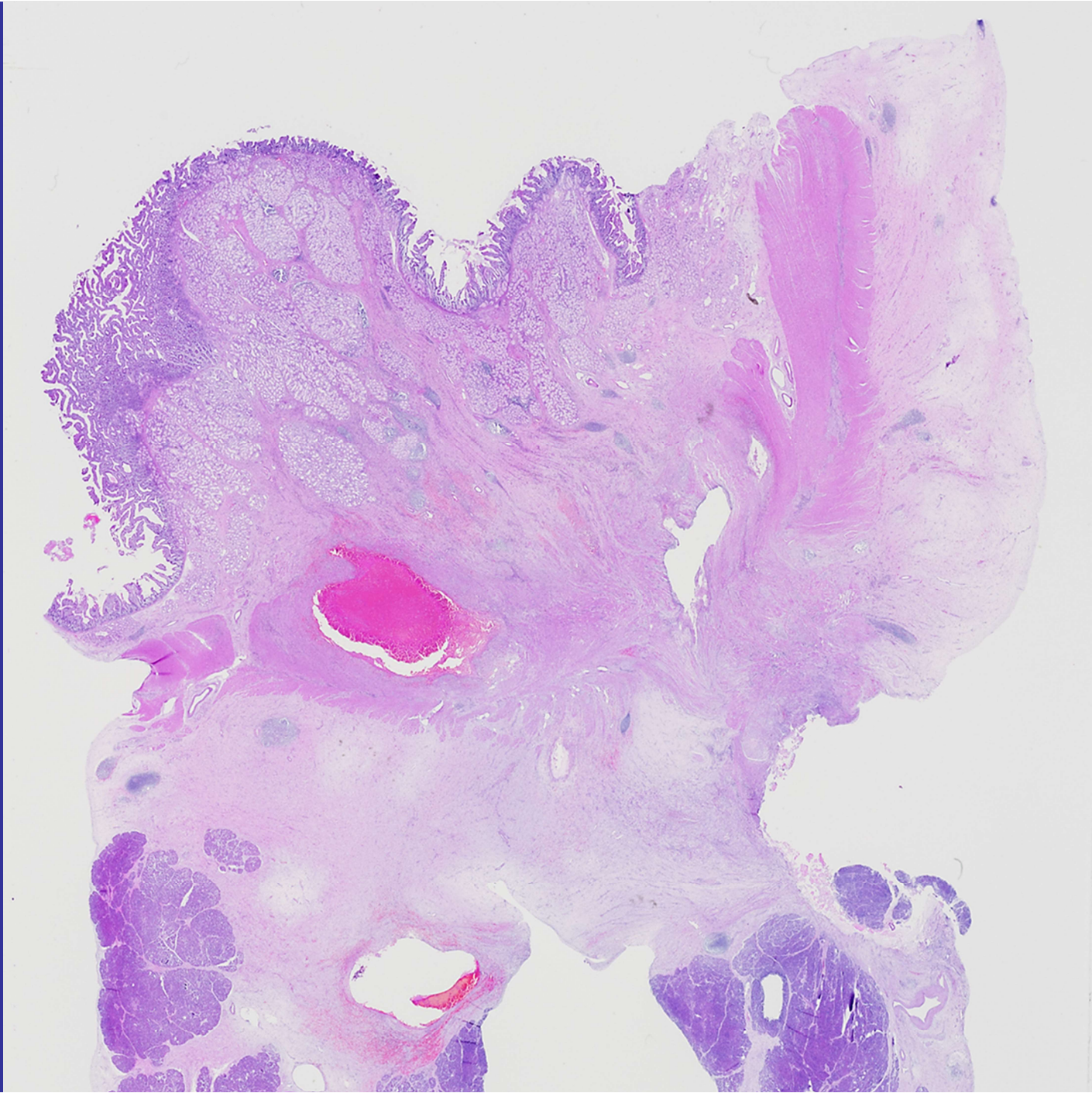


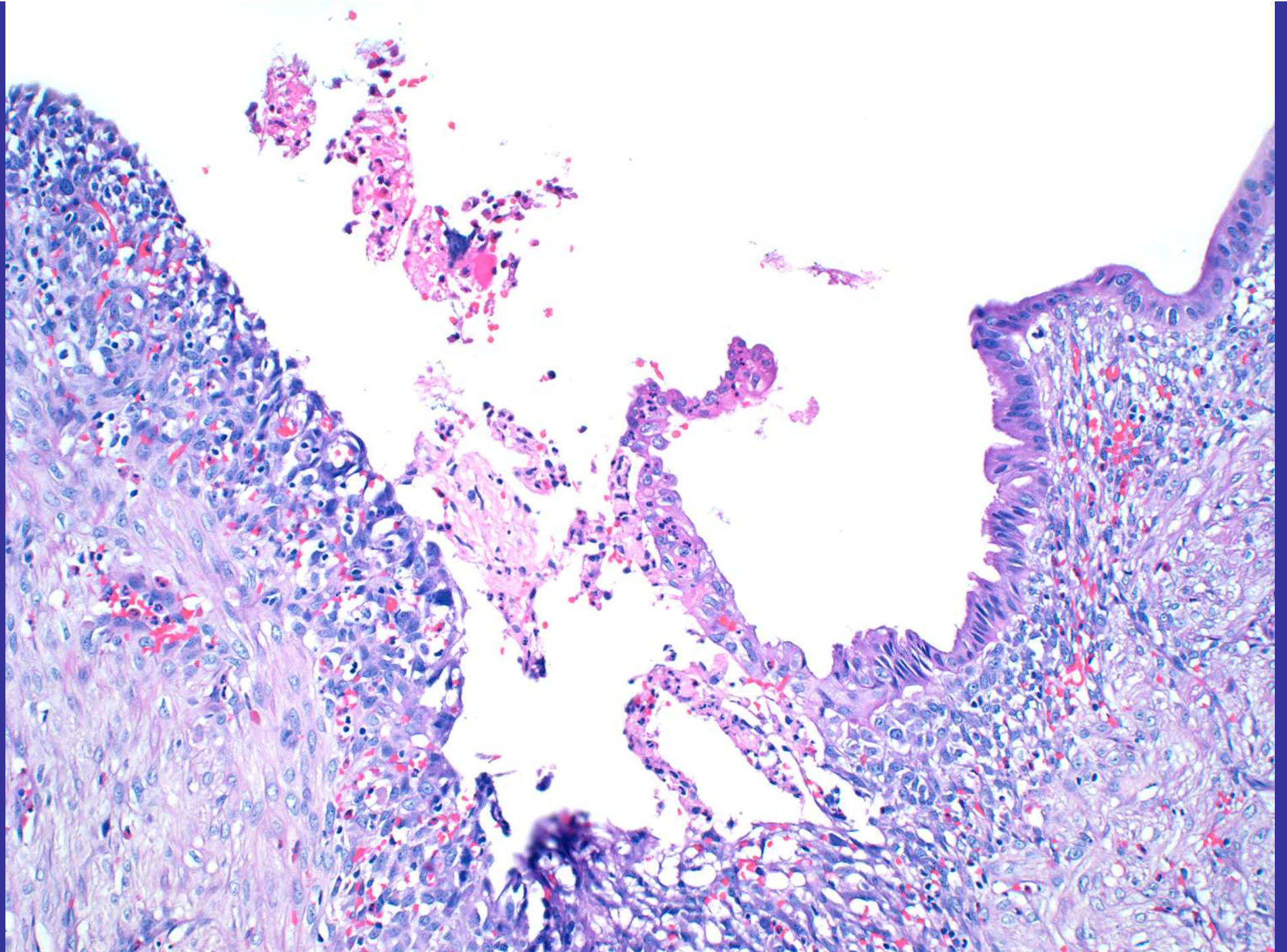
CTisUs

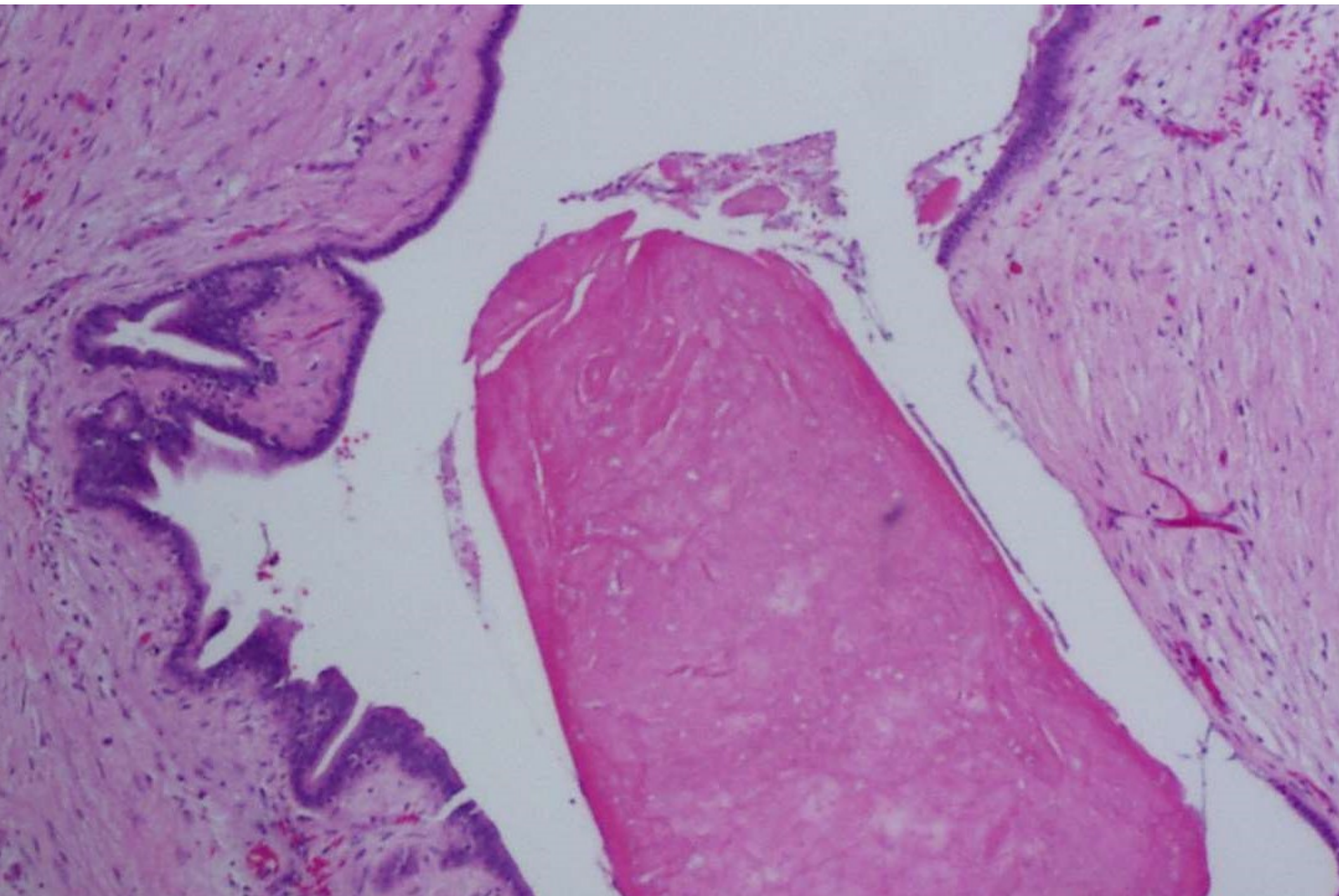


“Groove
Pancreatitis”

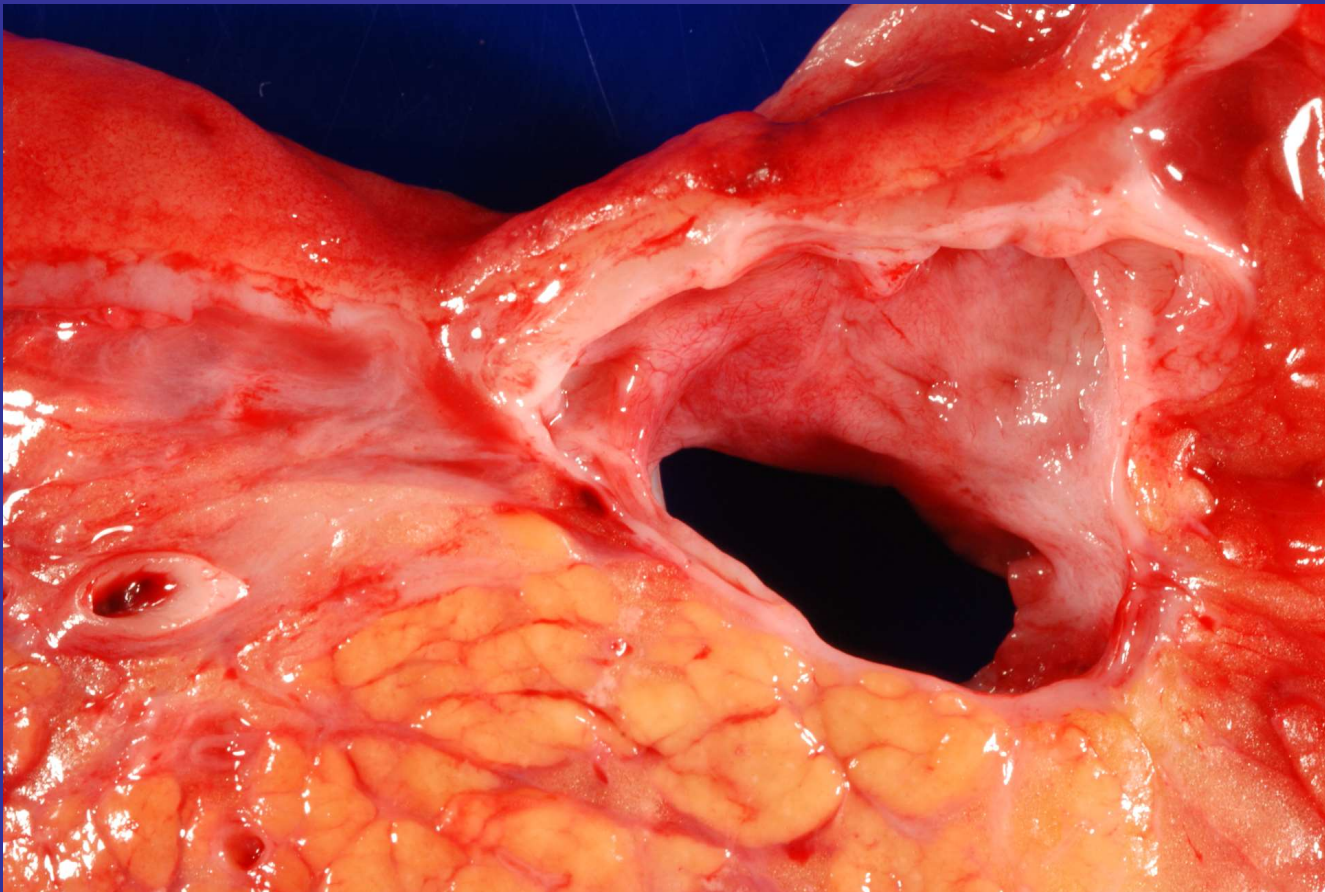








Look at the Groove Region!



Thank You!

@Hopkins_GI_Path