

An Algorithmic approach to cystic neoplasms of the pancreas



JOHNS HOPKINS
MEDICAL INSTITUTIONS

February 2017

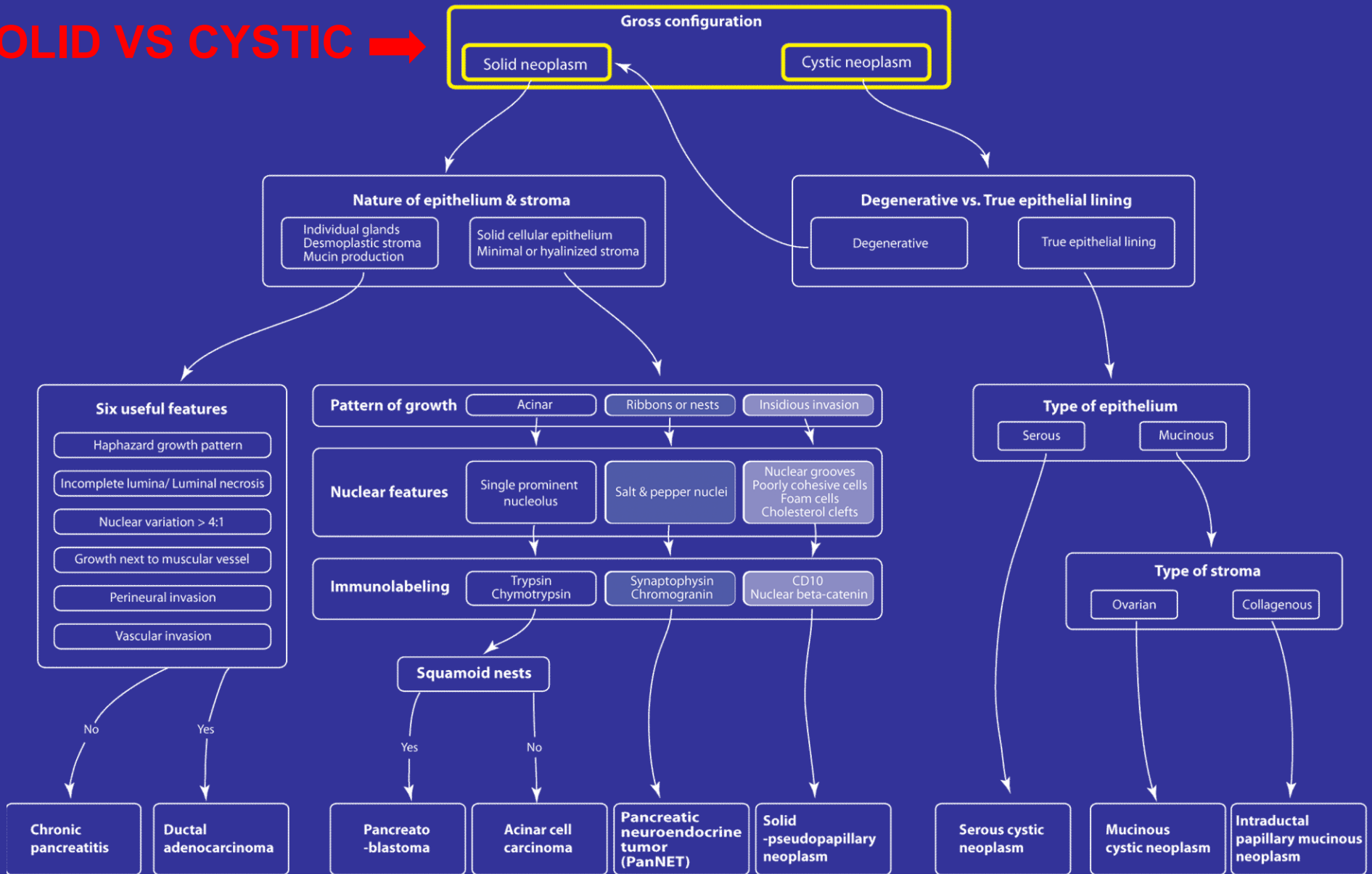
Ralph H. Hruban, M.D.

Professor and Director of Pathology
The Sol Goldman Pancreatic Cancer Research Center
The Johns Hopkins Medical Institutions

Disclosure

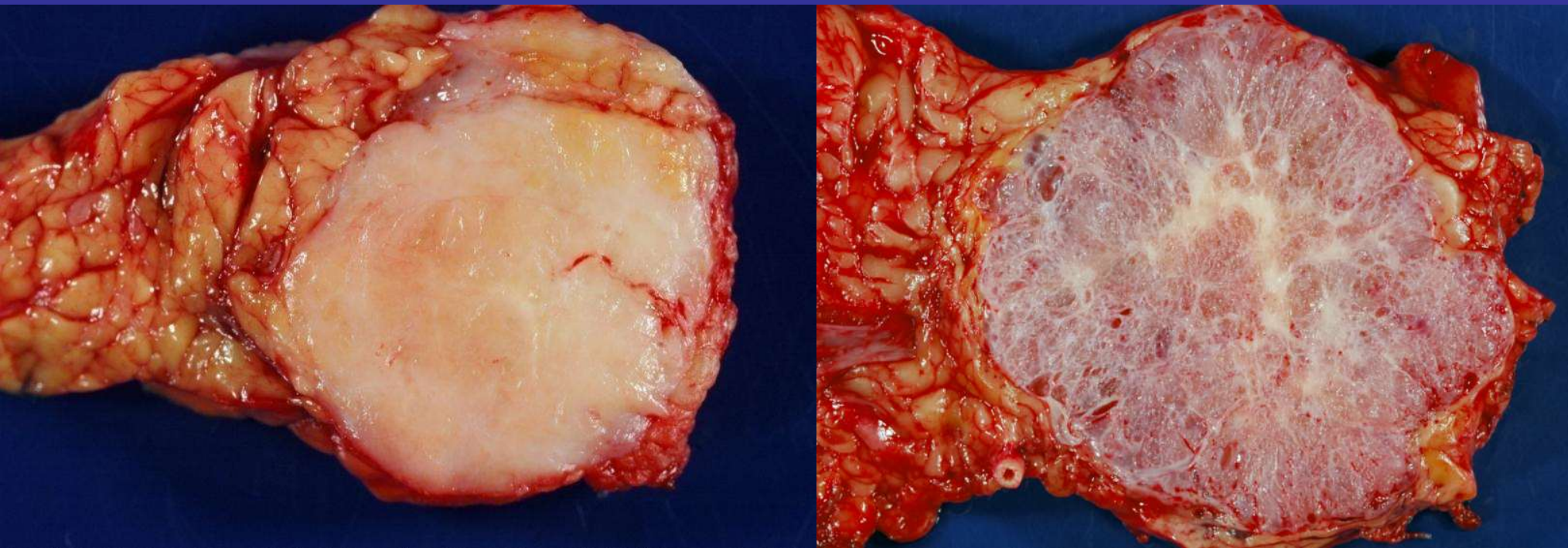
- I receive royalty payments from Myriad Genetics for the PALB2 invention.
- Selected images from the AFIP Fascicle with permission
- The pancreas pathology iPad APPs are free through the iTunes Store

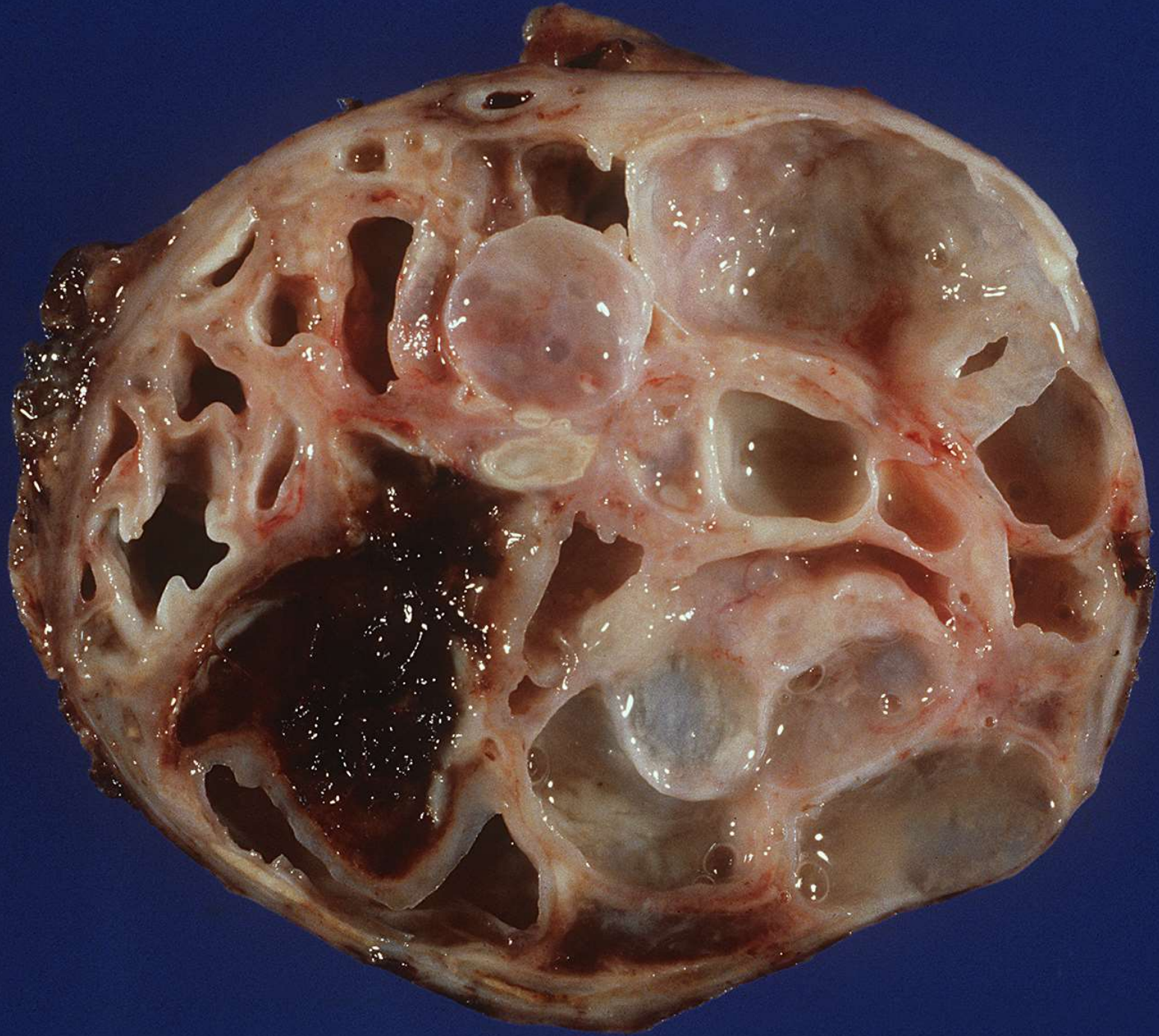SOLID VS CYSTIC →



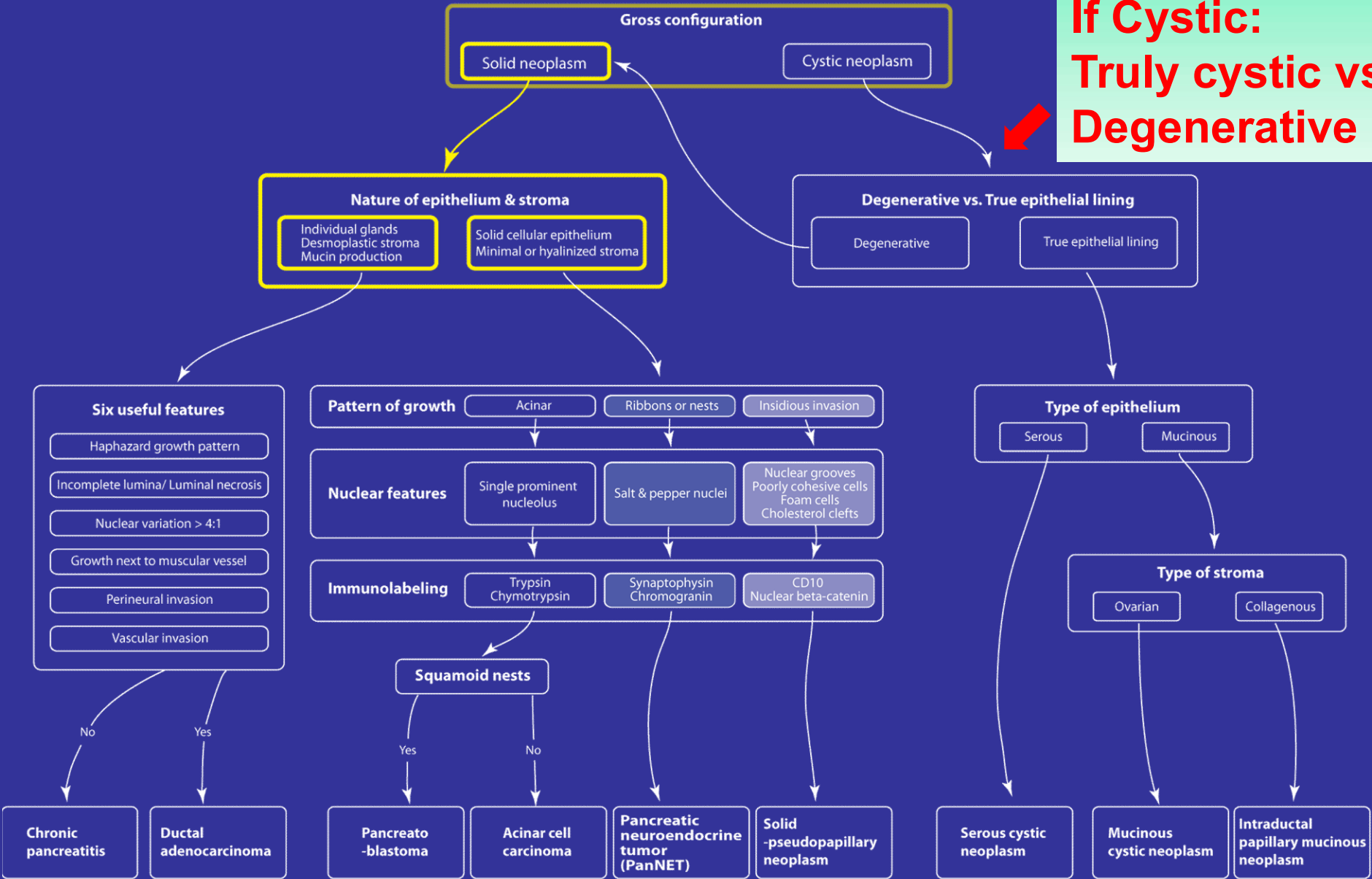
Based on AFIP Fascicle, 4th Edition

1. Is it Solid or Cystic?

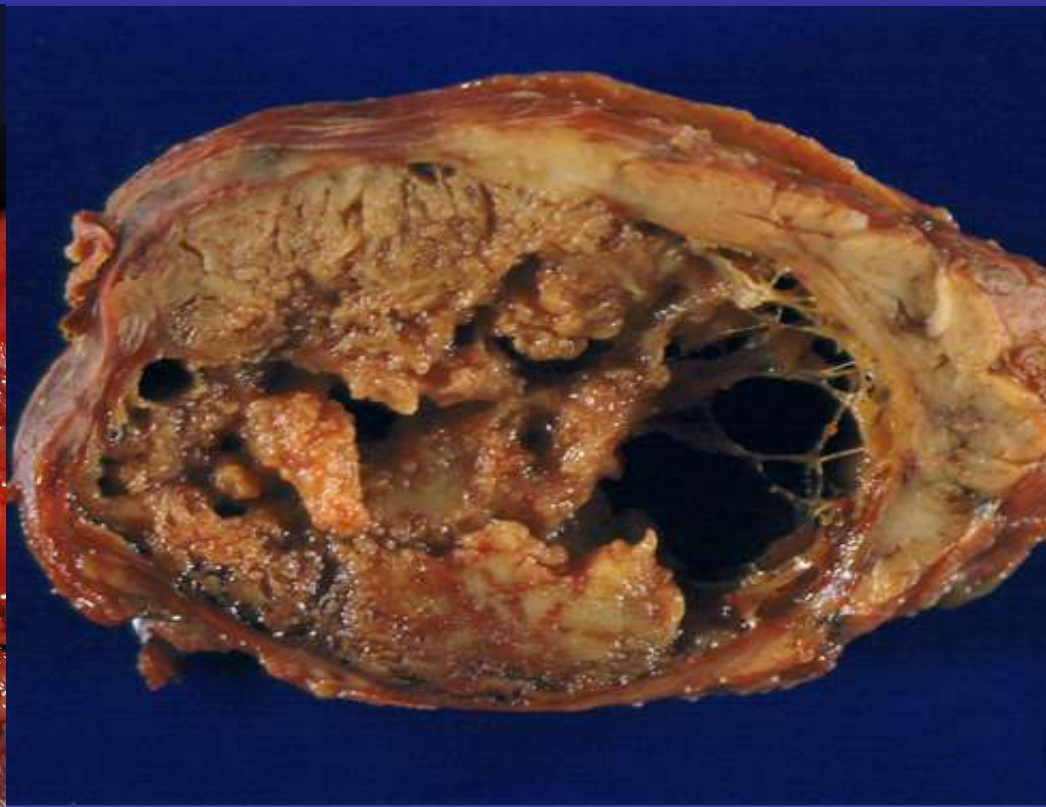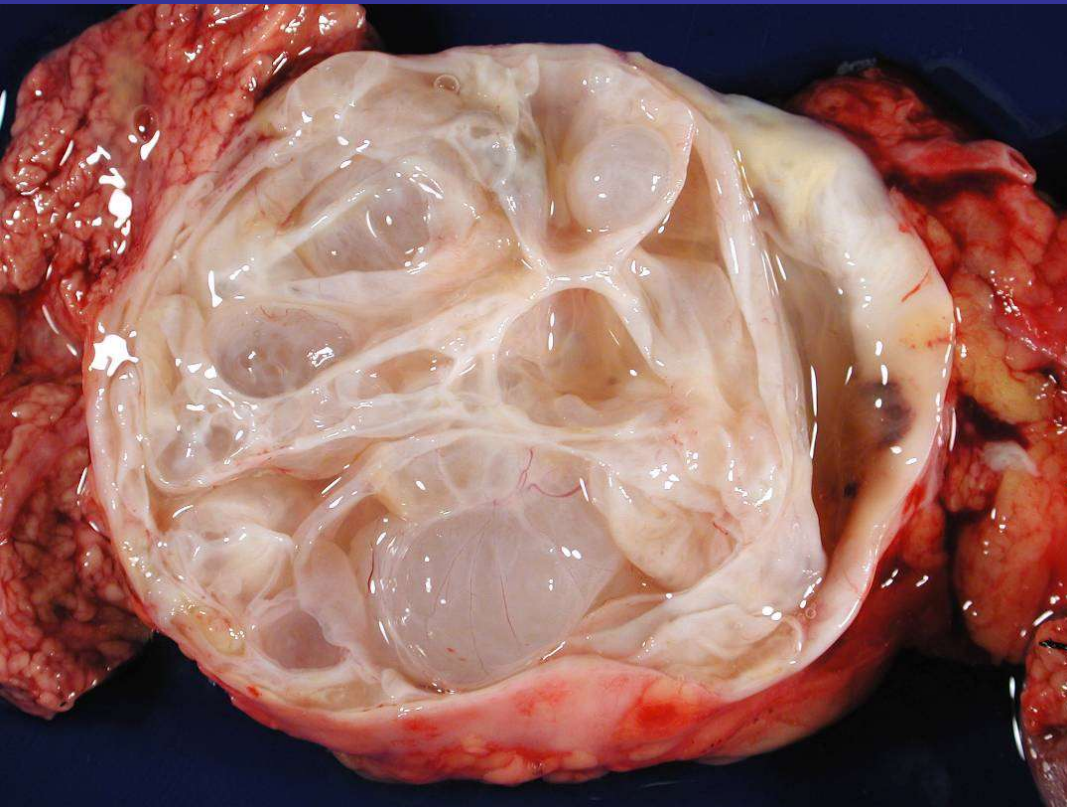




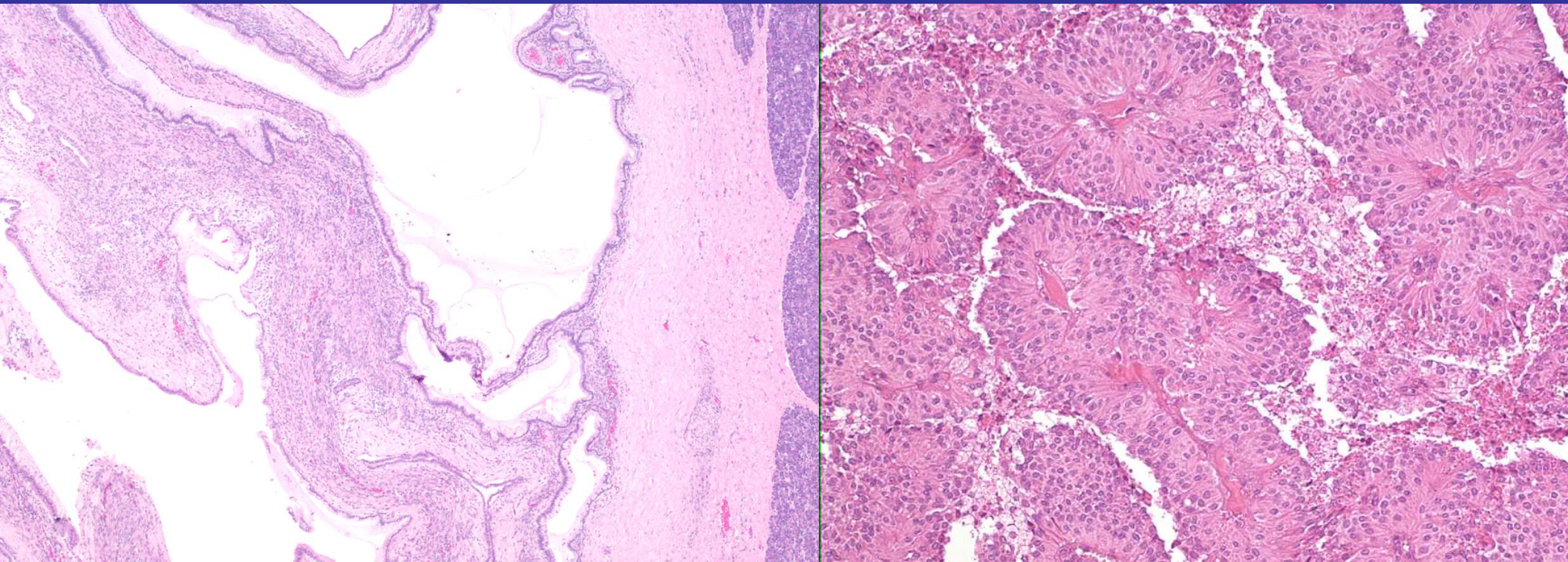
**If Cystic:
Truly cystic vs.
Degenerative**

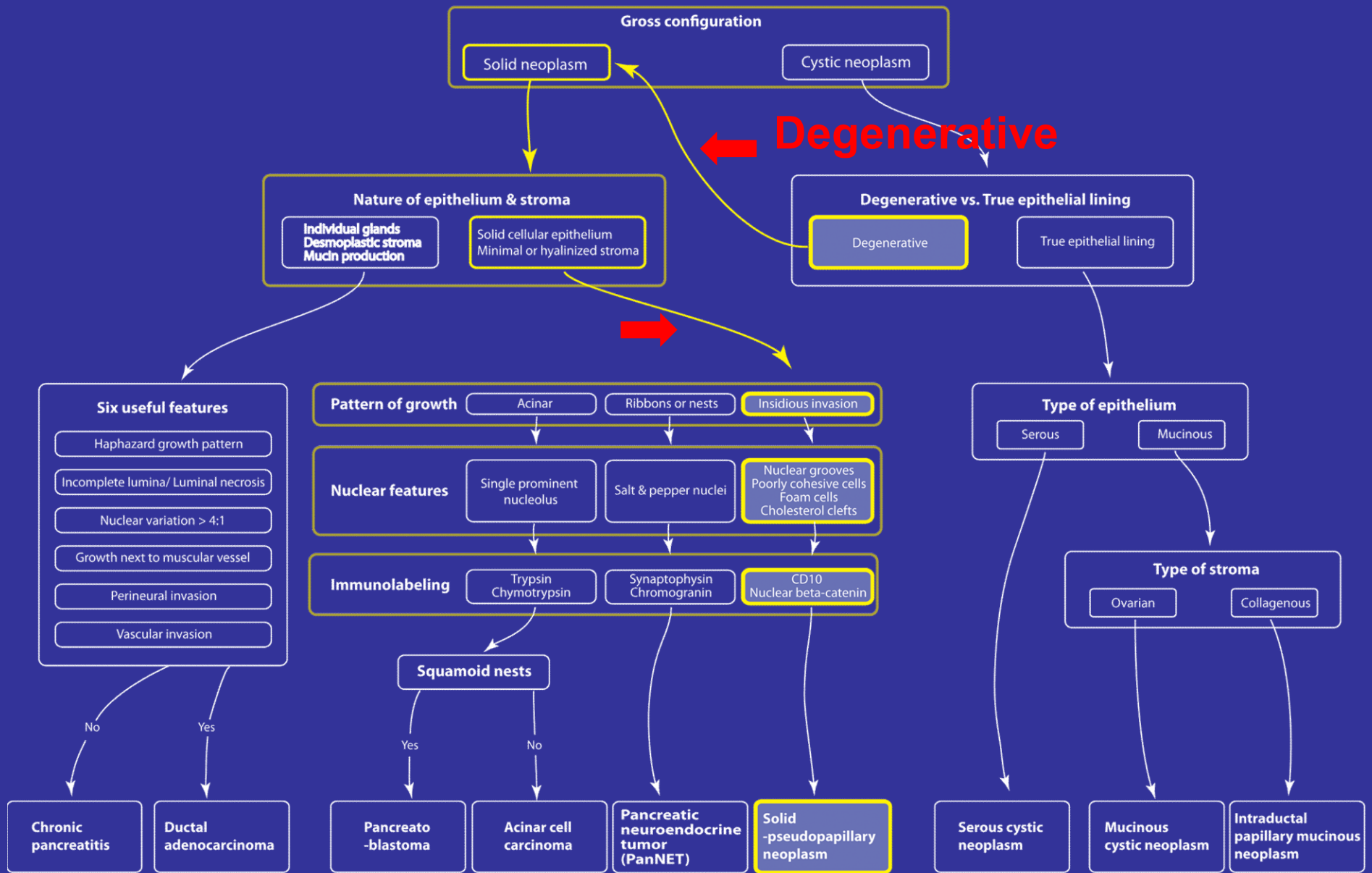


Epithelial Lined vs. Degenerative

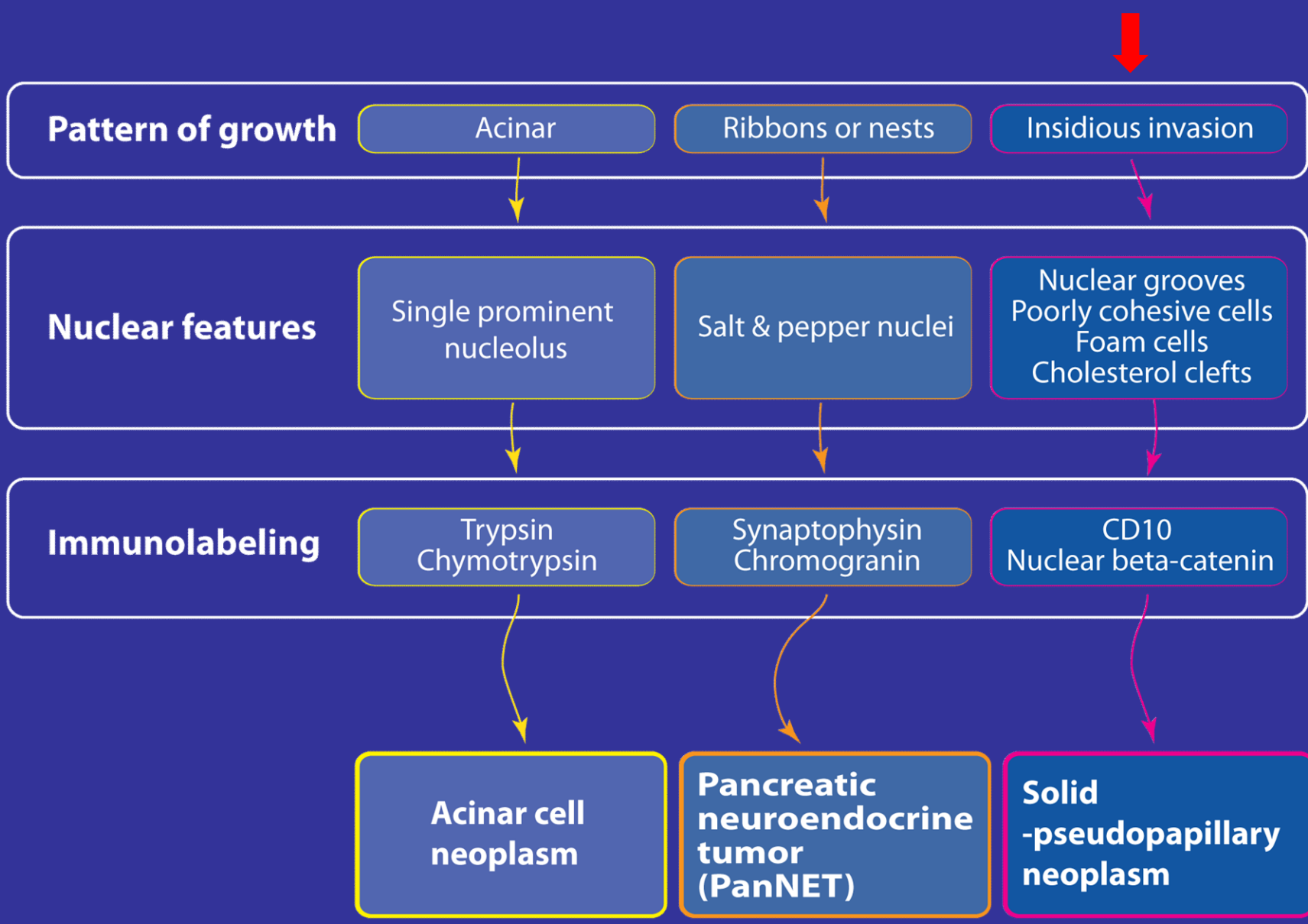


Epithelial Lined vs. Degenerative

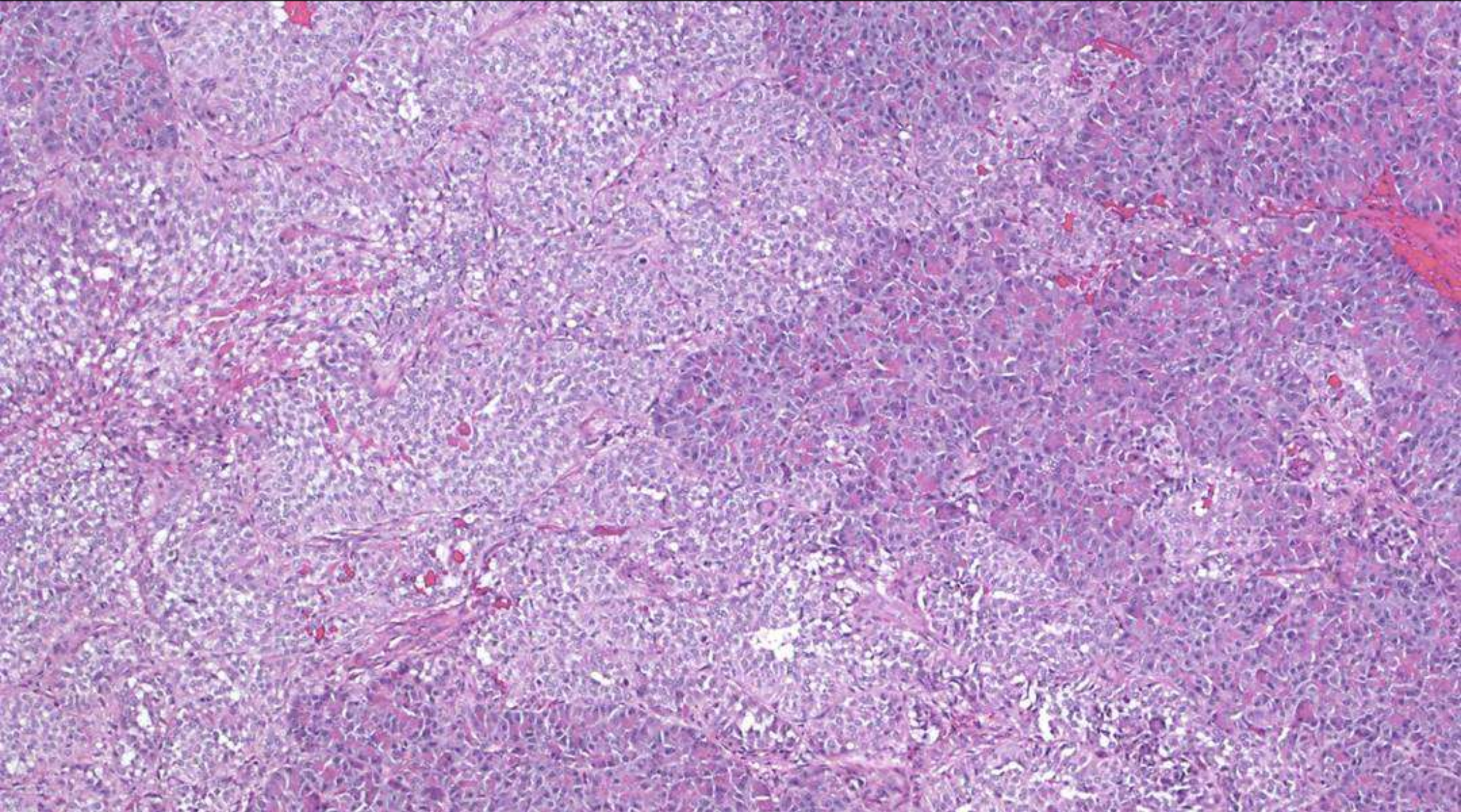


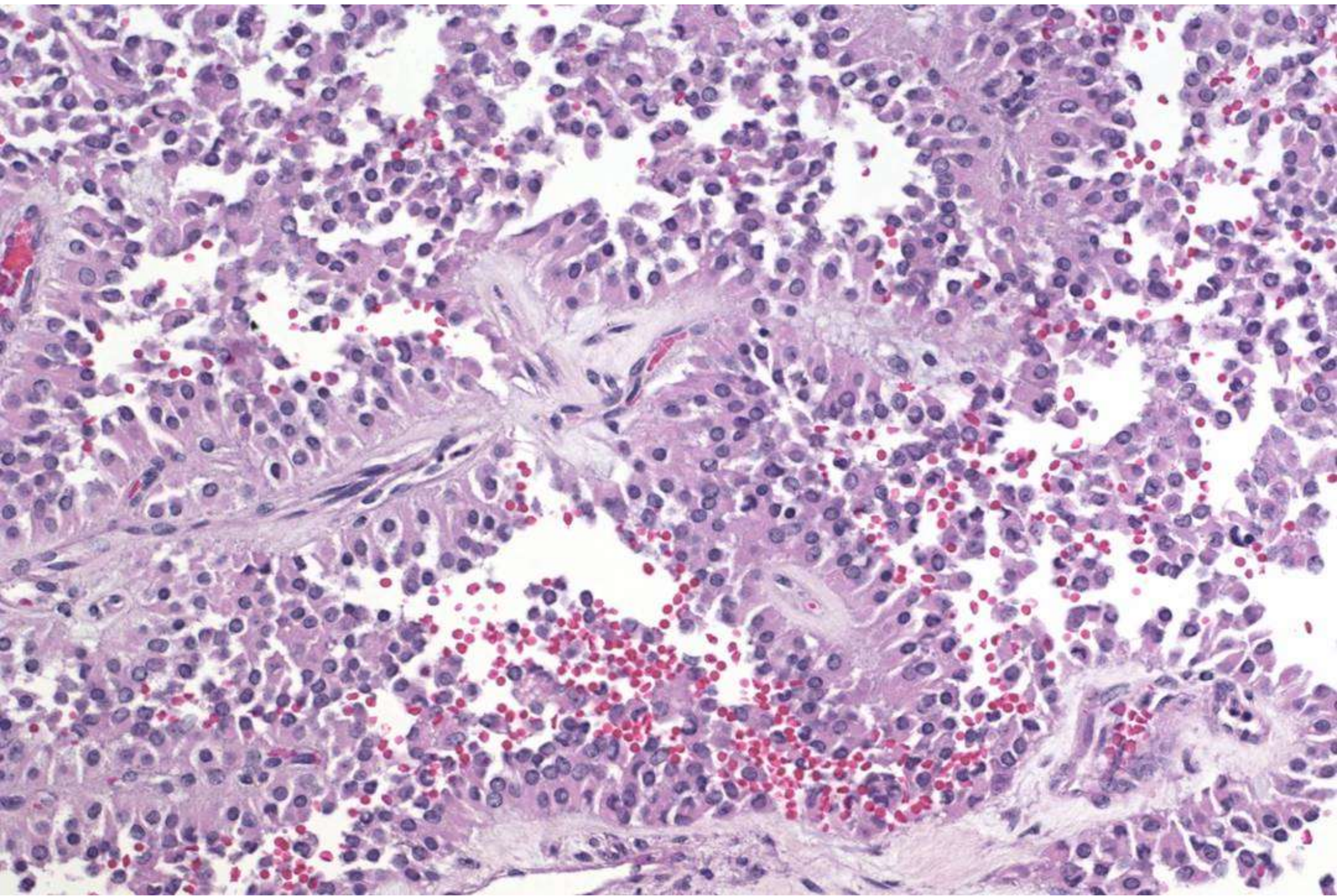


Based on AFIP Fascicle, 4th Edition

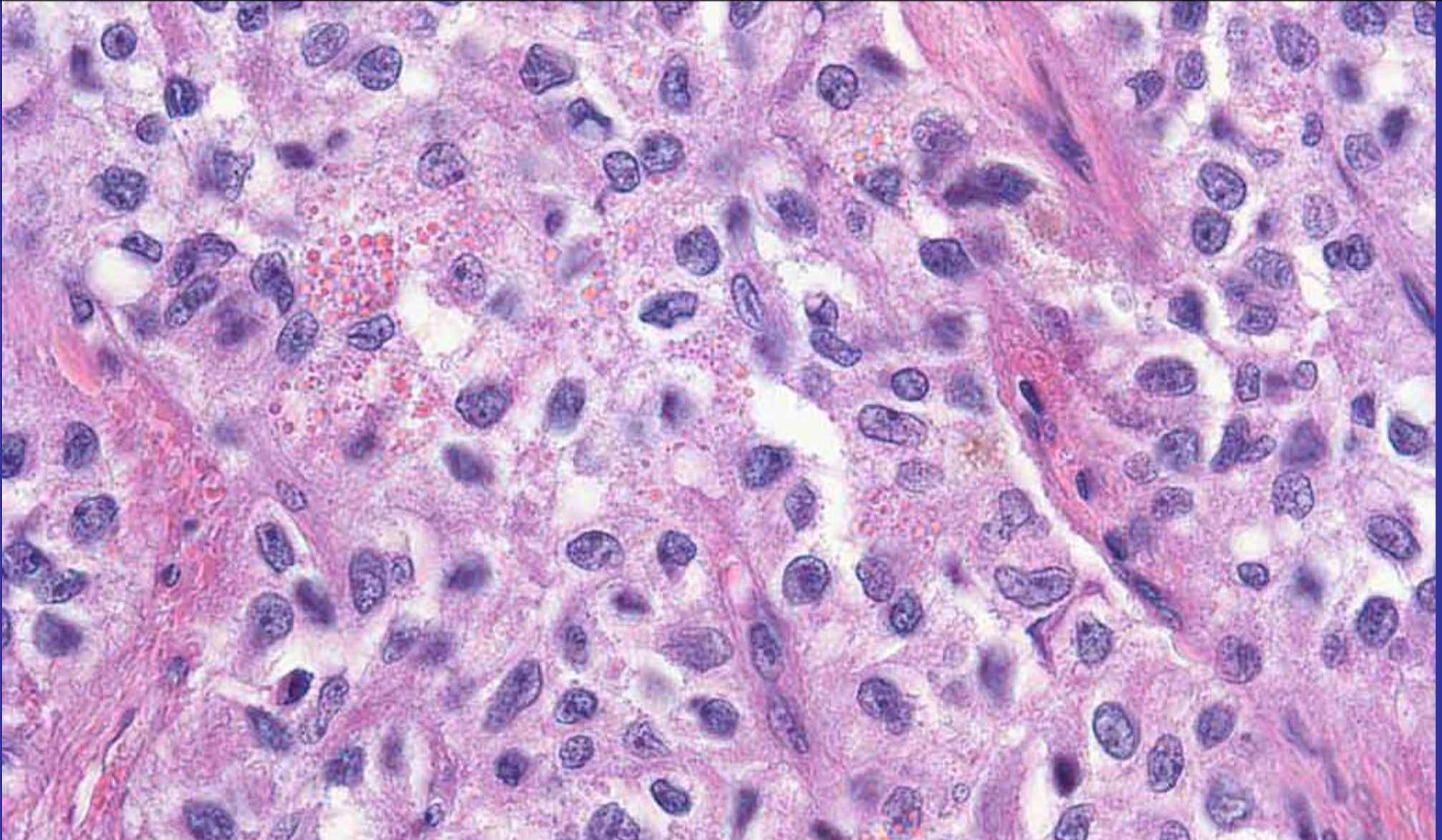


Growth Pattern: Insidious Pattern of Invasion

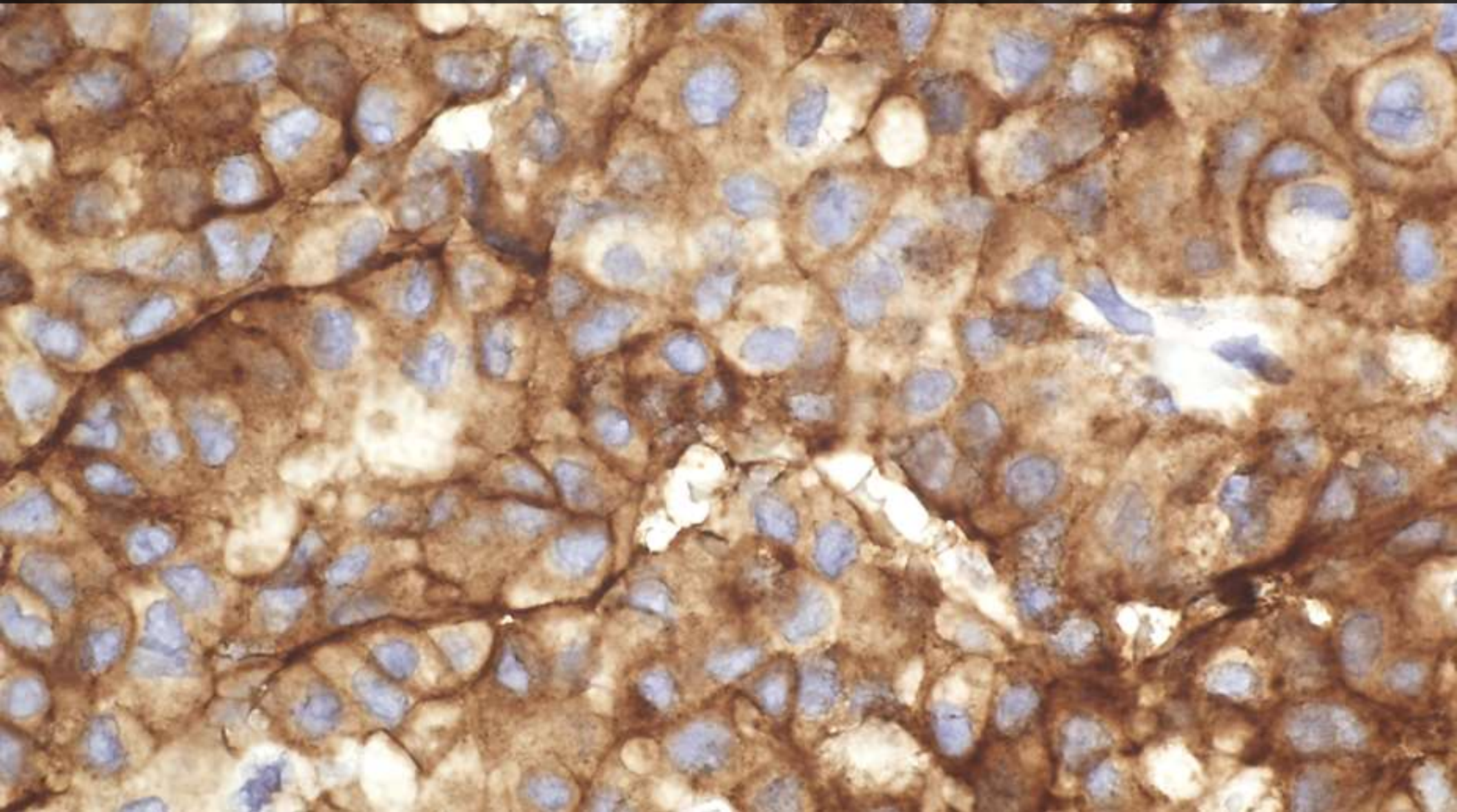




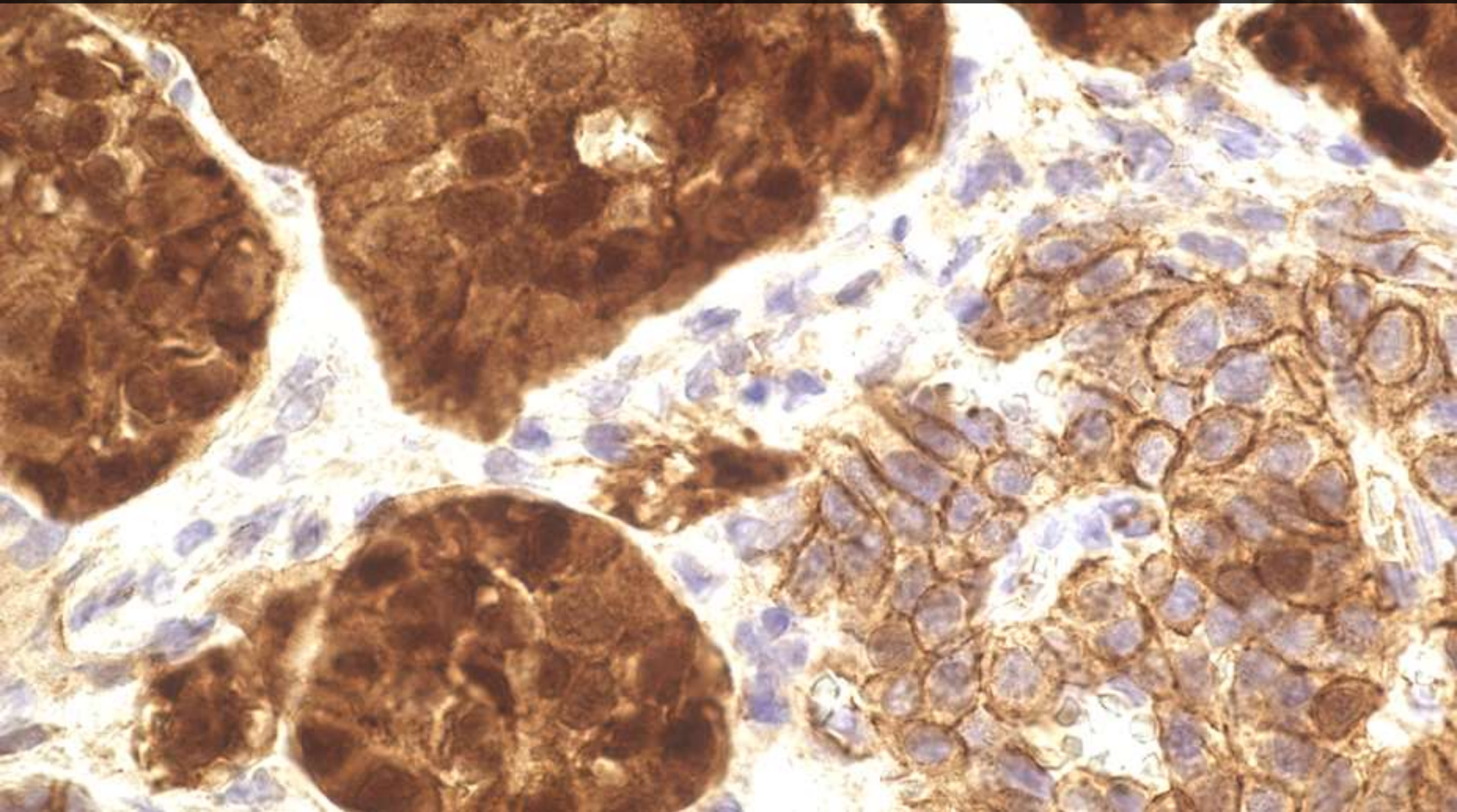
Nuclear: Grooves



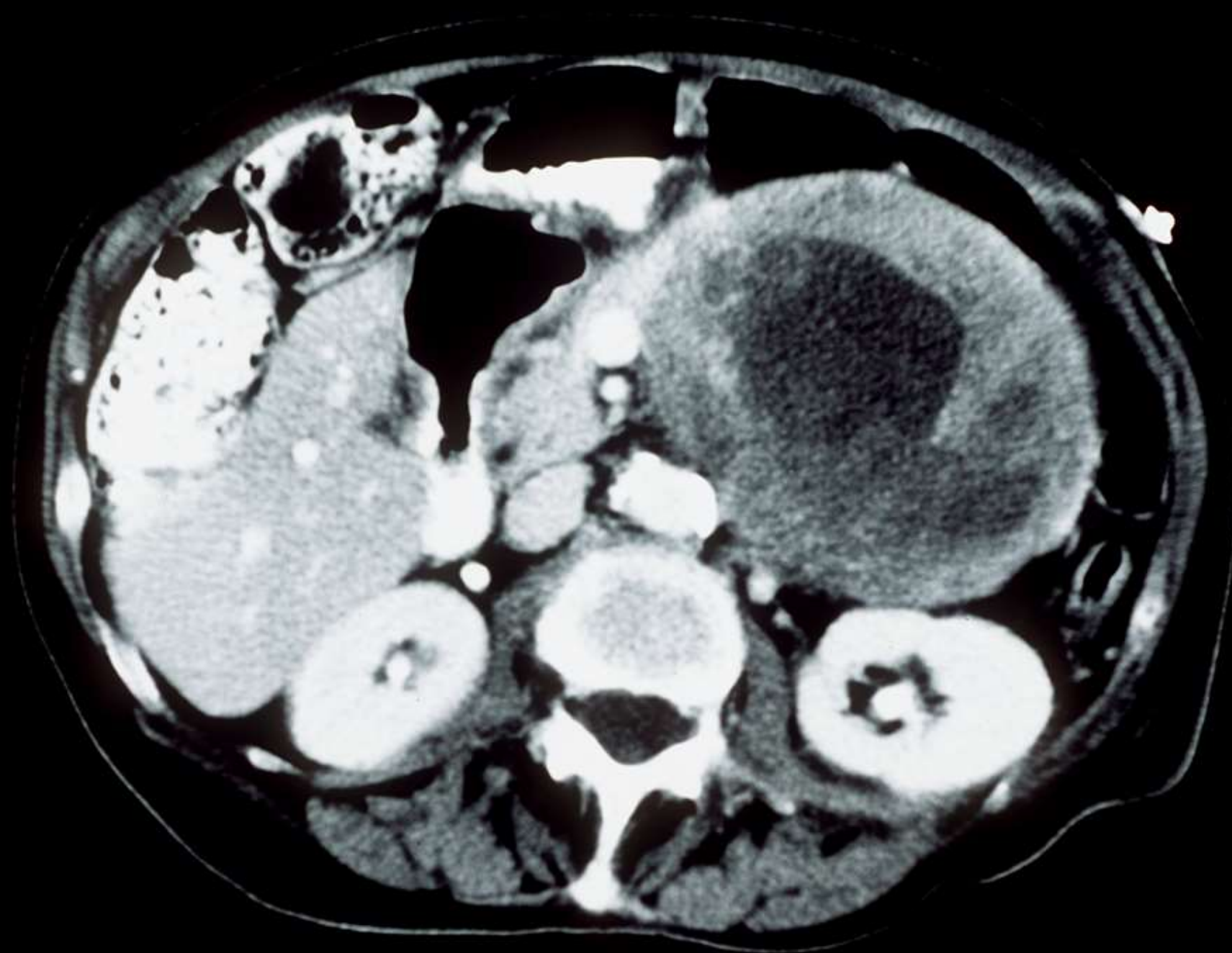
Immunohistochemistry: CD10



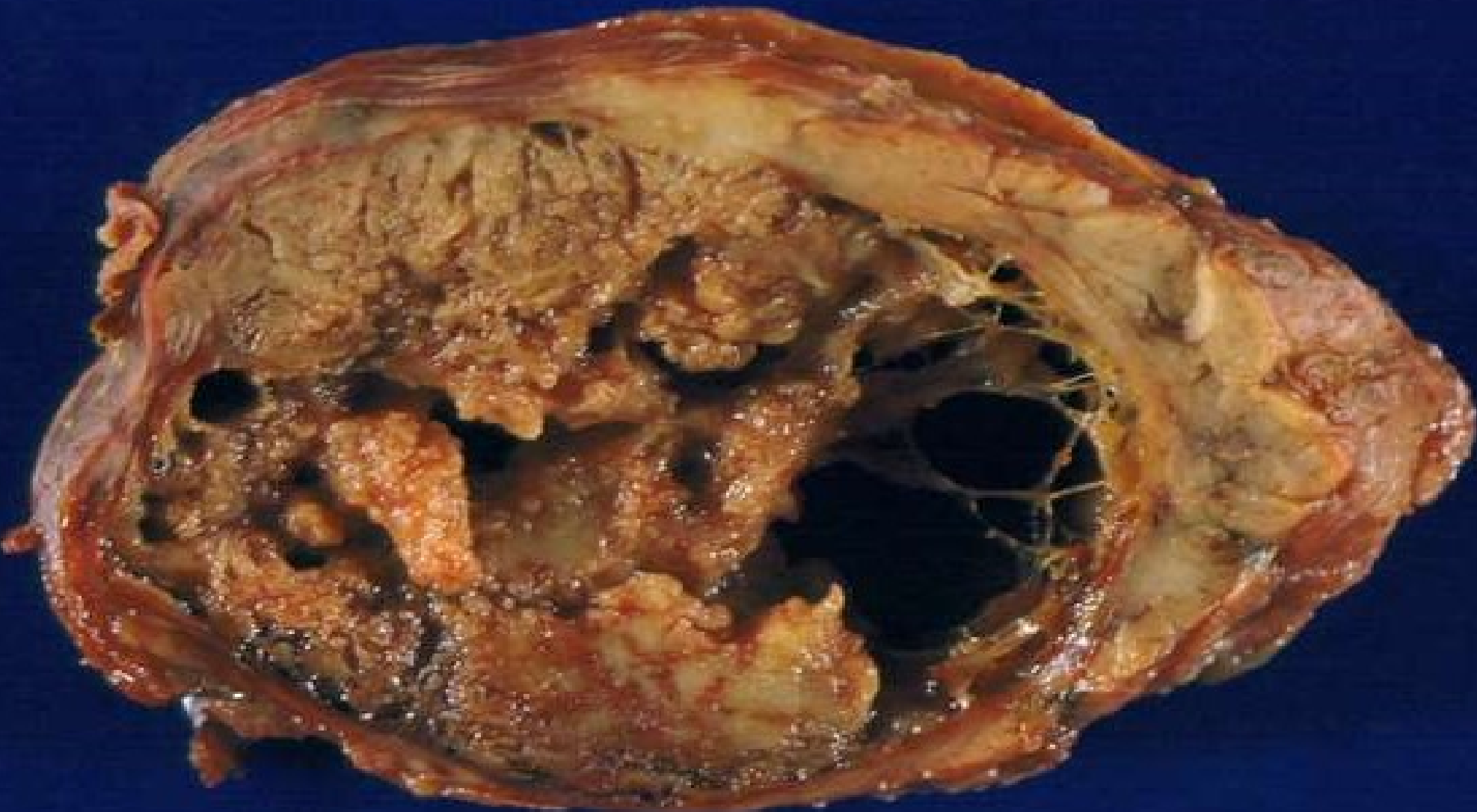
Immunohistochemistry: Beta-catenin



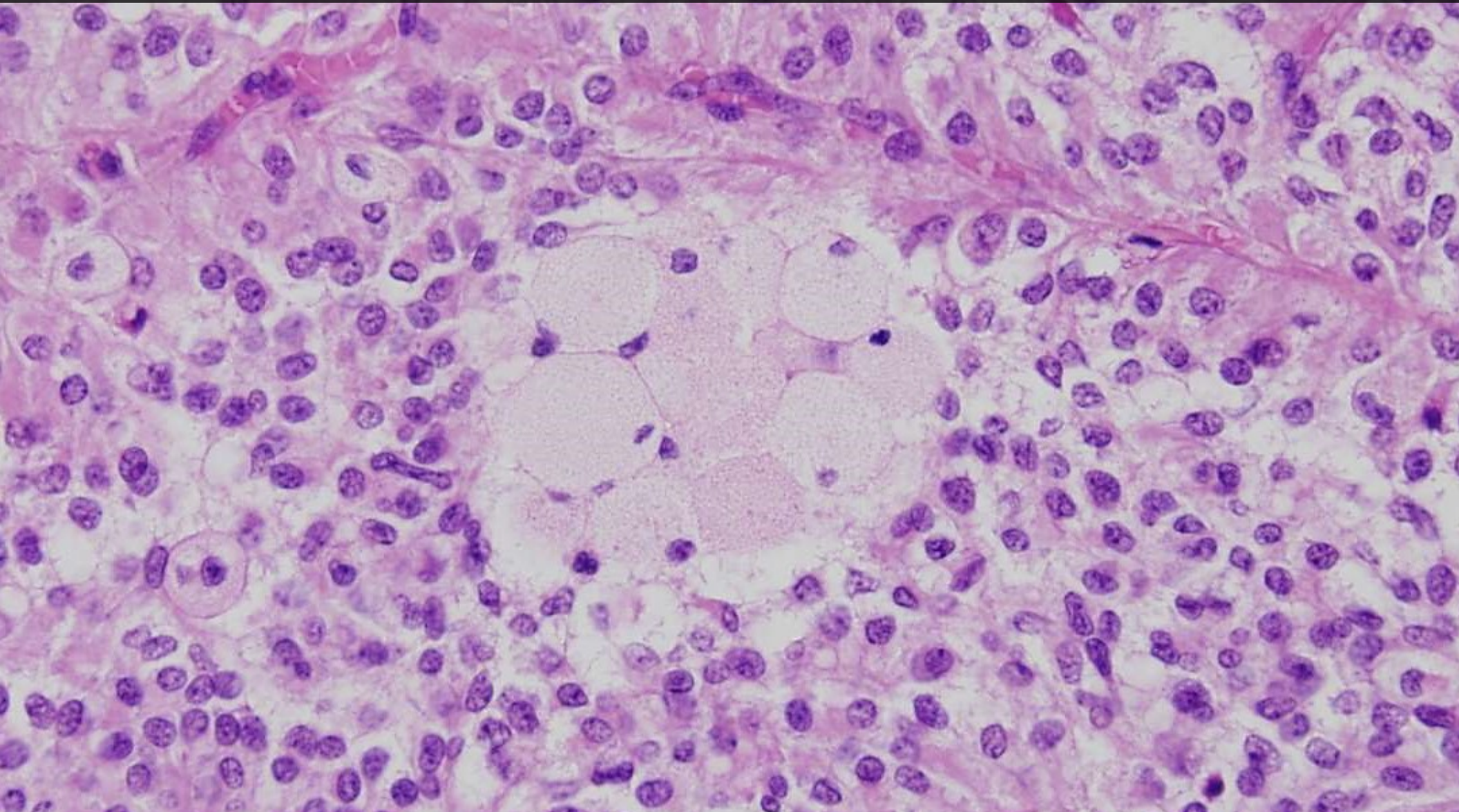
**Solid-
Pseudopapillary
Neoplasm**



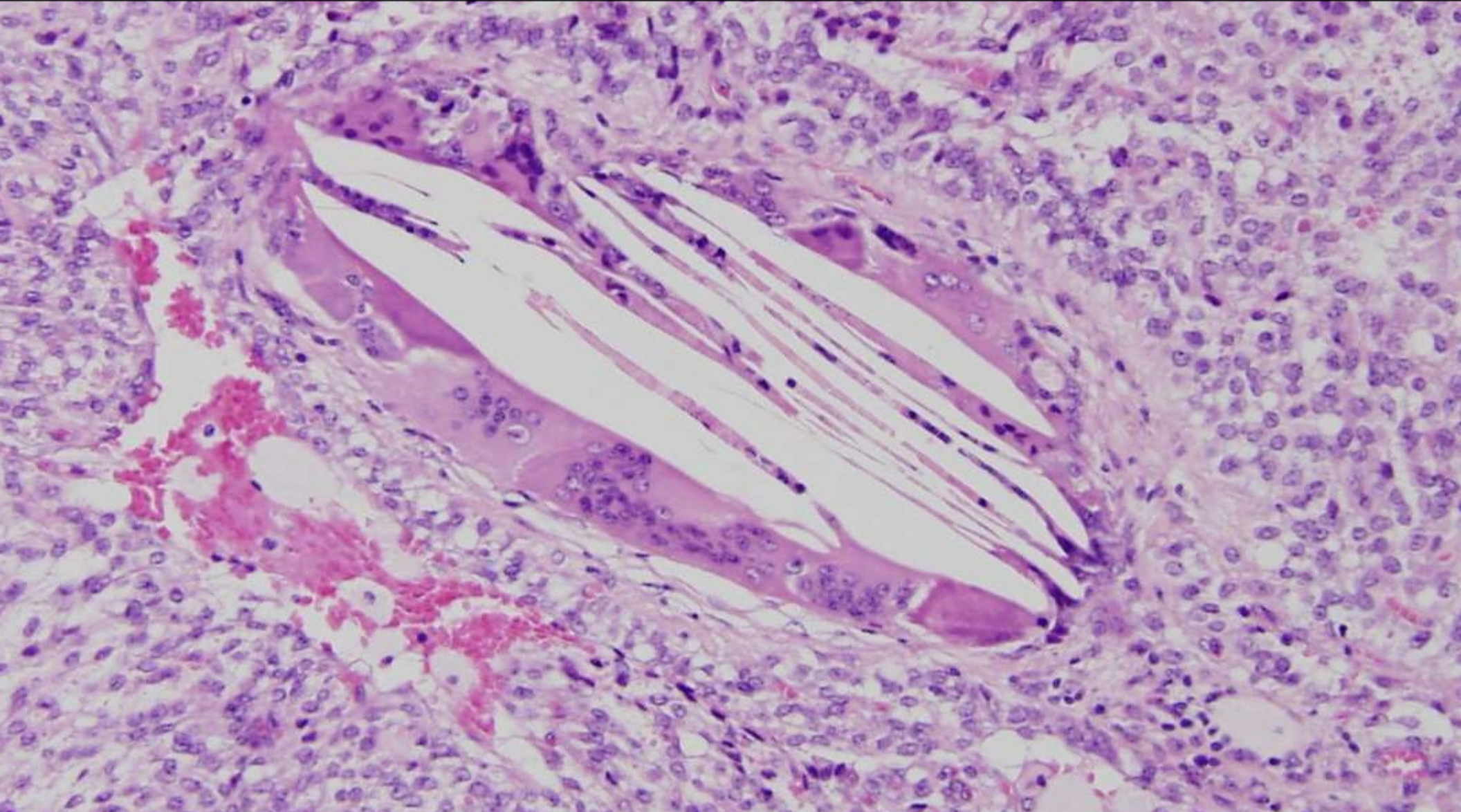
10 CM



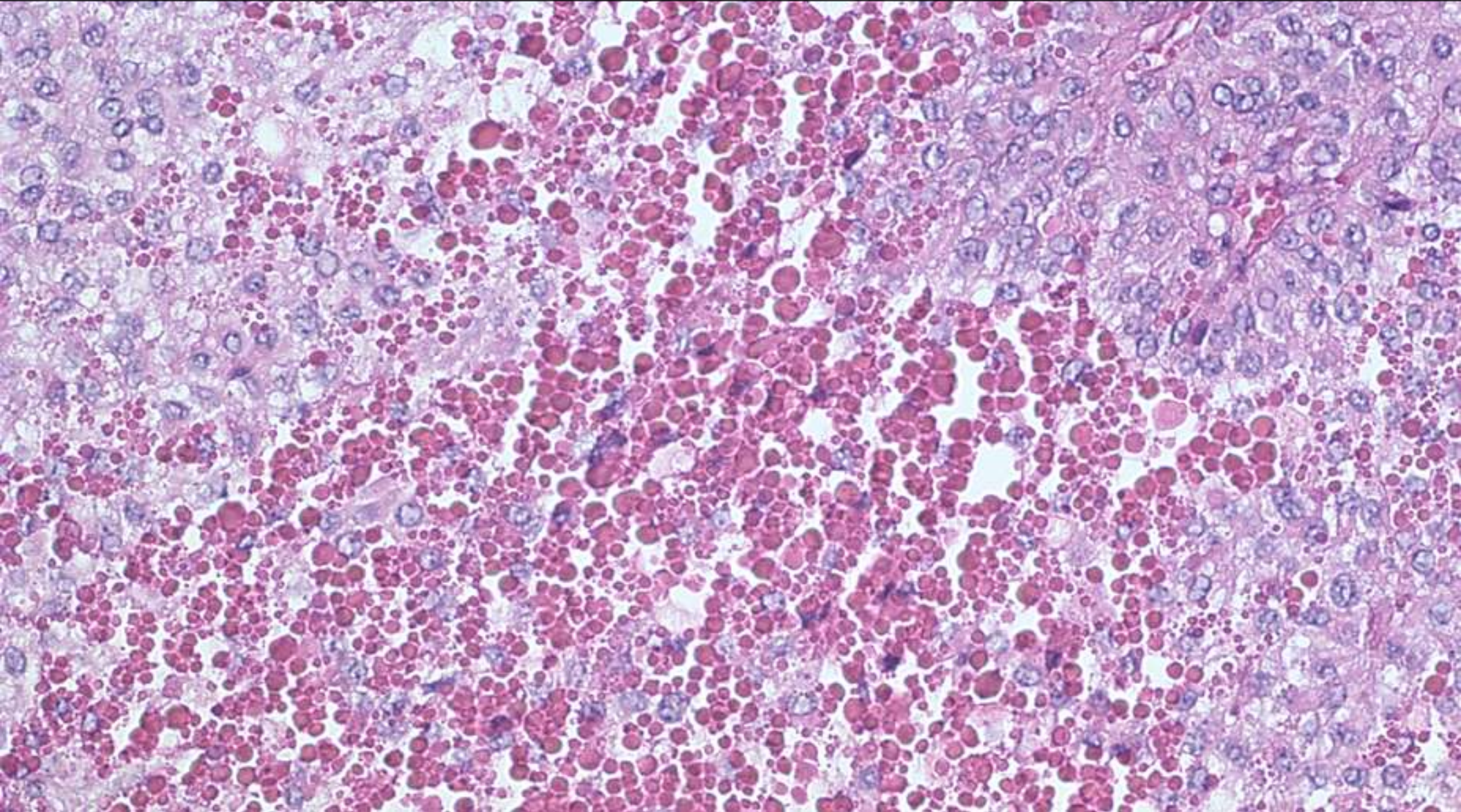
Foam Cells

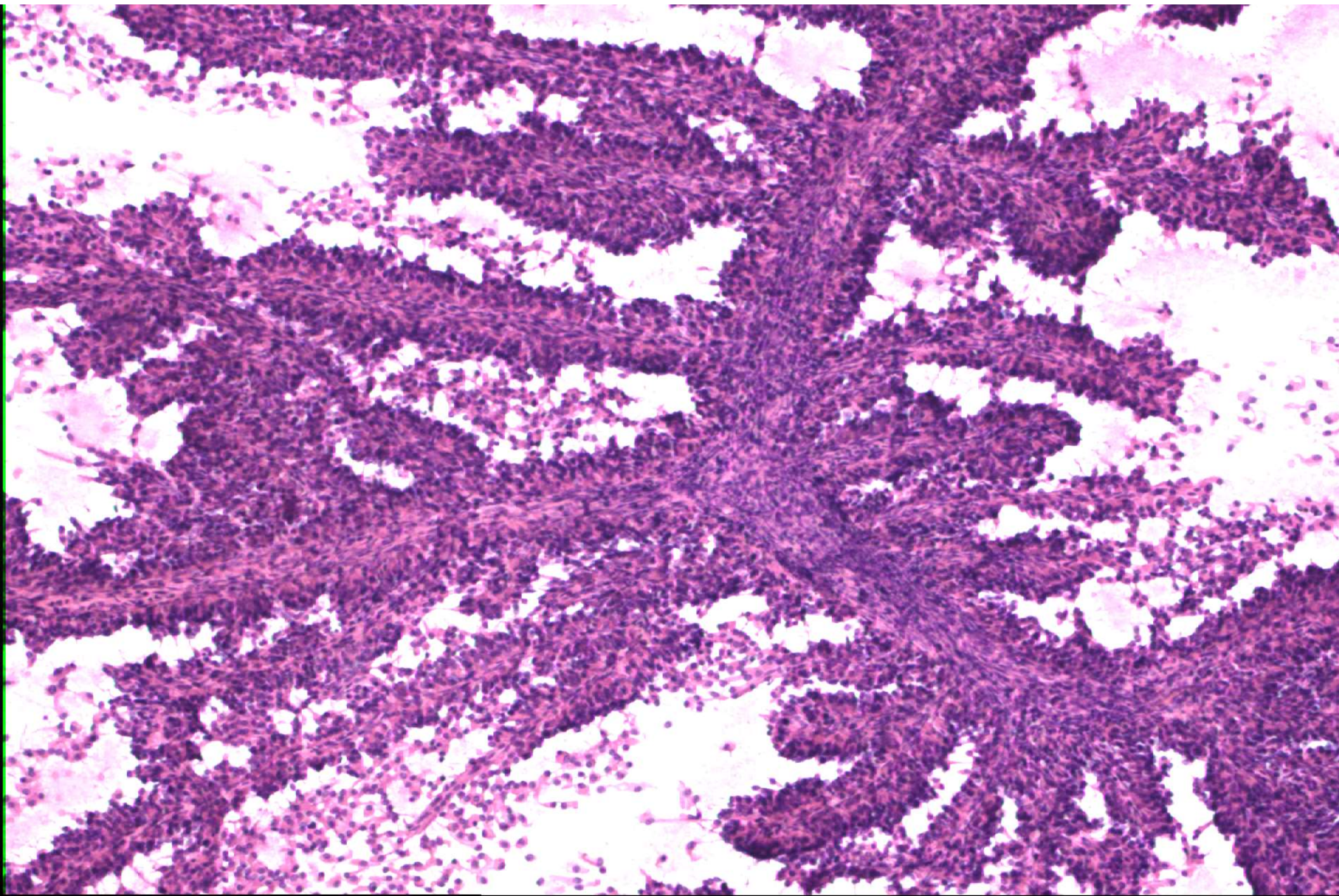


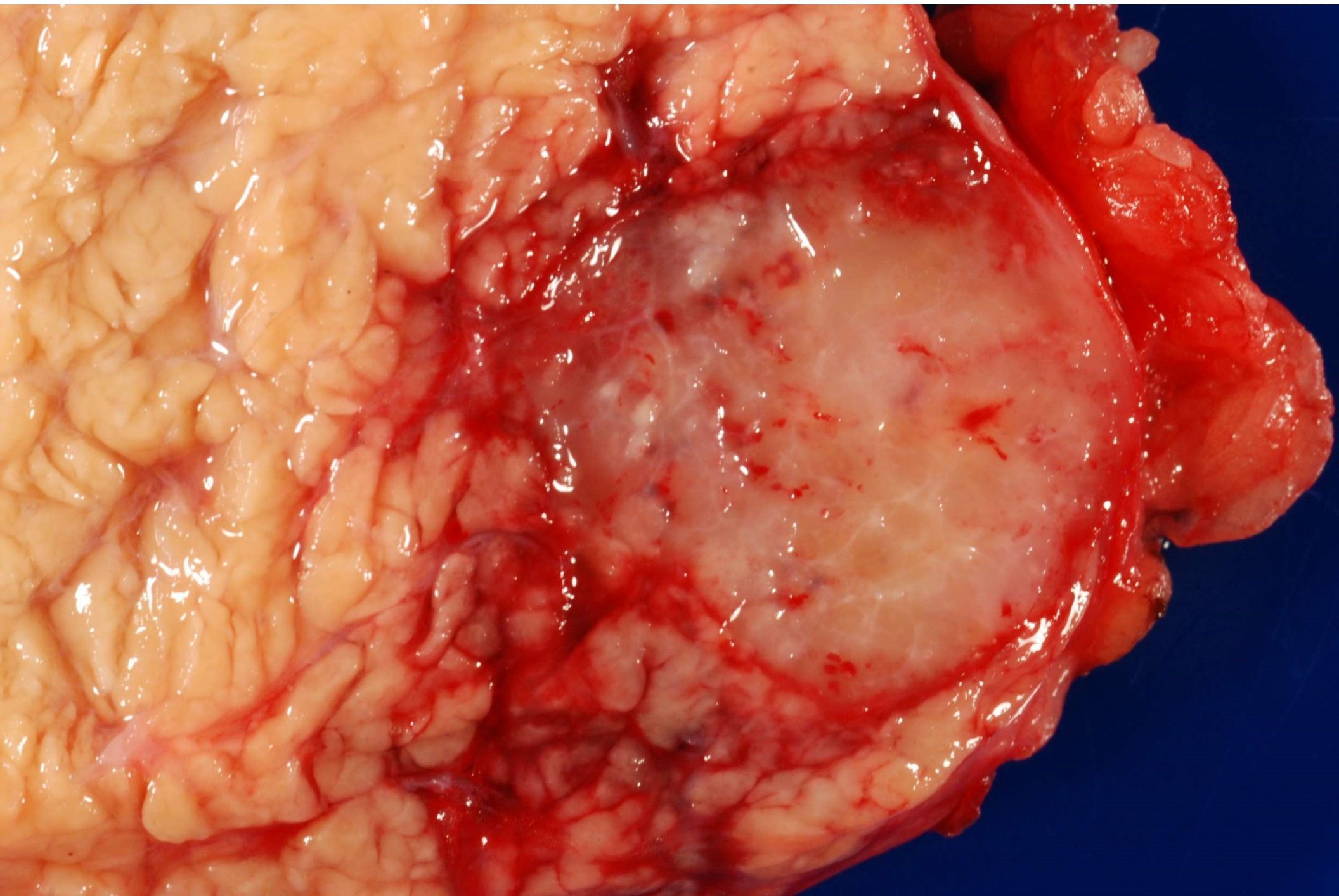
Cholesterol Clefts

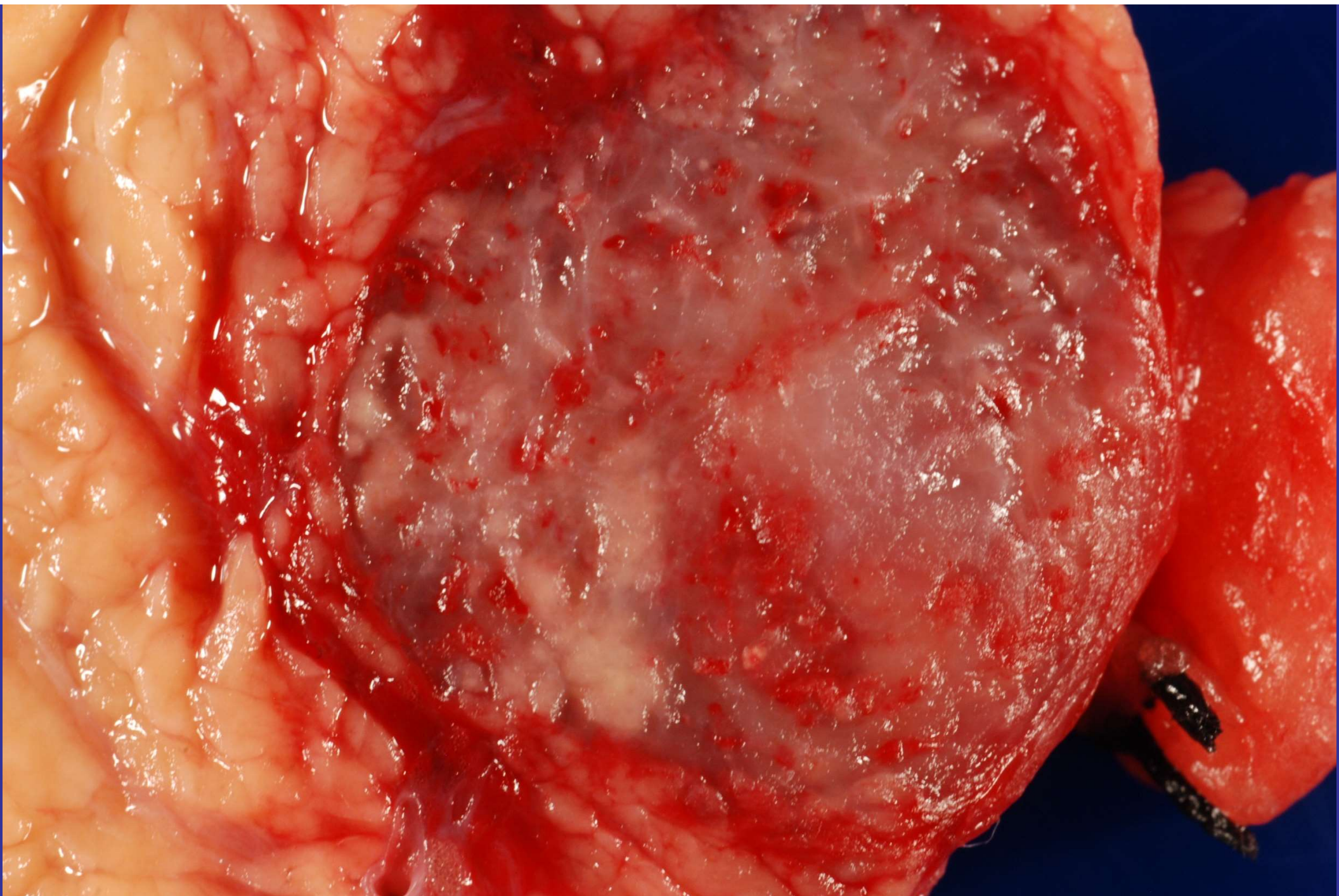


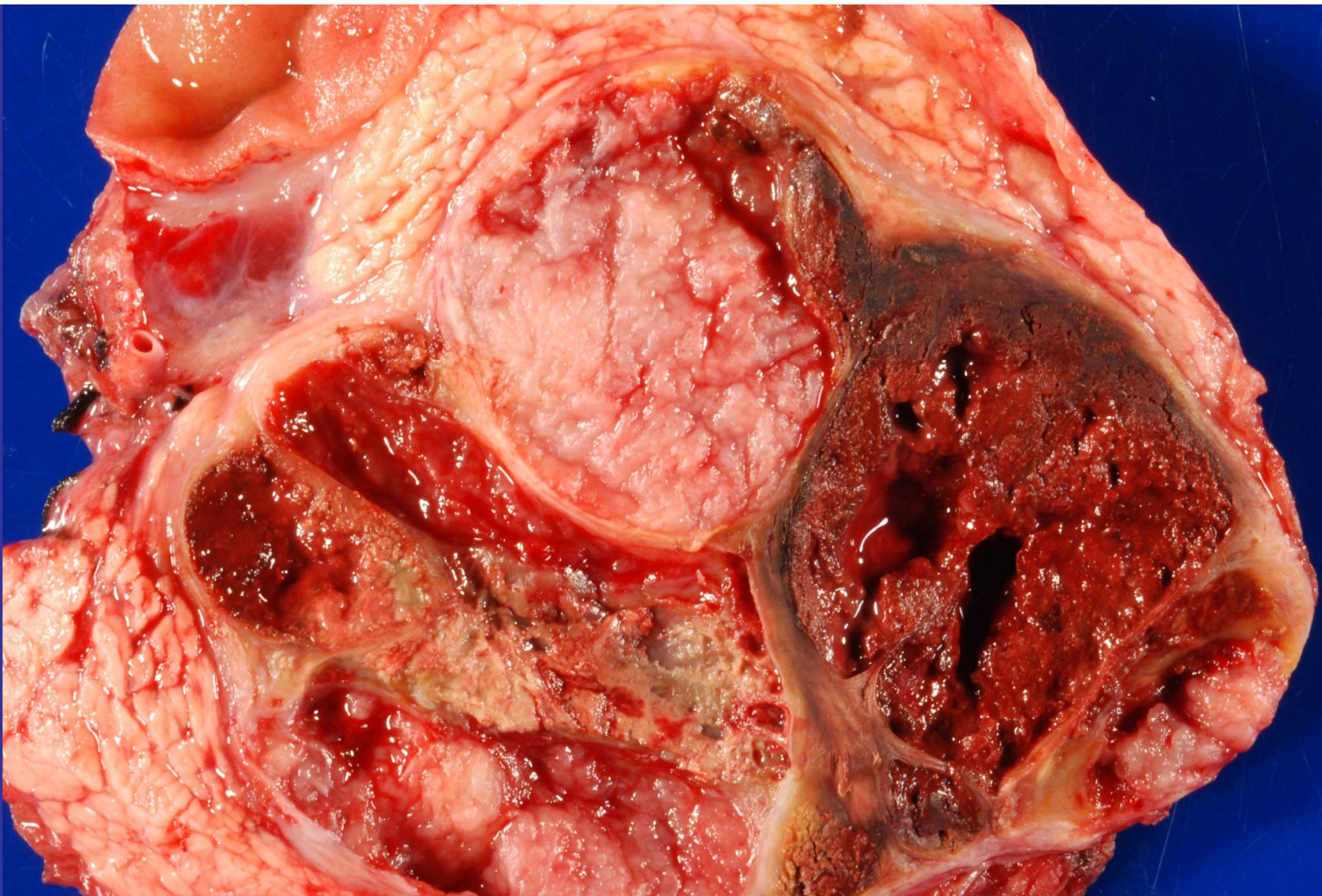
Hyaline Globules

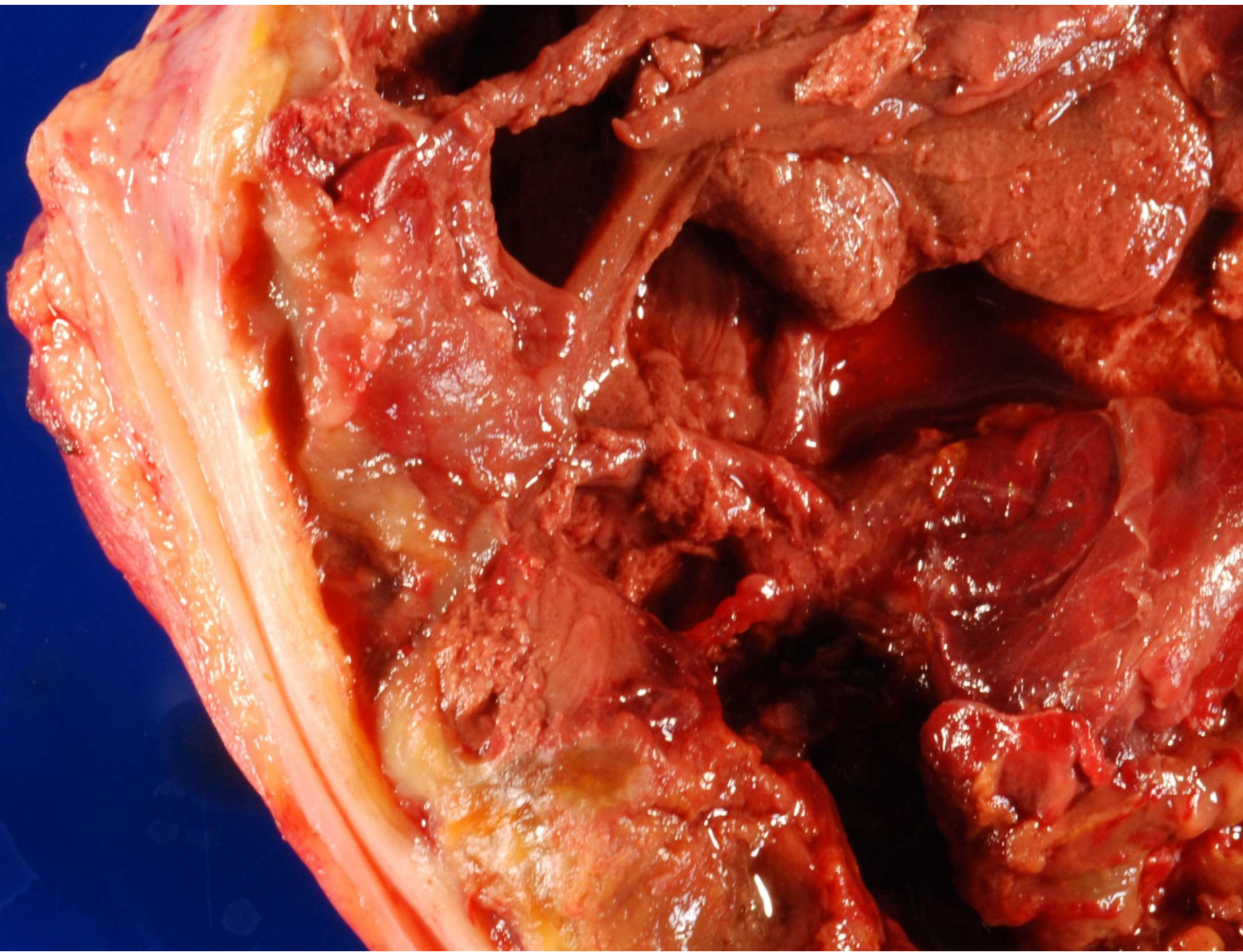






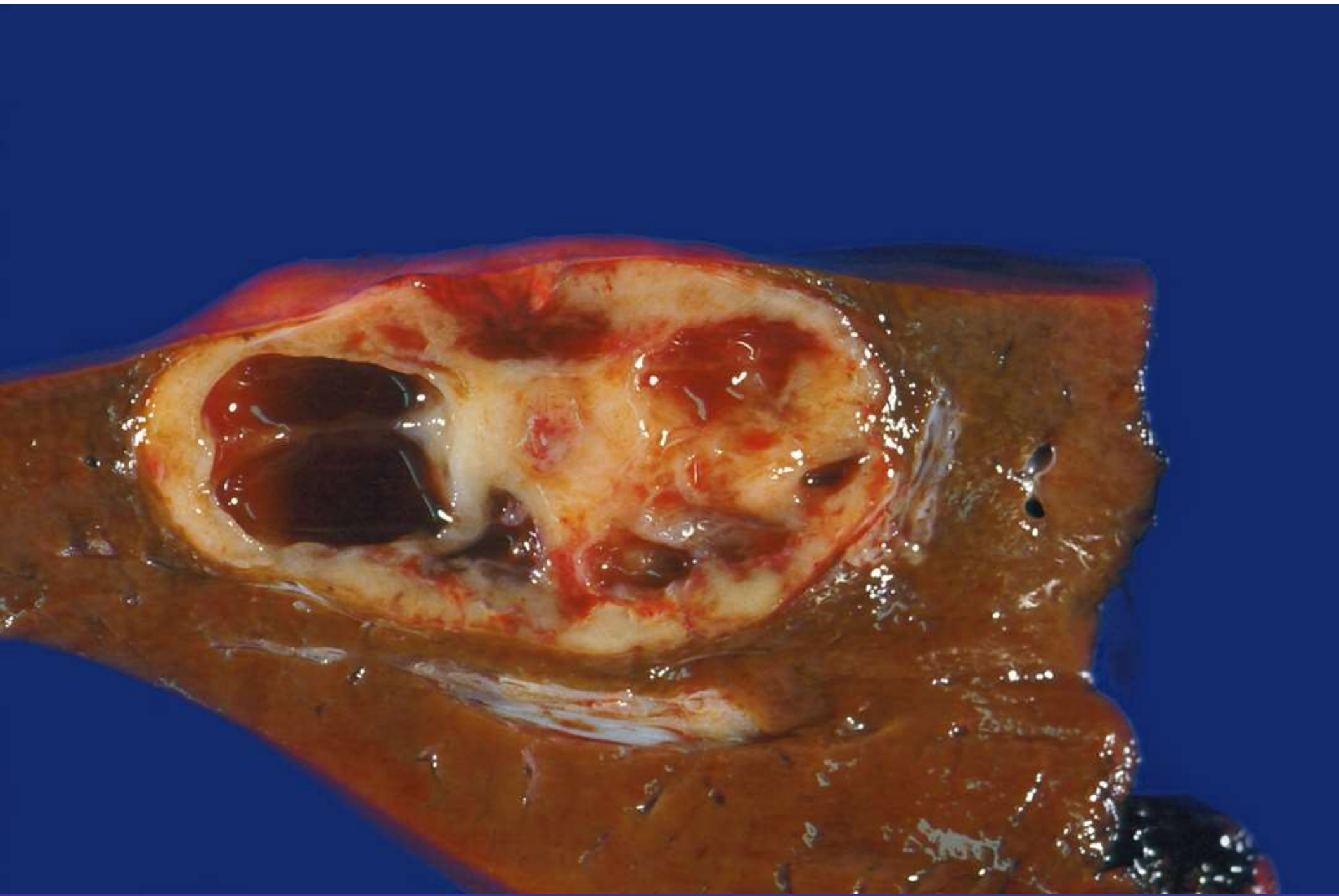






Solid-Pseudopapillary Neoplasm

- **Clinically, the vast majority occur in young women (20's)**
- **Patients present with vague abdominal fullness or pain**
- **Grossly well demarcated masses. On cross section, they are cystic and solid with areas of hemorrhage and necrosis**



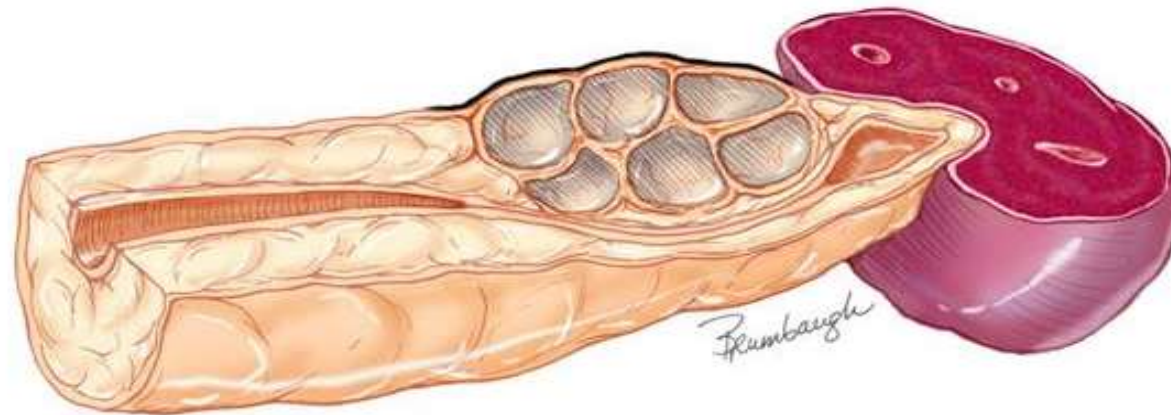
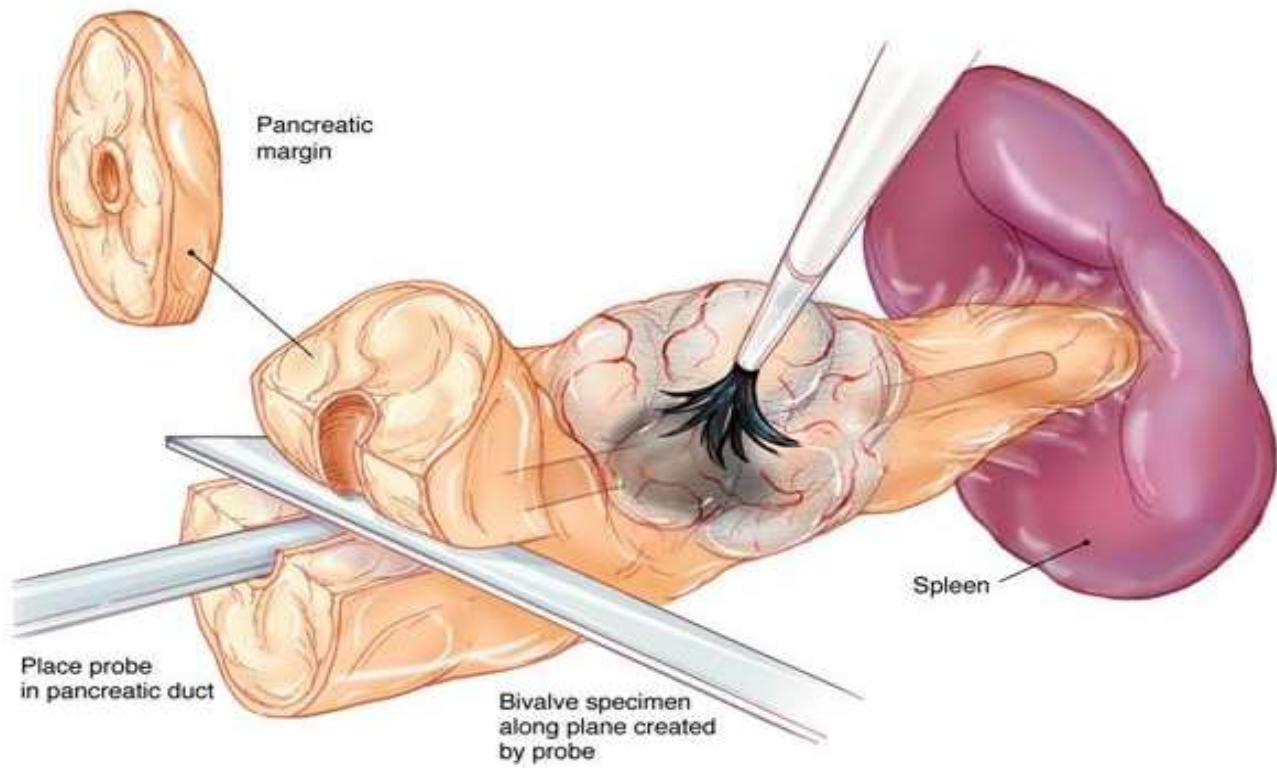
Solid-Pseudopapillary Neoplasms: Outcome

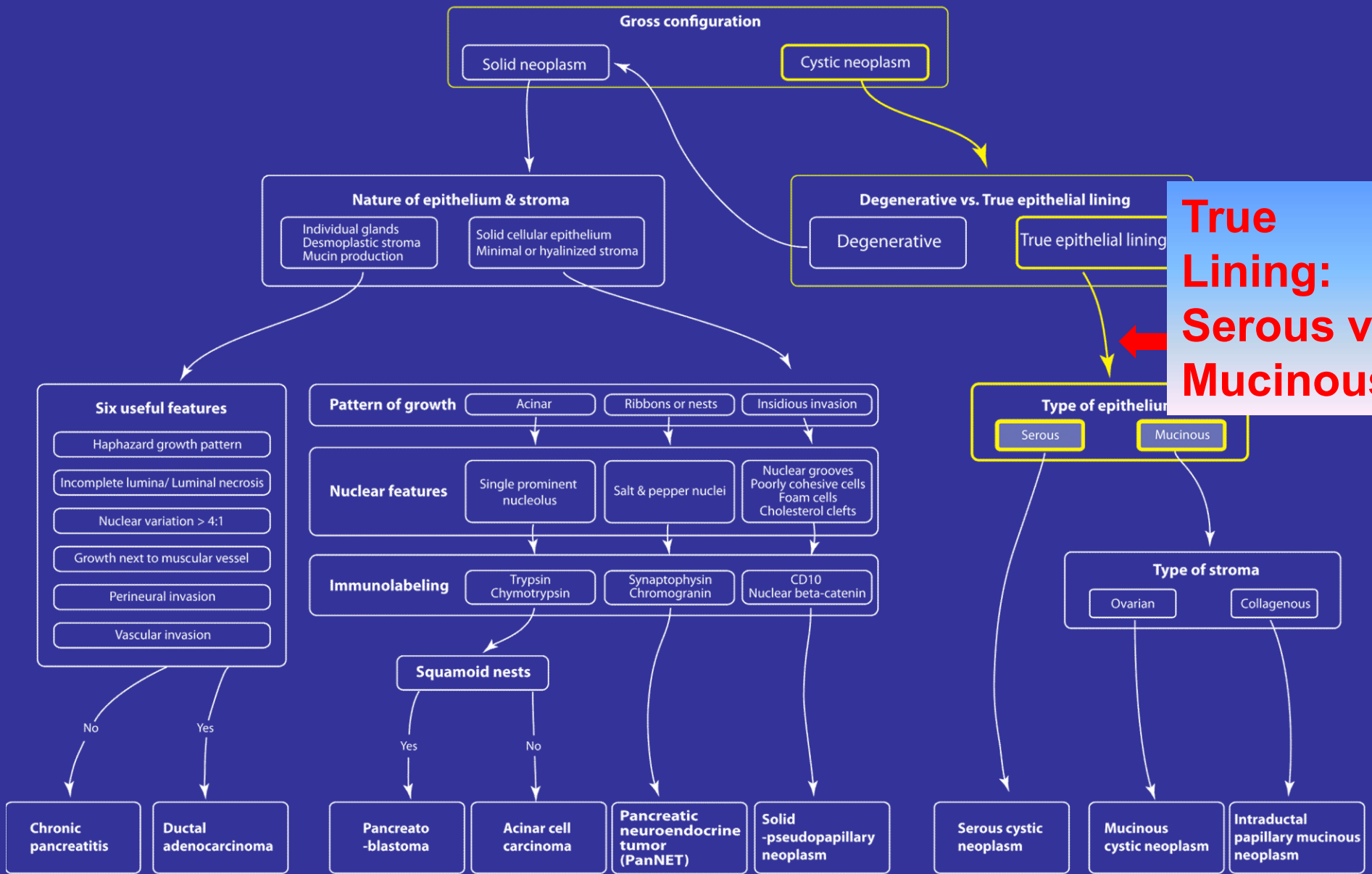
- **All are classified as malignant.**
- **Some may be locally aggressive, but most are surgically cured.**

Truly Cystic Neoplasms

- Gender
- Tail vs. Head
- Relationship to larger pancreatic ducts
- Character of cyst fluid
- Lining (serous vs. mucinous vs. none)
- Stroma (ovarian-type)

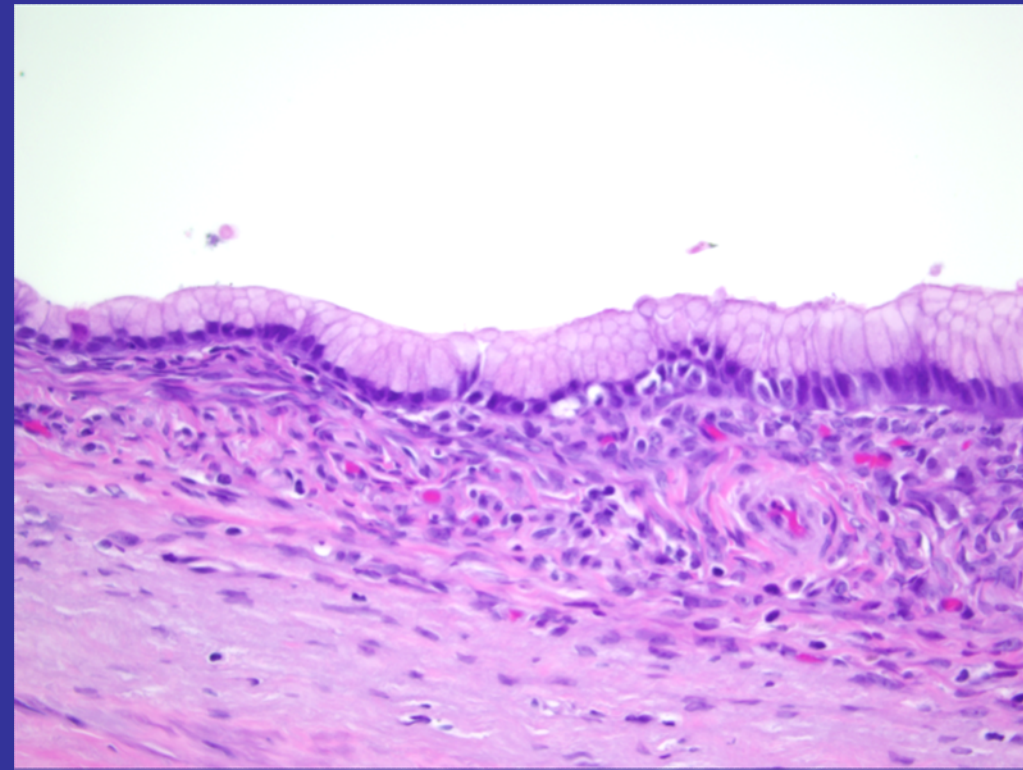
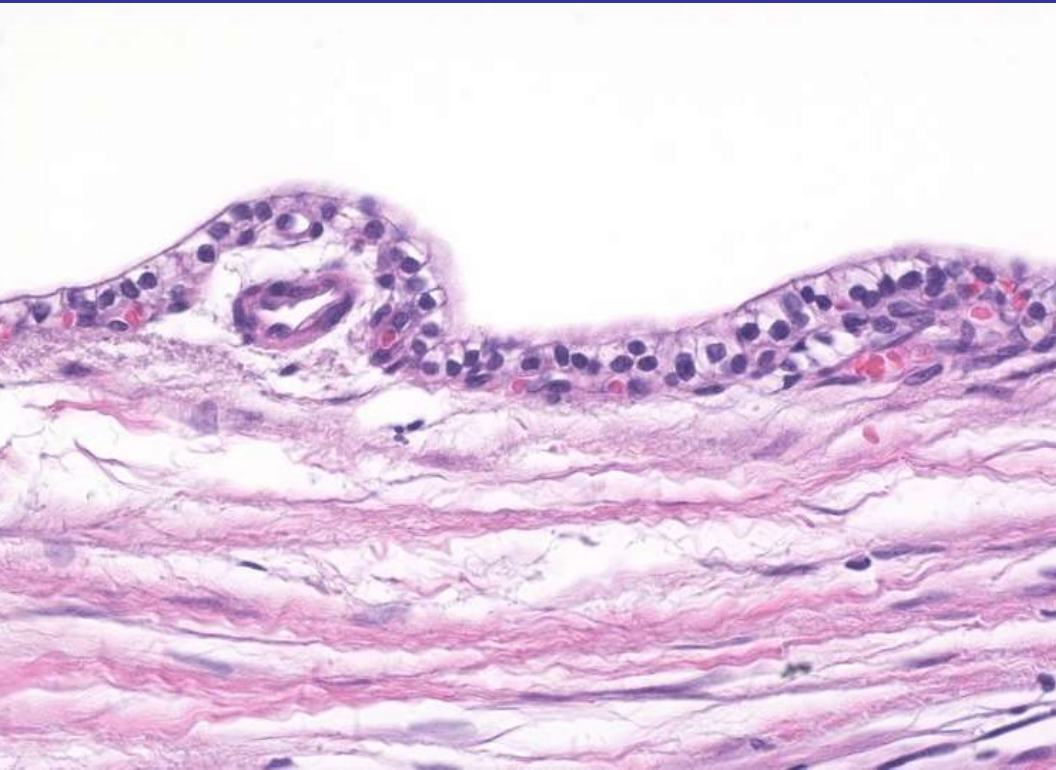
| | Mucinous Cystic Neoplasm | Intraductal papillary Mucinous Neoplasm | Solid-pseudopapillary Neoplasm | Serous Cystic Neoplasm |
|-------------------------|---------------------------------|--|---------------------------------------|-------------------------------|
| Gender (F:M) | 20:1 | 1:1.5 | 10:1 | 7:3 |
| Head/Tail | Tail | Head | Tail=Head | Tail=Head |
| Relation to Duct | None | Always | None | None |
| Cyst Contents | Mucinous | Mucinous | Necrotic/ Hemorrhagic | Serous |
| Epithelium | Mucinous | Mucinous | Non-cohesive | Serous |
| Stroma | Ovarian | None | None | None |



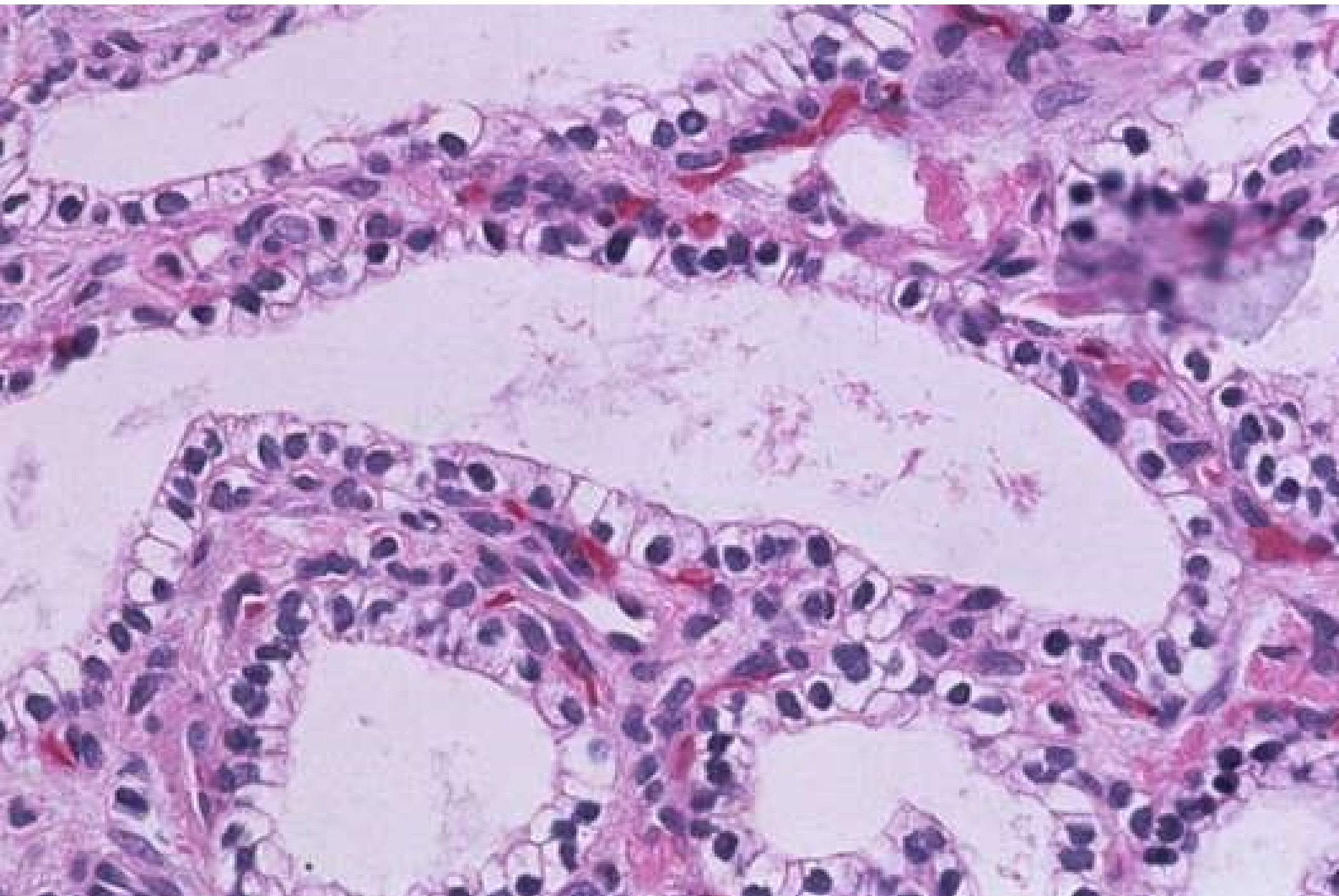


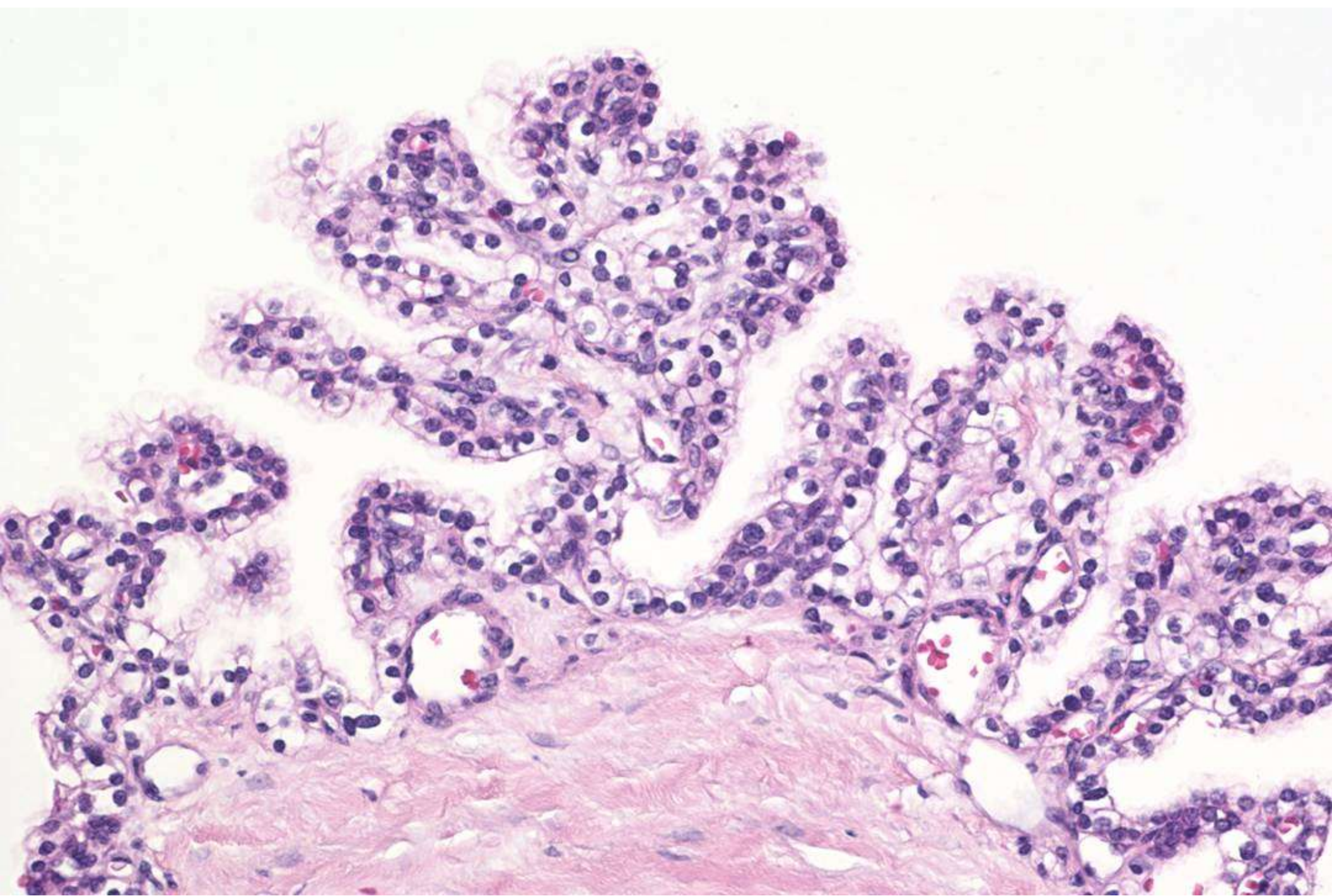
Based on AFIP Fascicle, 4th Edition

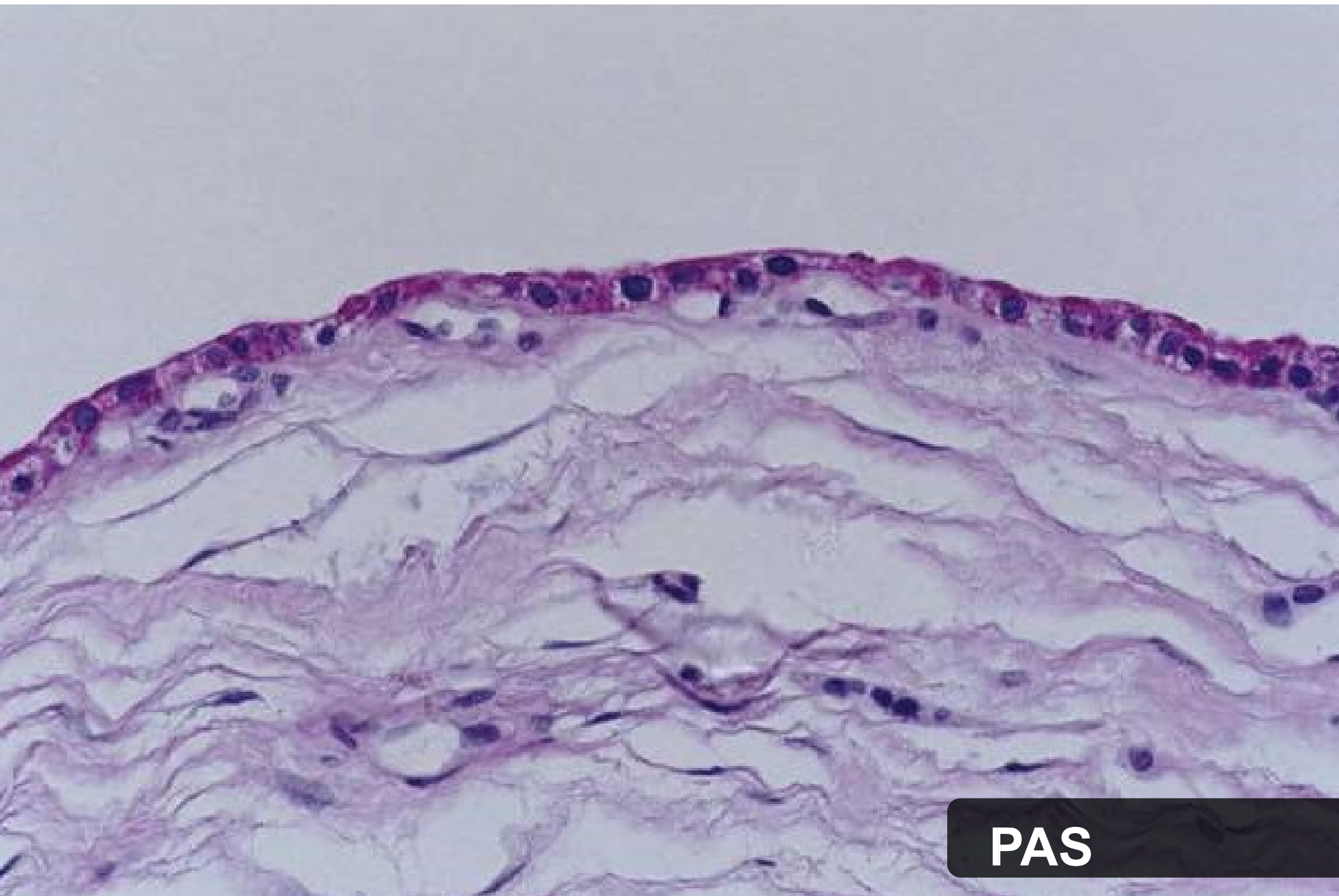
Serous vs. Mucinous



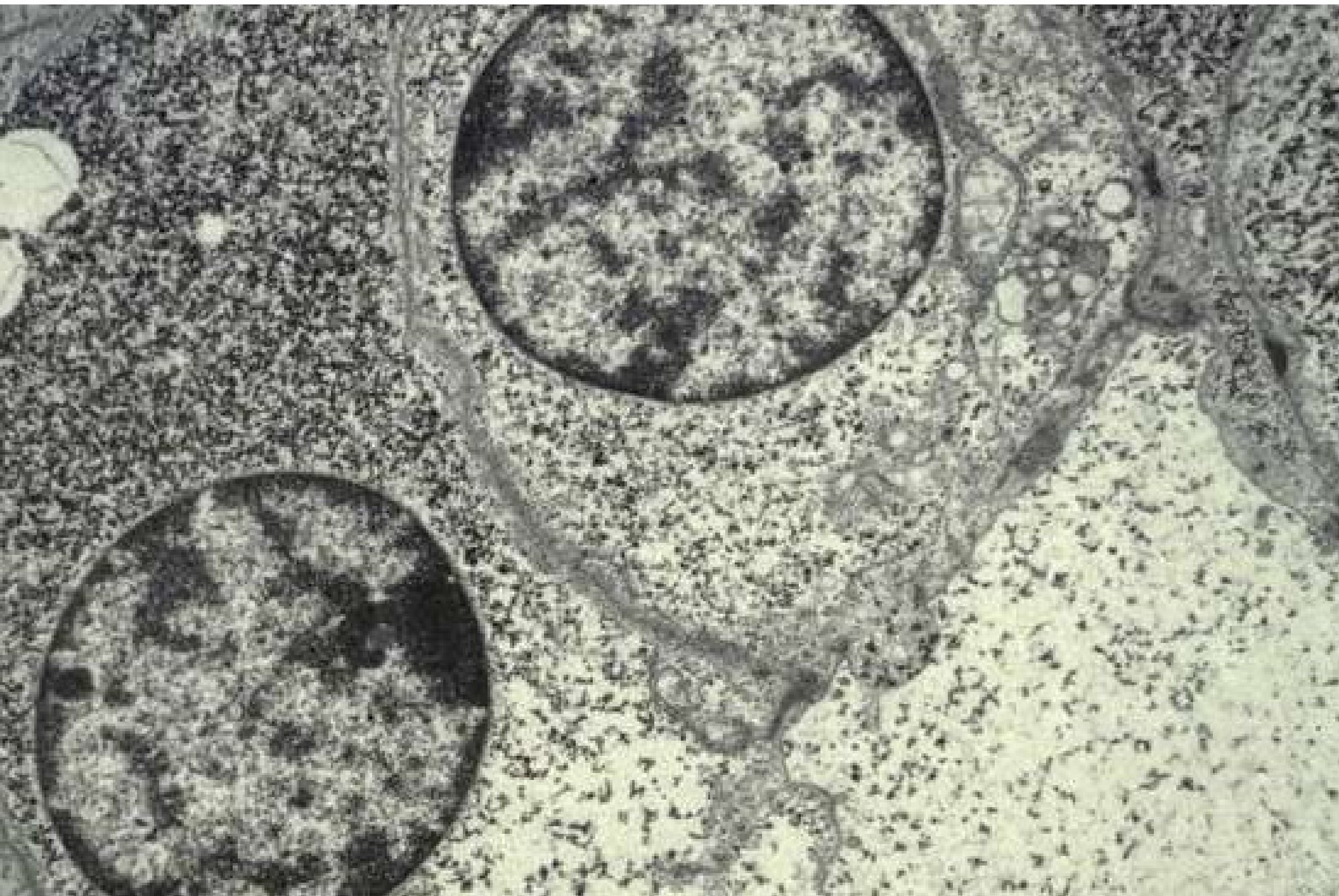
Serous Neoplasms







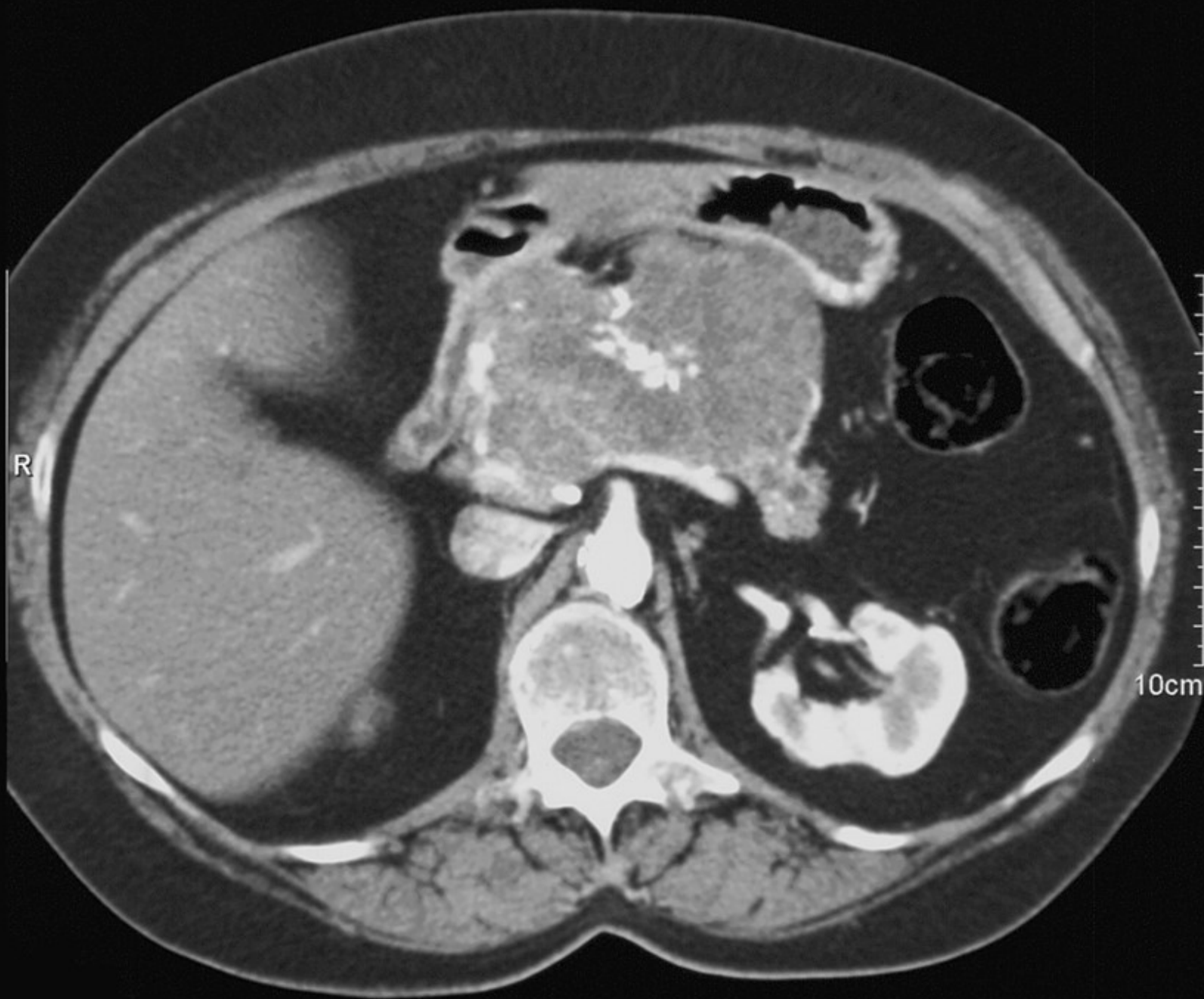PAS

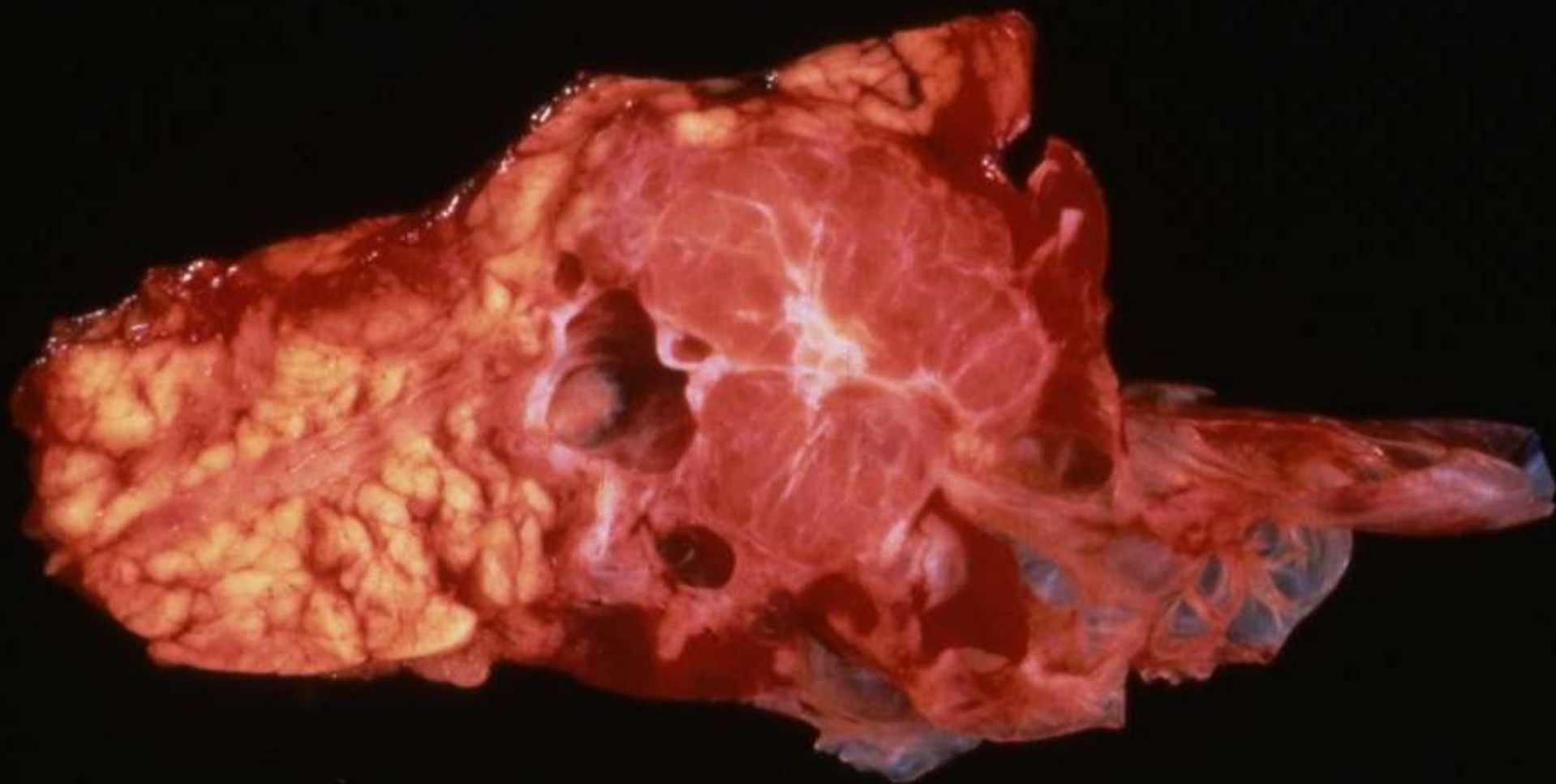


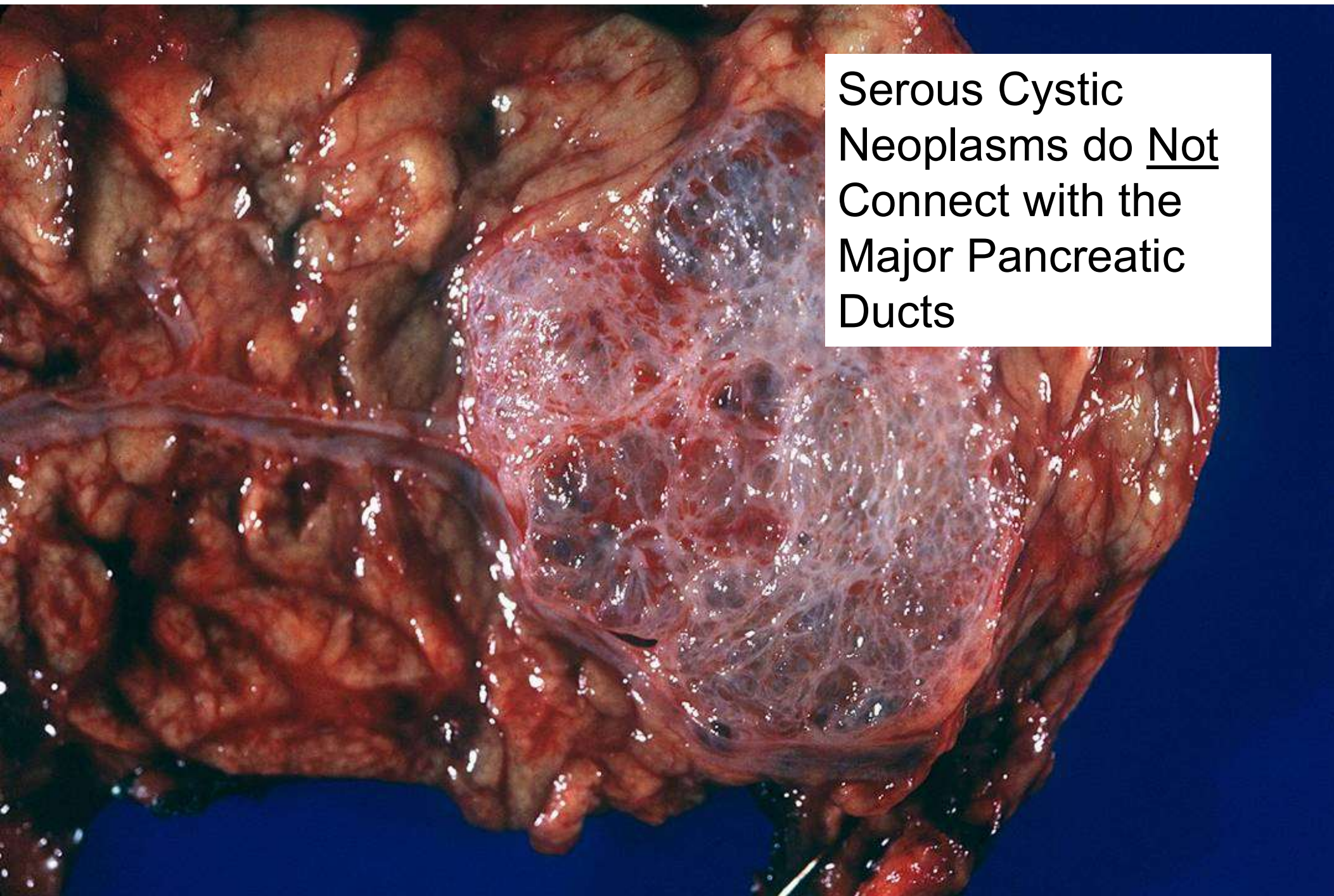
Serous Cystadenomas

Clinical

- **More common in women than in men**
- **Average age at diagnosis: 61-68 years**
- **Presenting signs and symptoms include:**
 - **abdominal pain**
 - **weight loss**
 - **palpable abdominal mass**

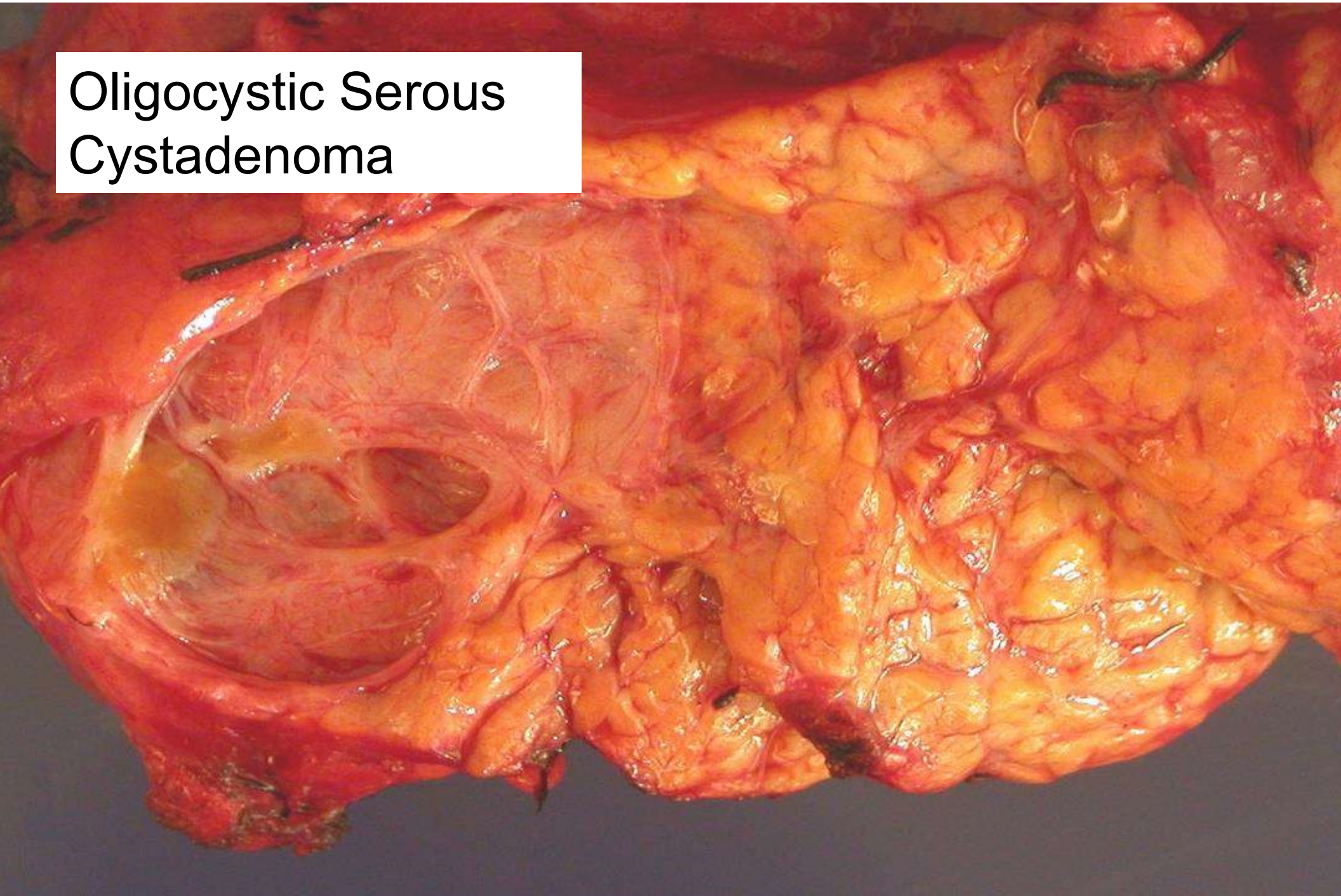






Serous Cystic
Neoplasms do Not
Connect with the
Major Pancreatic
Ducts

Oligocystic Serous Cystadenoma

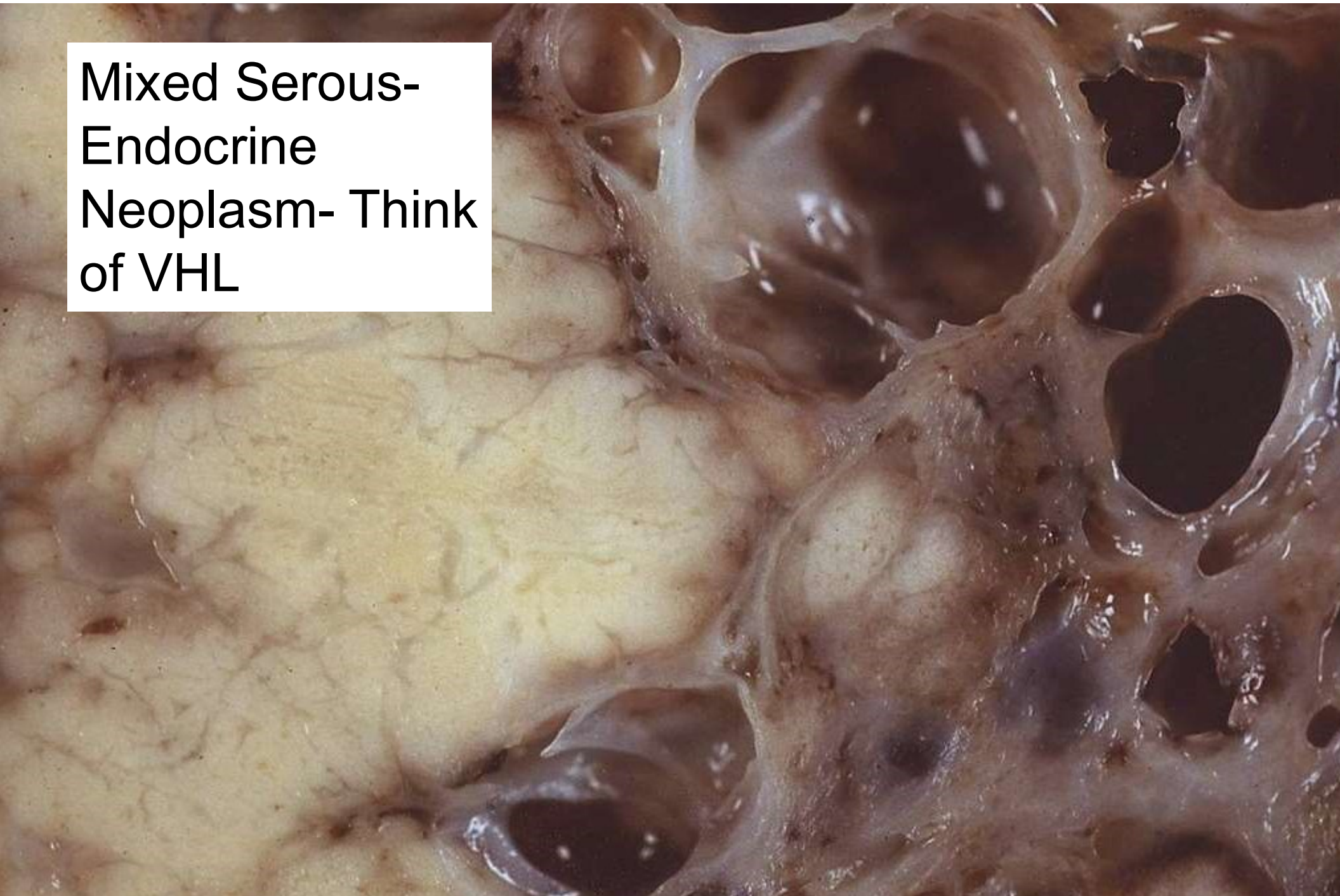


A gross specimen of a solid serous neoplasm, likely an ovarian tumor, is shown. The tumor is a large, rounded, pinkish-tan mass with a lobulated surface. It is surrounded by a thick, white, fibrous capsule. The surrounding tissue is dark red and appears to be the surface of the ovary. A scale bar in the bottom right corner indicates 1 cm.

**Solid Serous
Neoplasm**

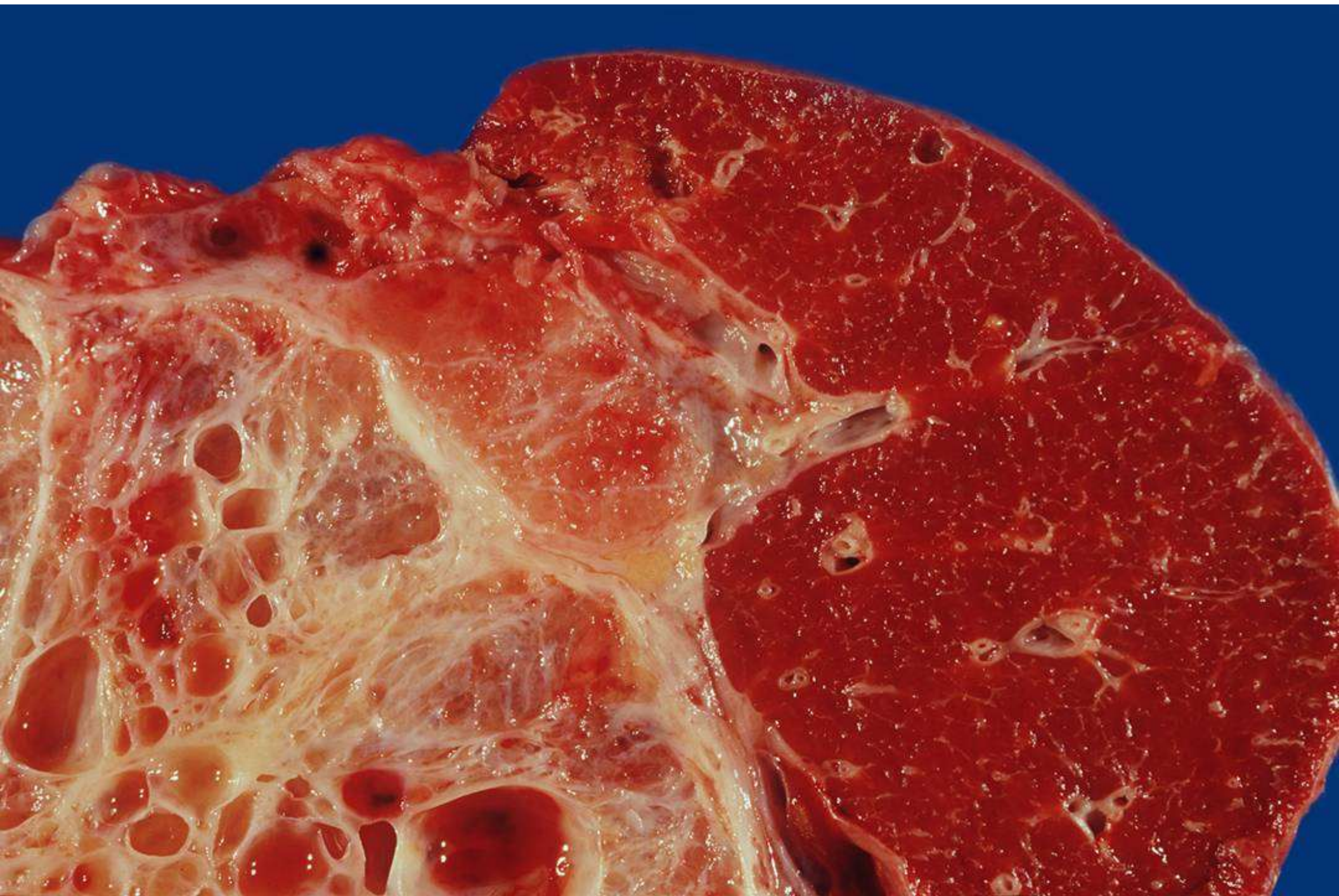
1 cm

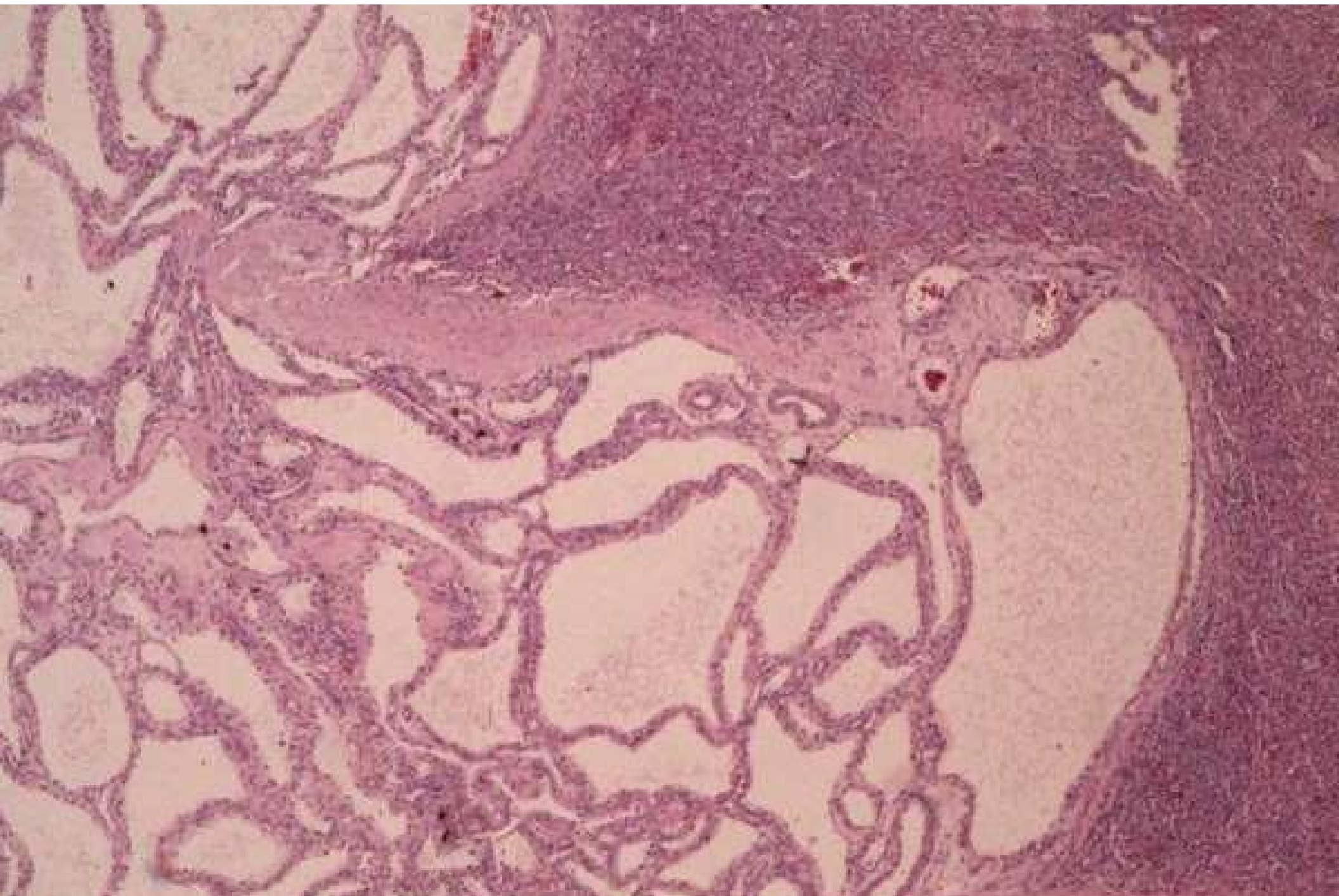
Mixed Serous-
Endocrine
Neoplasm- Think
of VHL



Serous Cystadenoma Outcome

- **Several case reports of “multifocal” disease**
- **One or two cases of malignant serous neoplasms**
- **The vast majority of serous cystadenomas are benign, even if incompletely resected**





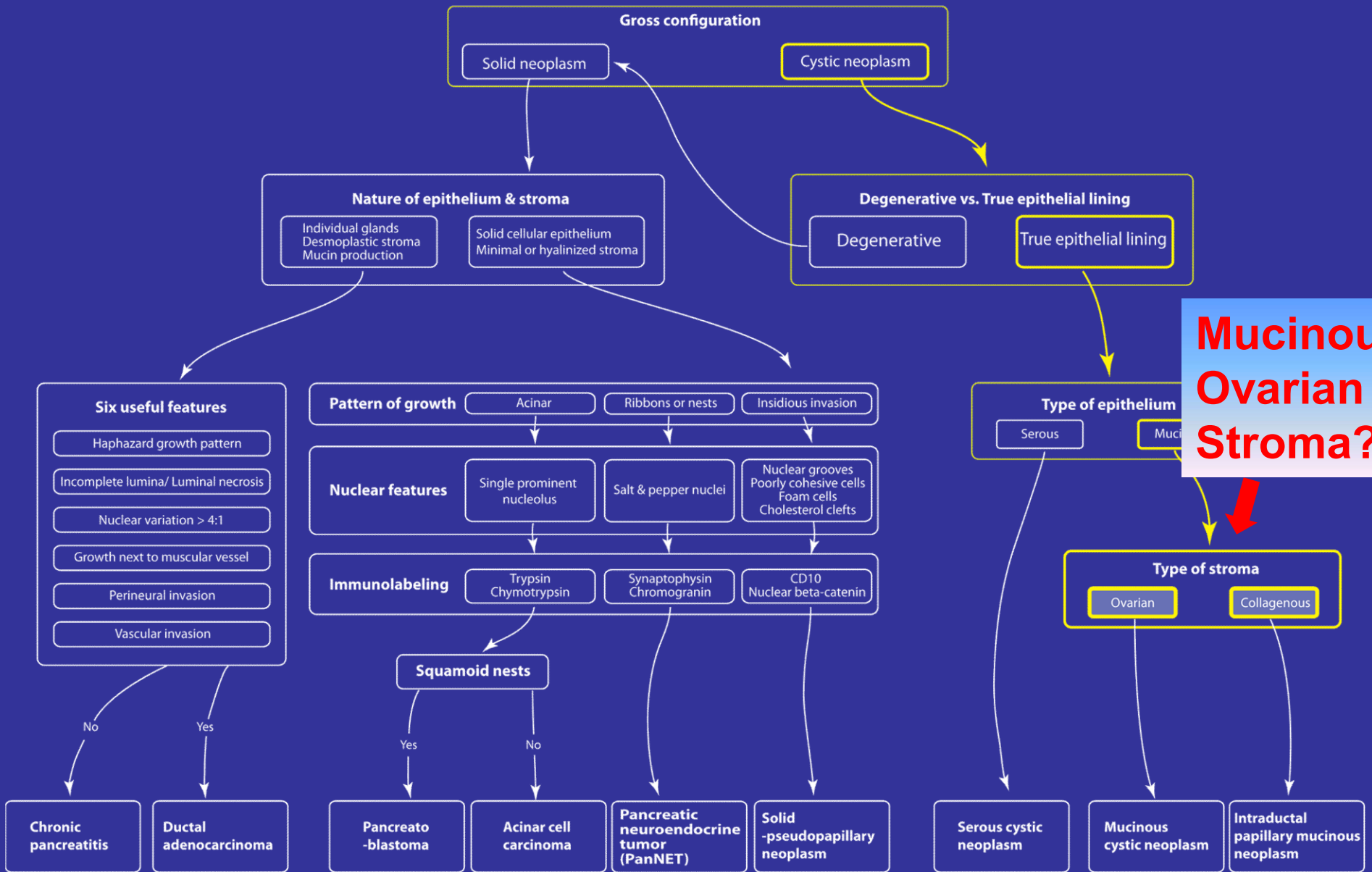
Serous Cystadenoma

Differential Diagnosis

| | <u>Serous cystadenoma</u> | <u>Lymphangioma</u> |
|--|---------------------------|---------------------|
|--|---------------------------|---------------------|

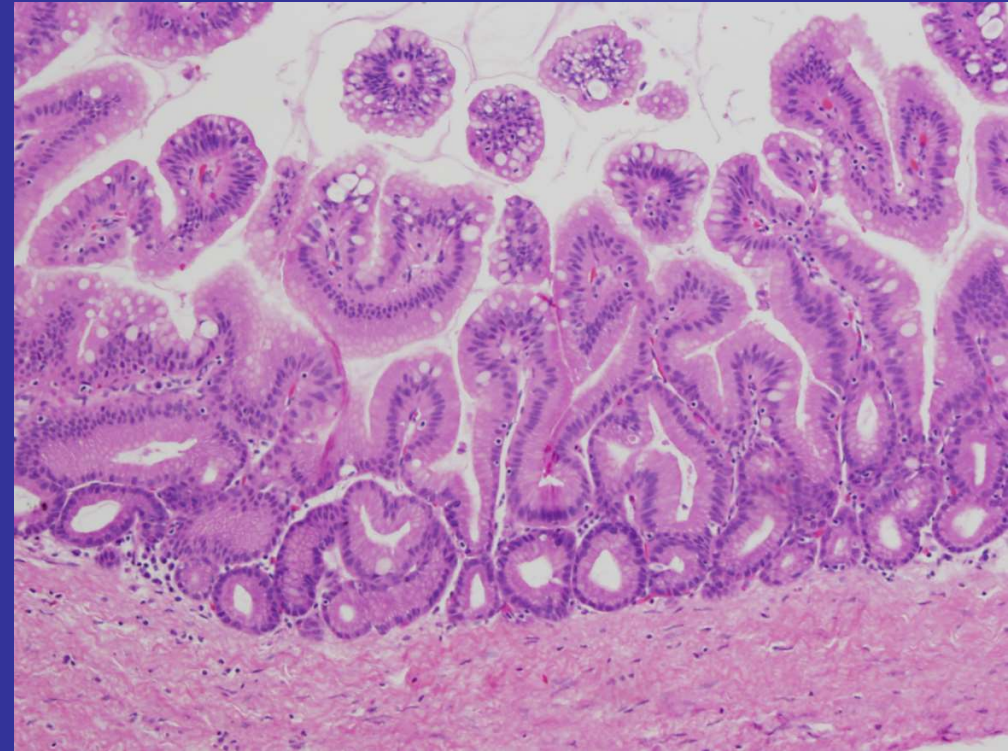
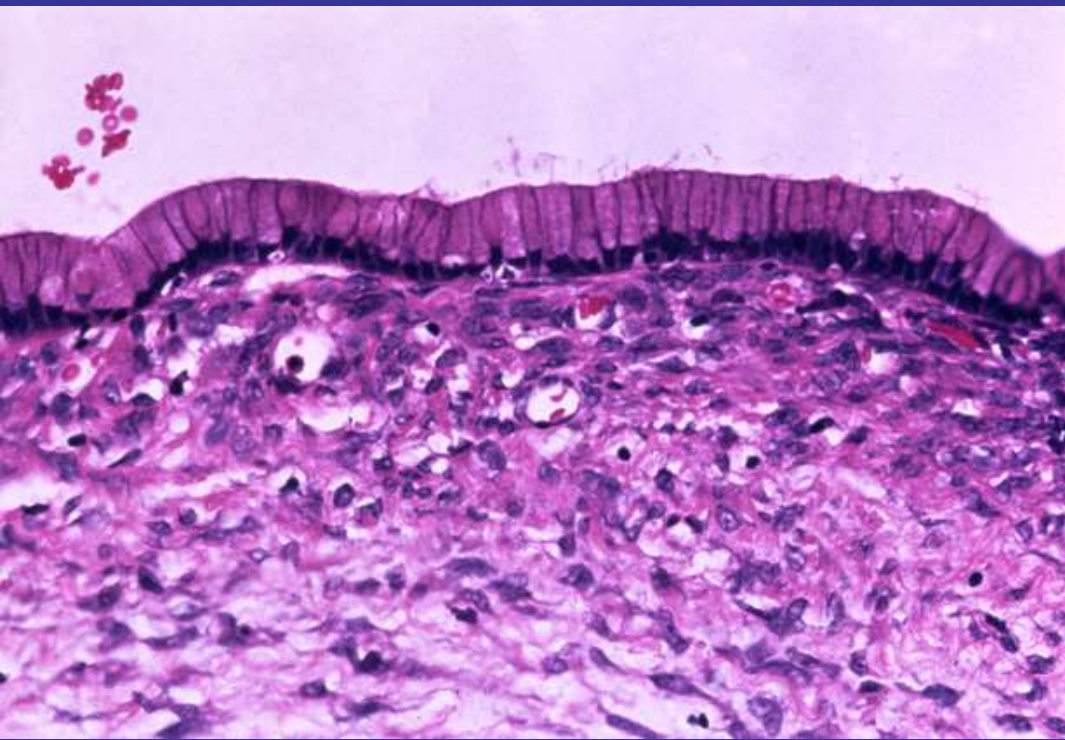
| | | |
|----------------------------|---|---|
| Cytokeratin | + | - |
| Glycogen | + | - |
| Lymphocytes in the wall | - | + |

**Mucin-producing
Neoplasms
(MCNs and IPMNs)**



Based on AFIP Fascicle, 4th Edition

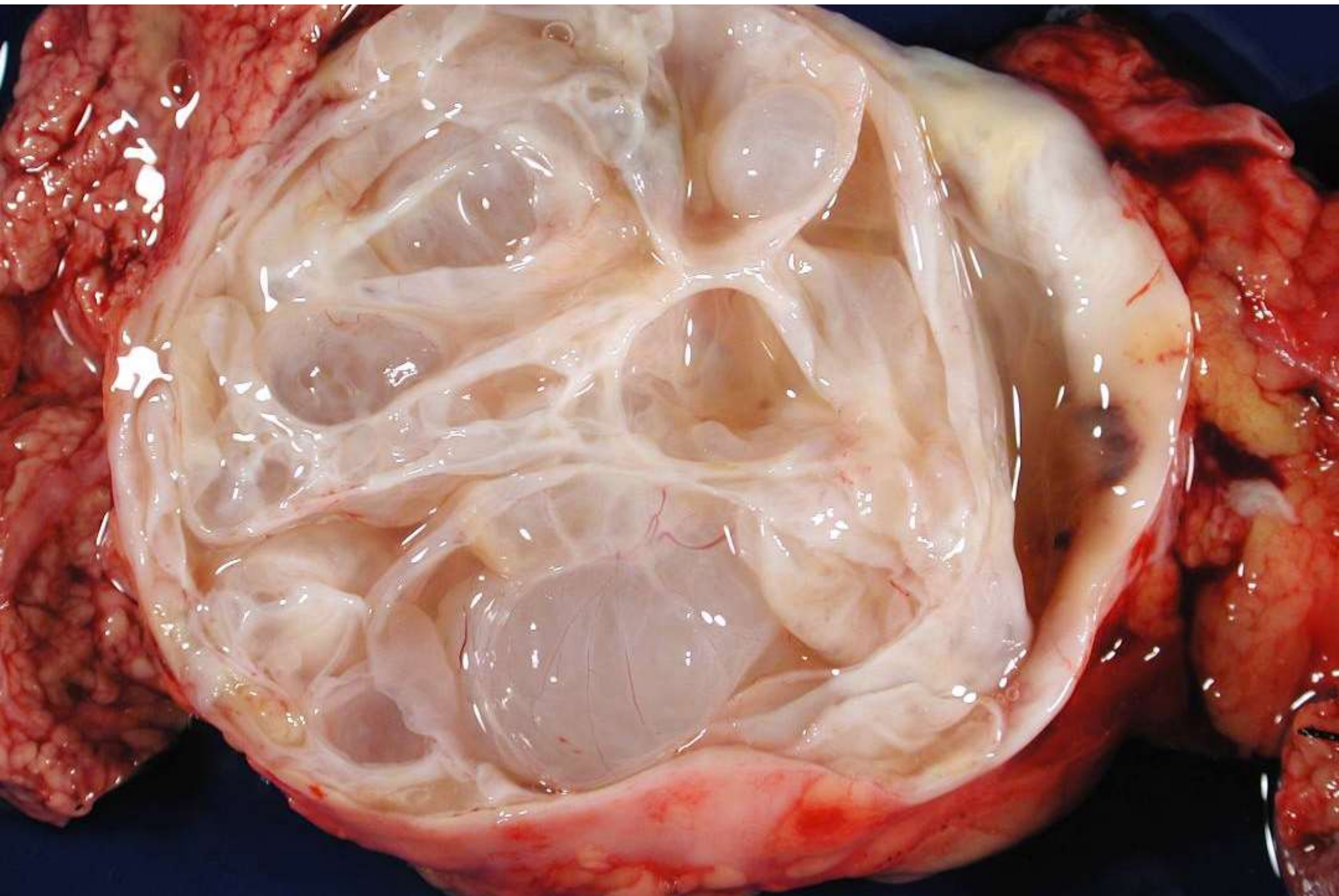
Nature of the Stroma: Ovarian vs. Collagenous

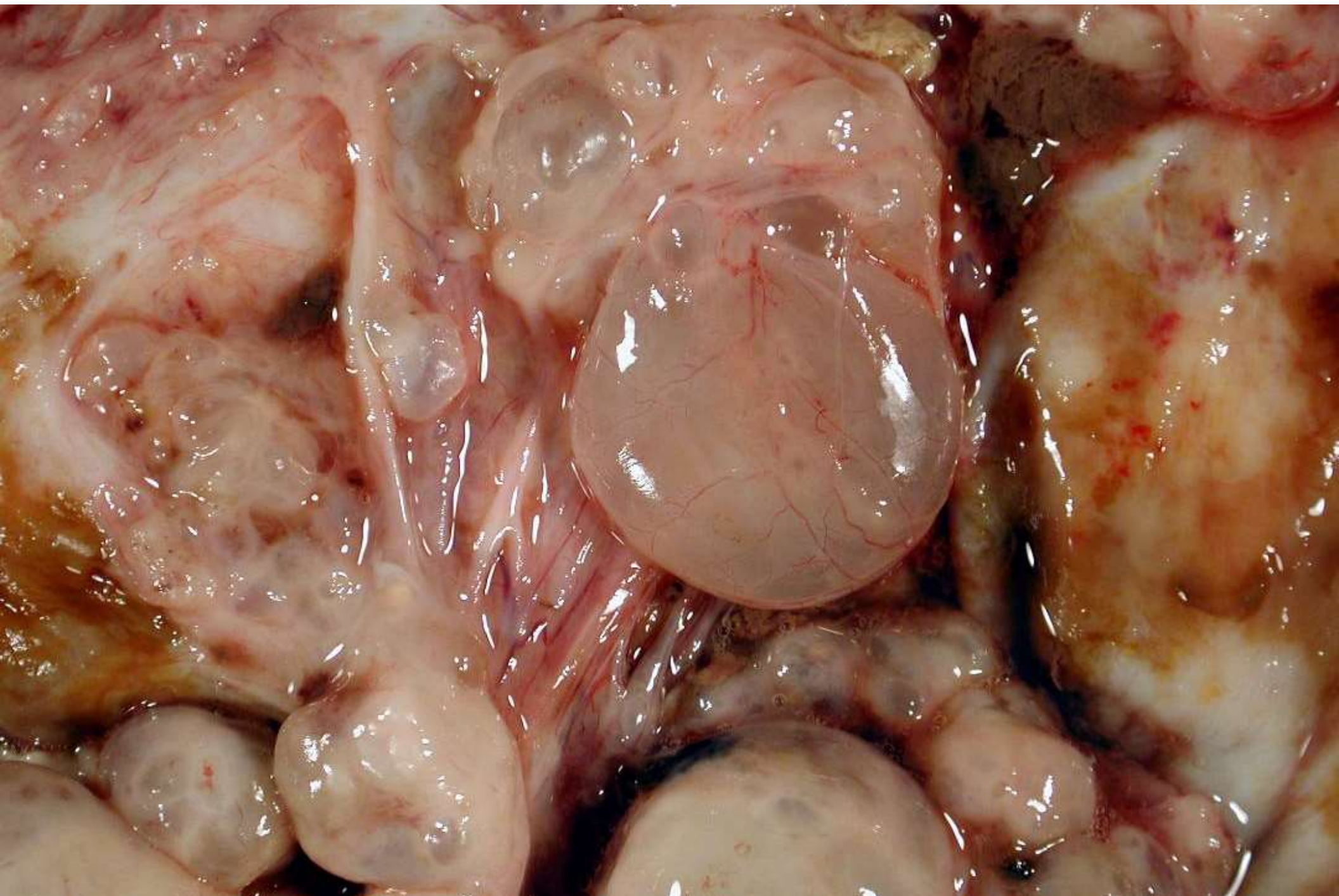


Mucinous Cystic Neoplasms

Mucinous Cystic Neoplasms

- Much more common in women than in men
- Mean age at diagnosis: ~50 (younger than for patients with serous cystadenomas)
- Tail > Head

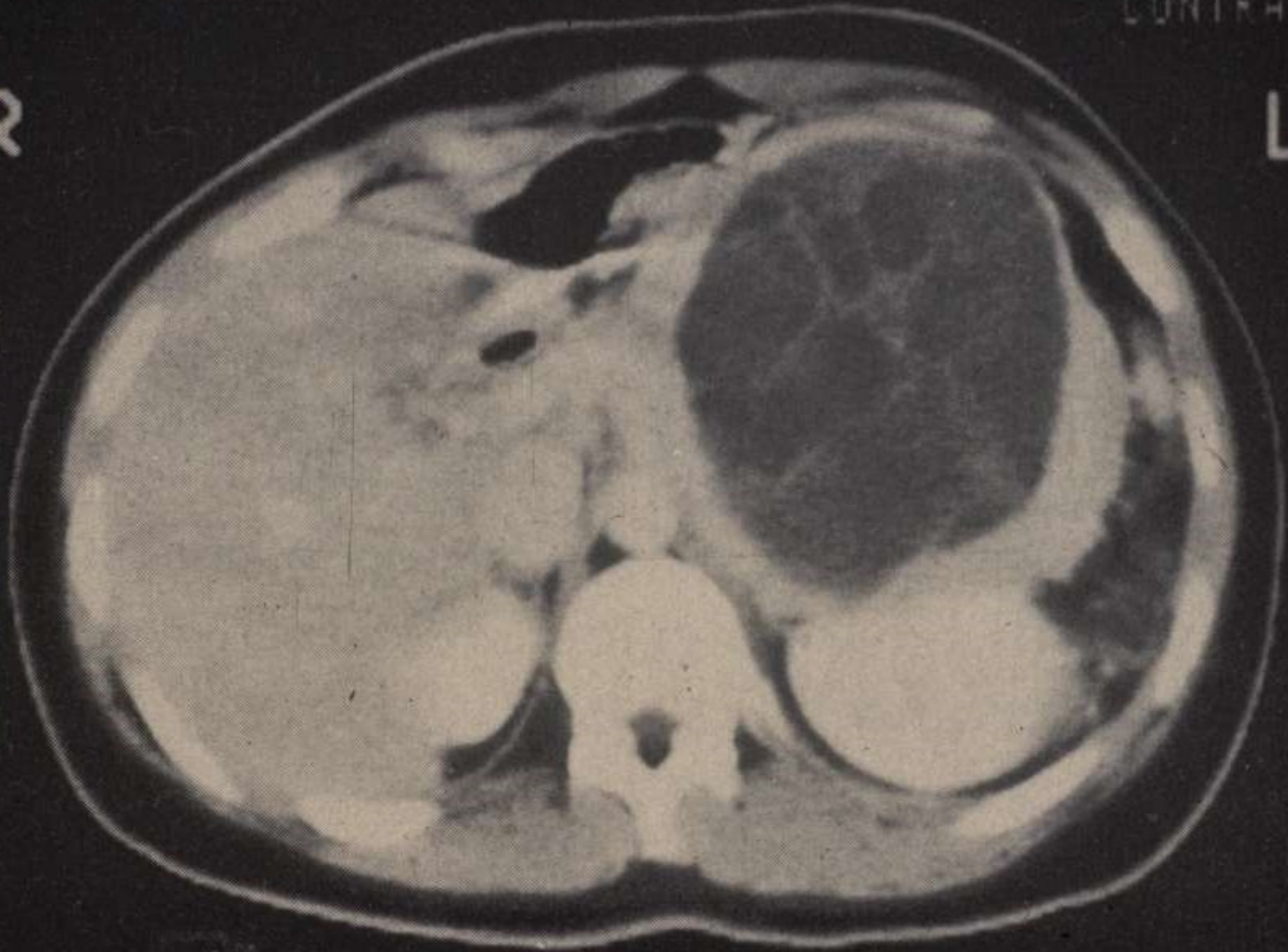

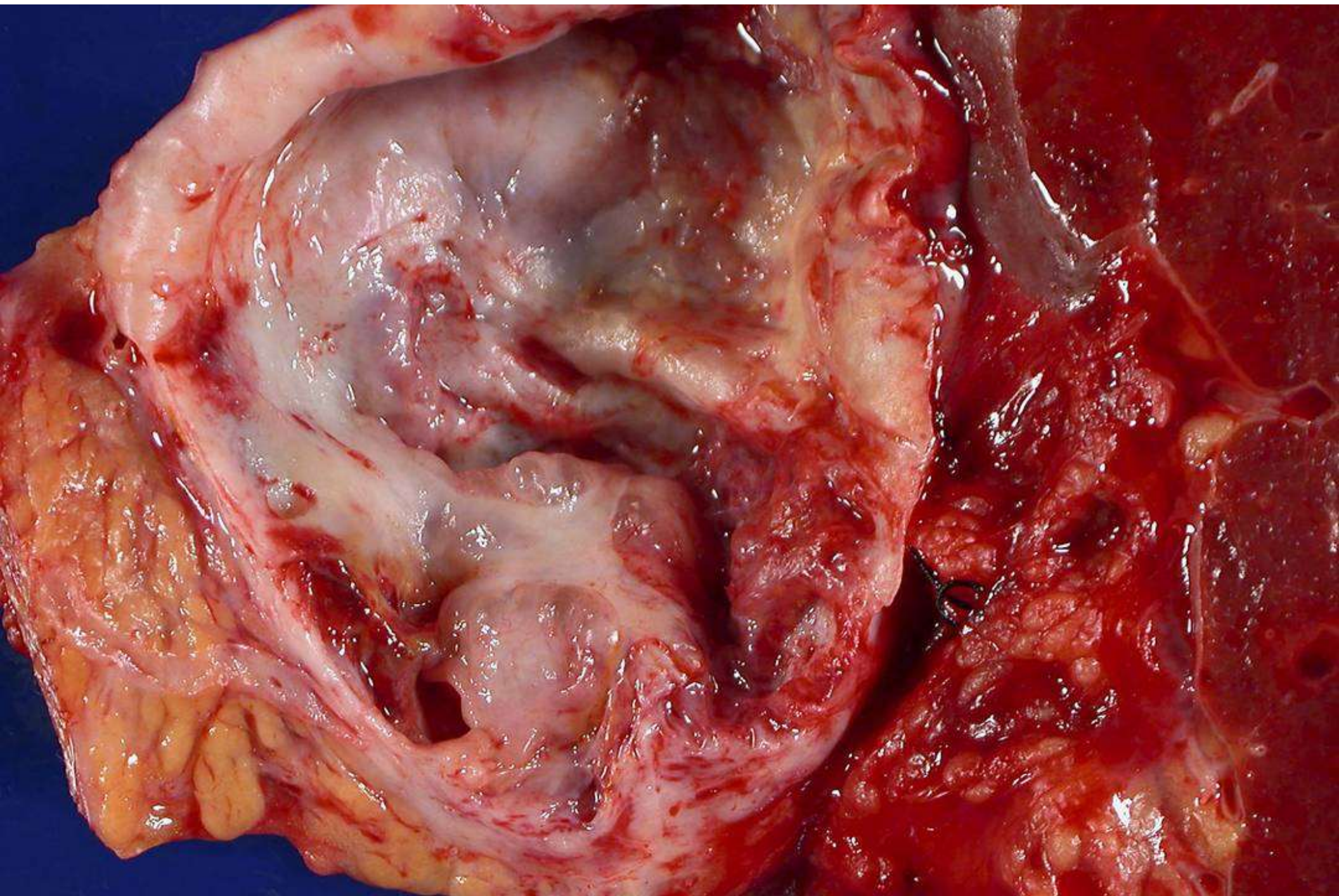


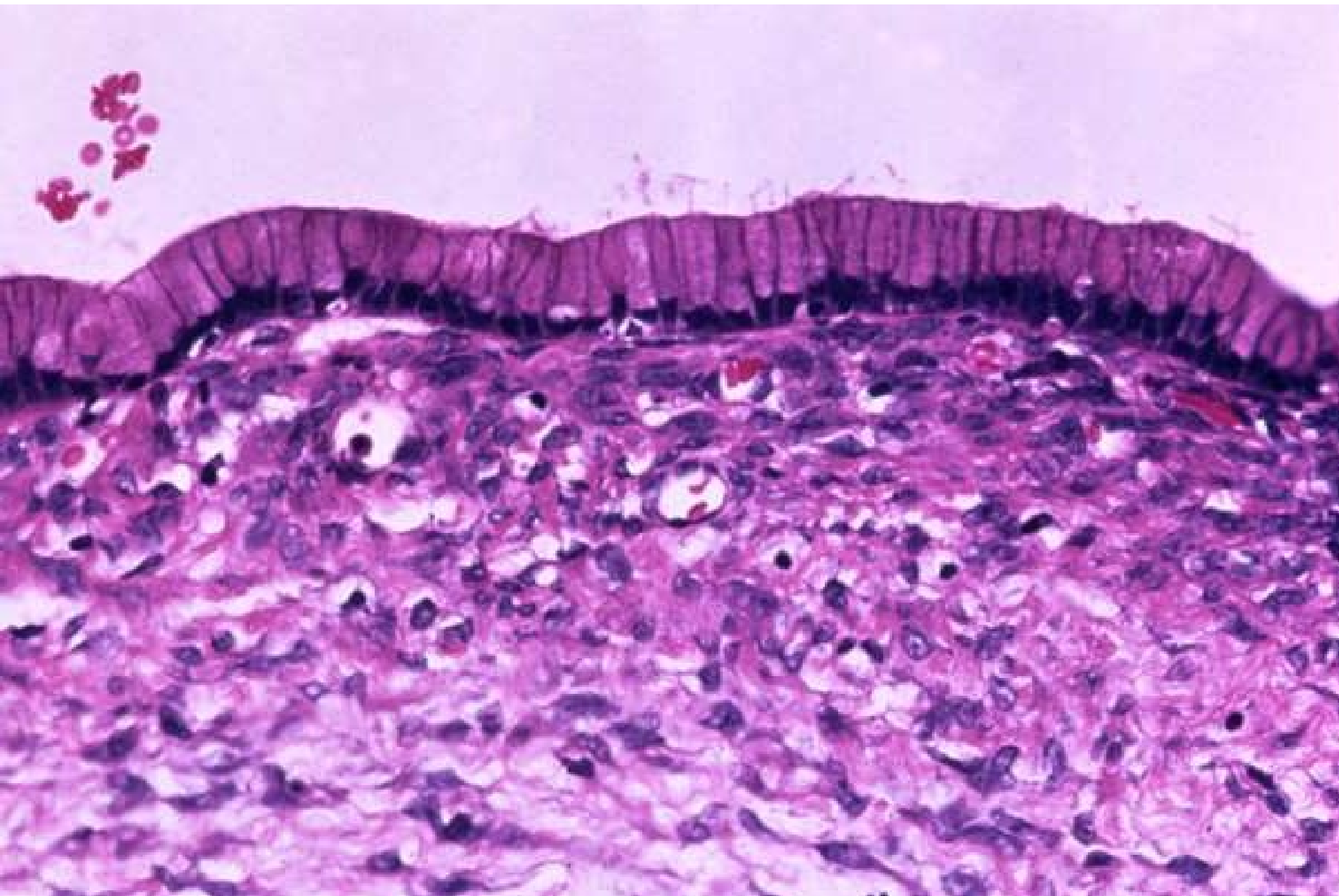
CONTRAST

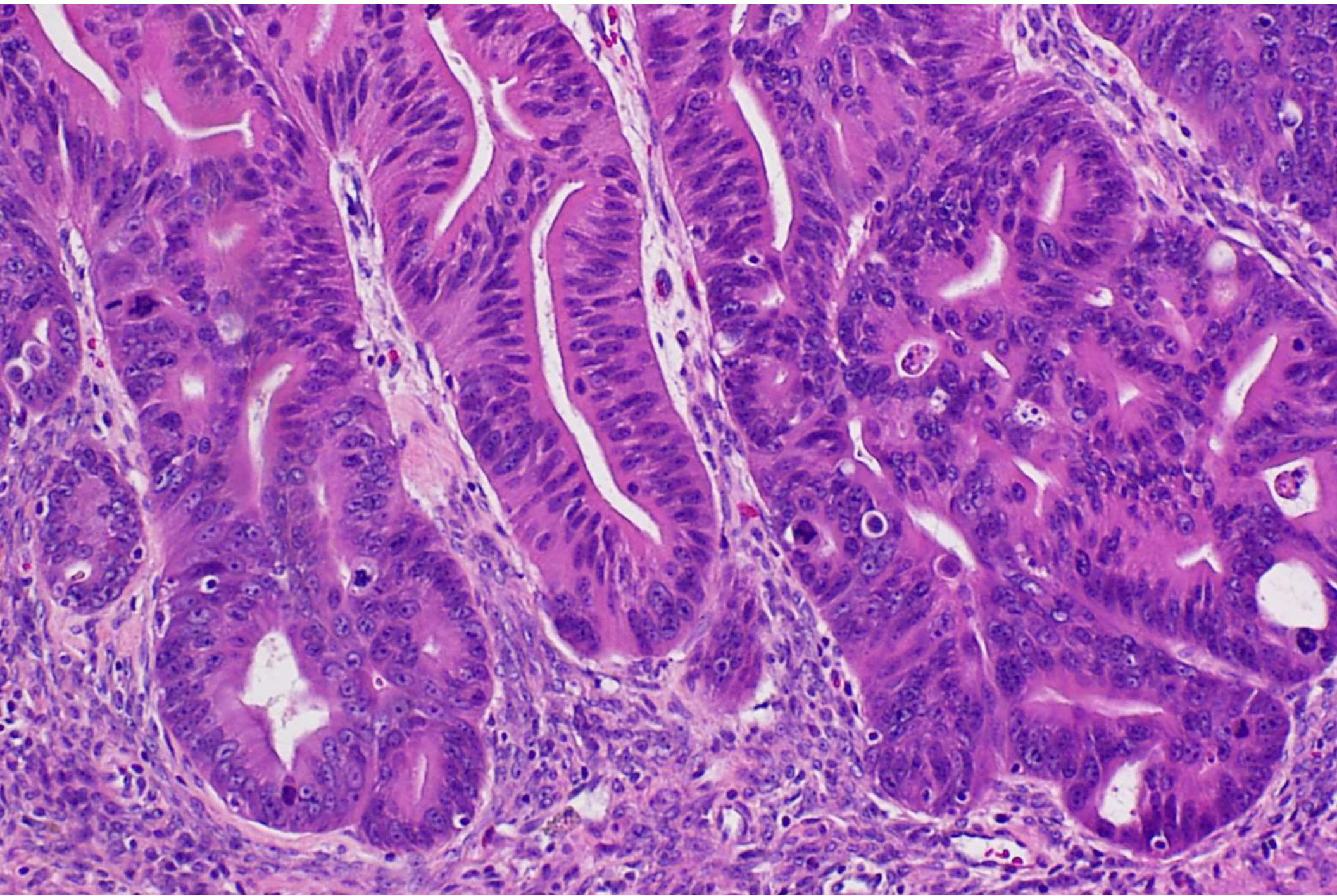
R

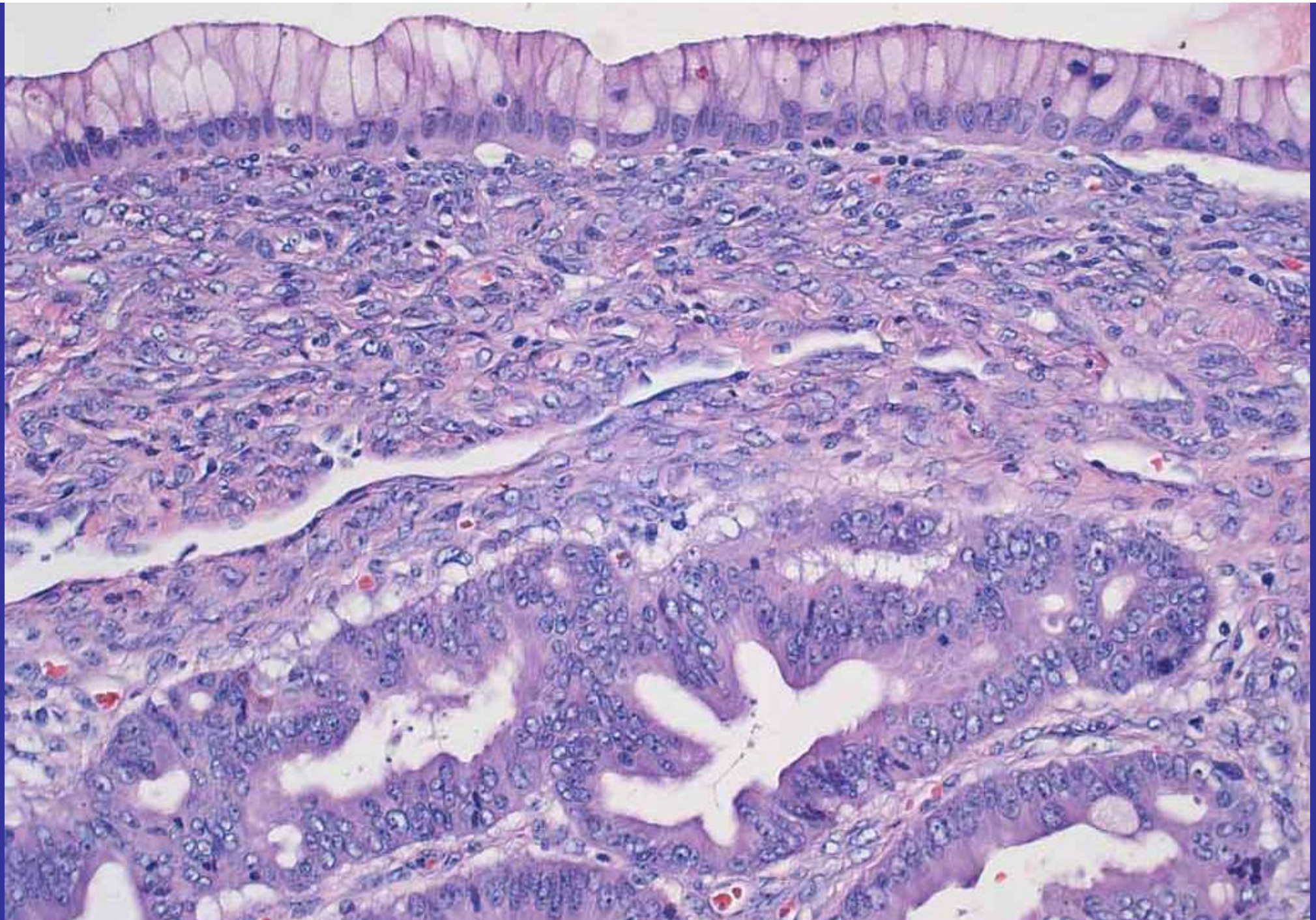
L

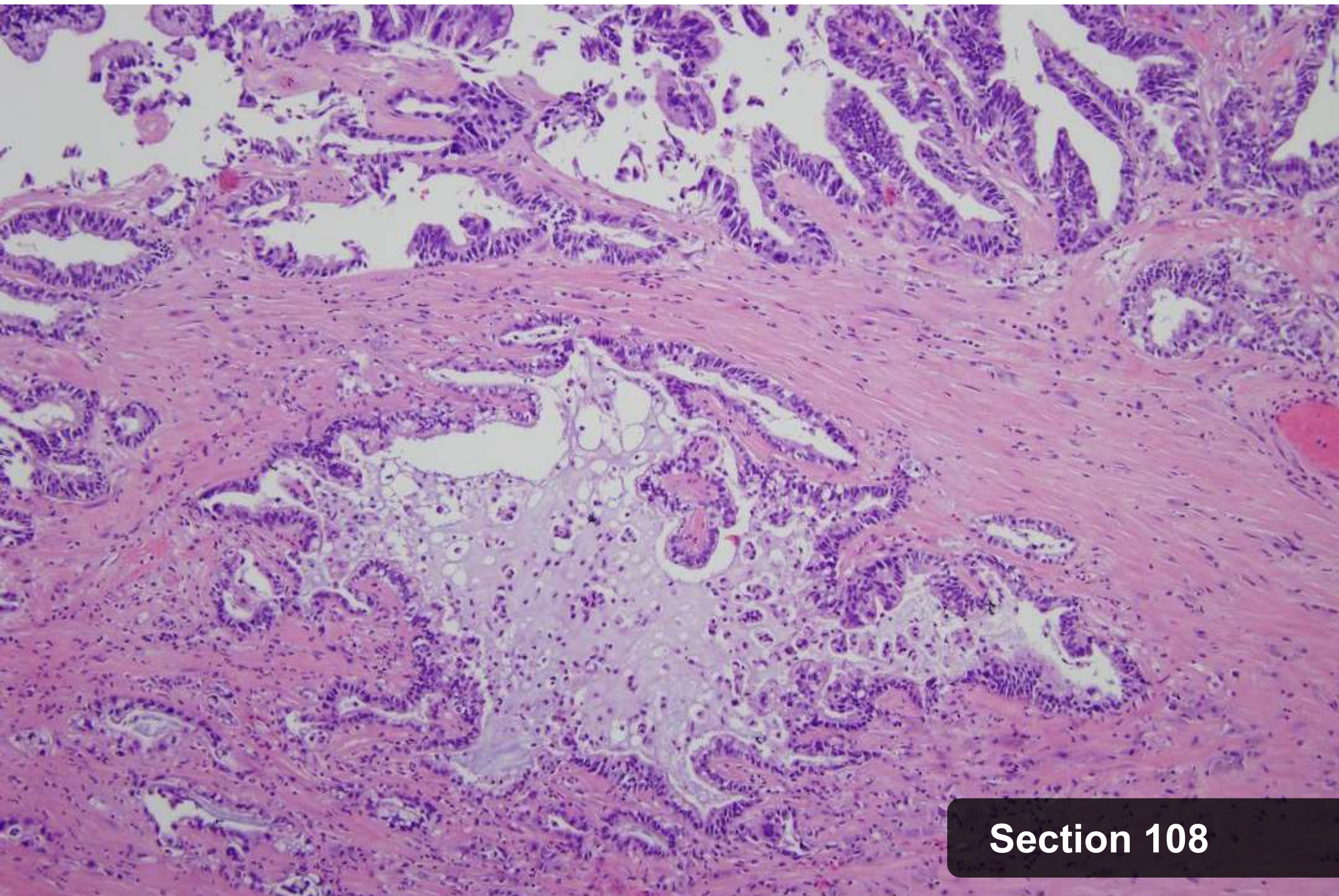












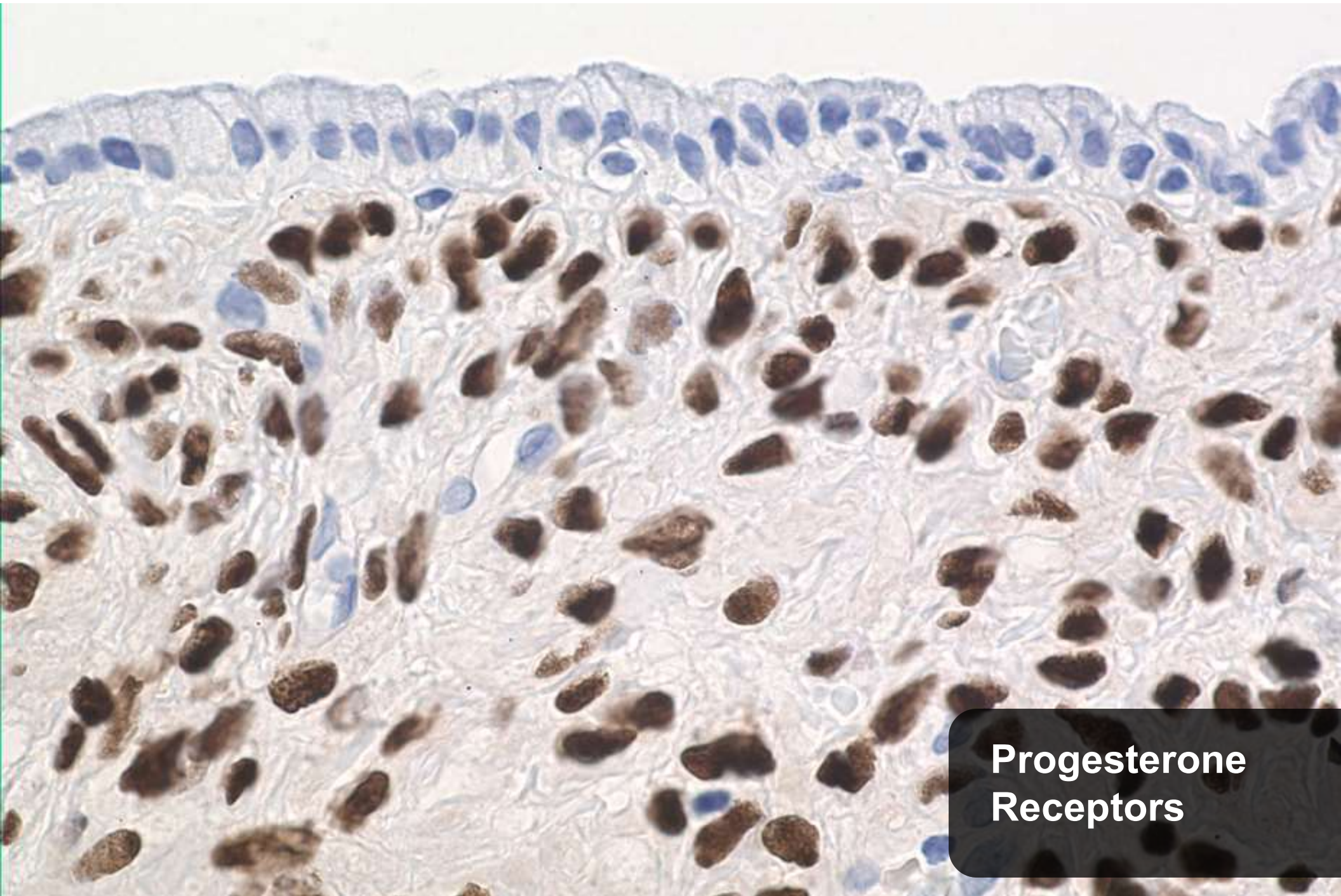
Section 108

Mucinous Cystic Neoplasms

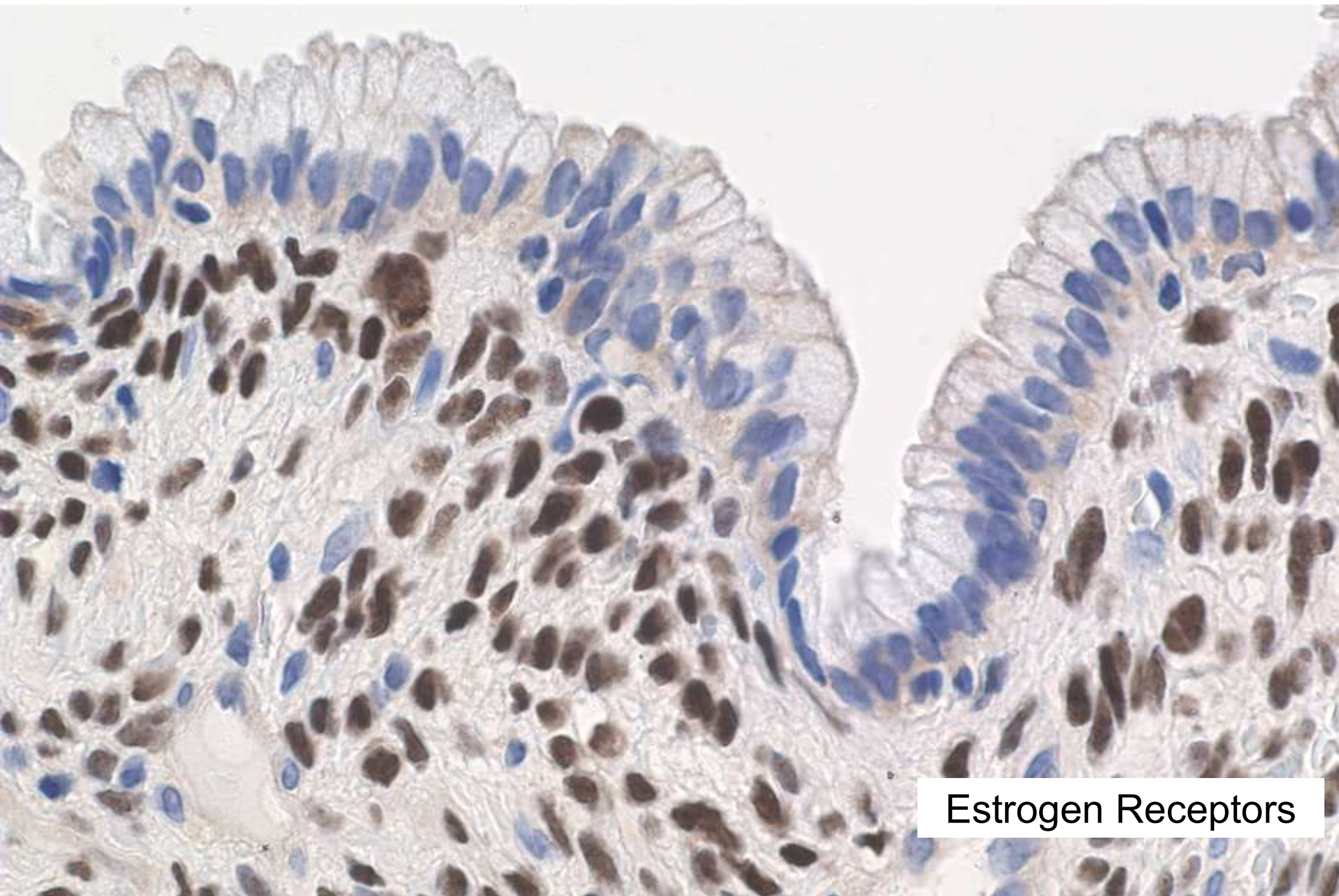
- Low-grade Dysplasia
 - Intermediate grade Dysplasia
 - High-grade Dysplasia
-
- Invasive Carcinoma

Mucinous Cystic Neoplasms- Proposed

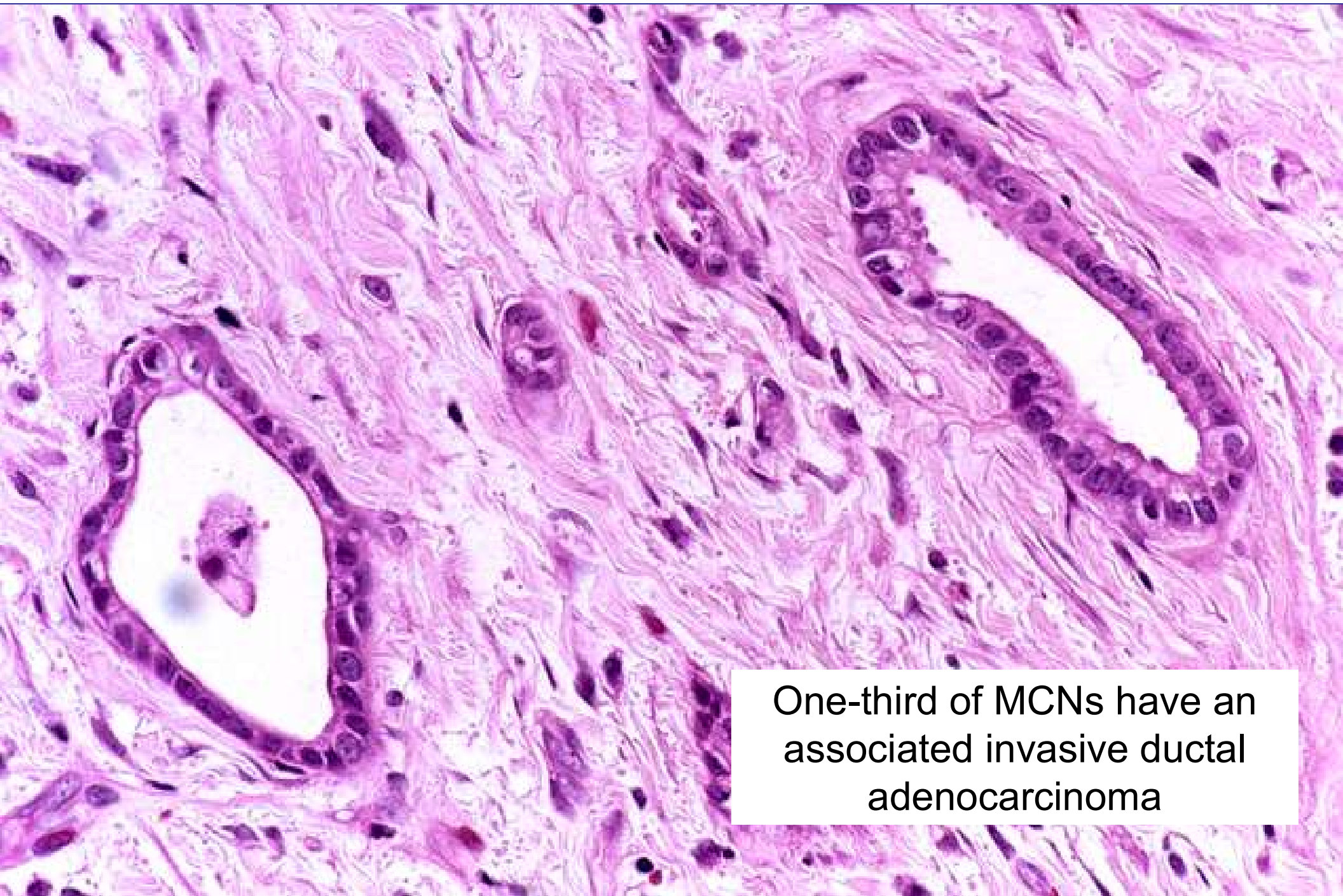
- Low-grade Dysplasia
 - High-grade Dysplasia
-
- Invasive Carcinoma



**Progesterone
Receptors**

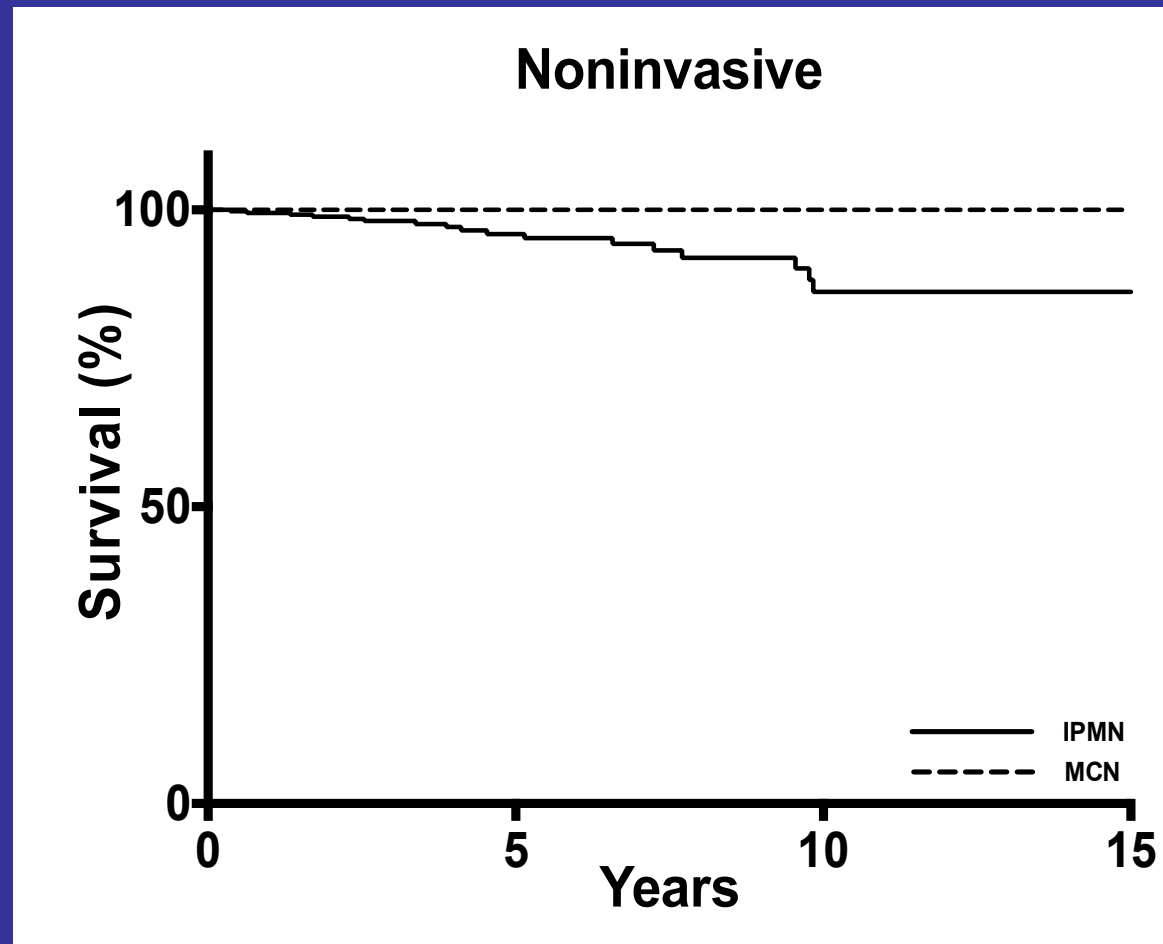


Estrogen Receptors



One-third of MCNs have an associated invasive ductal adenocarcinoma

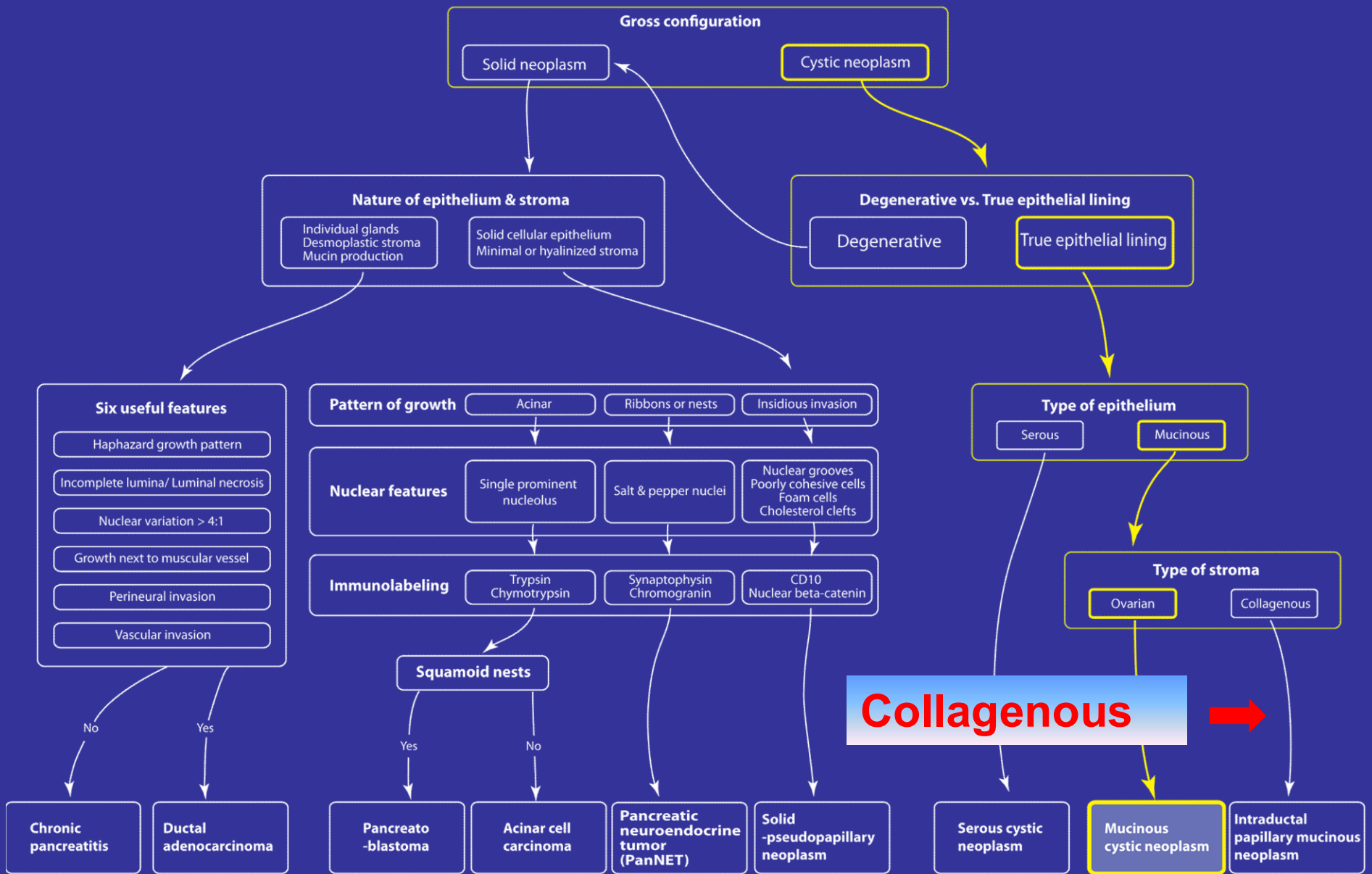
MCNs are Unifocal



A. Pea, Annals of

**Completely resected and
entirely examined
mucinous cystic neoplasms
without an associated
invasive carcinoma follow
benign courses.**

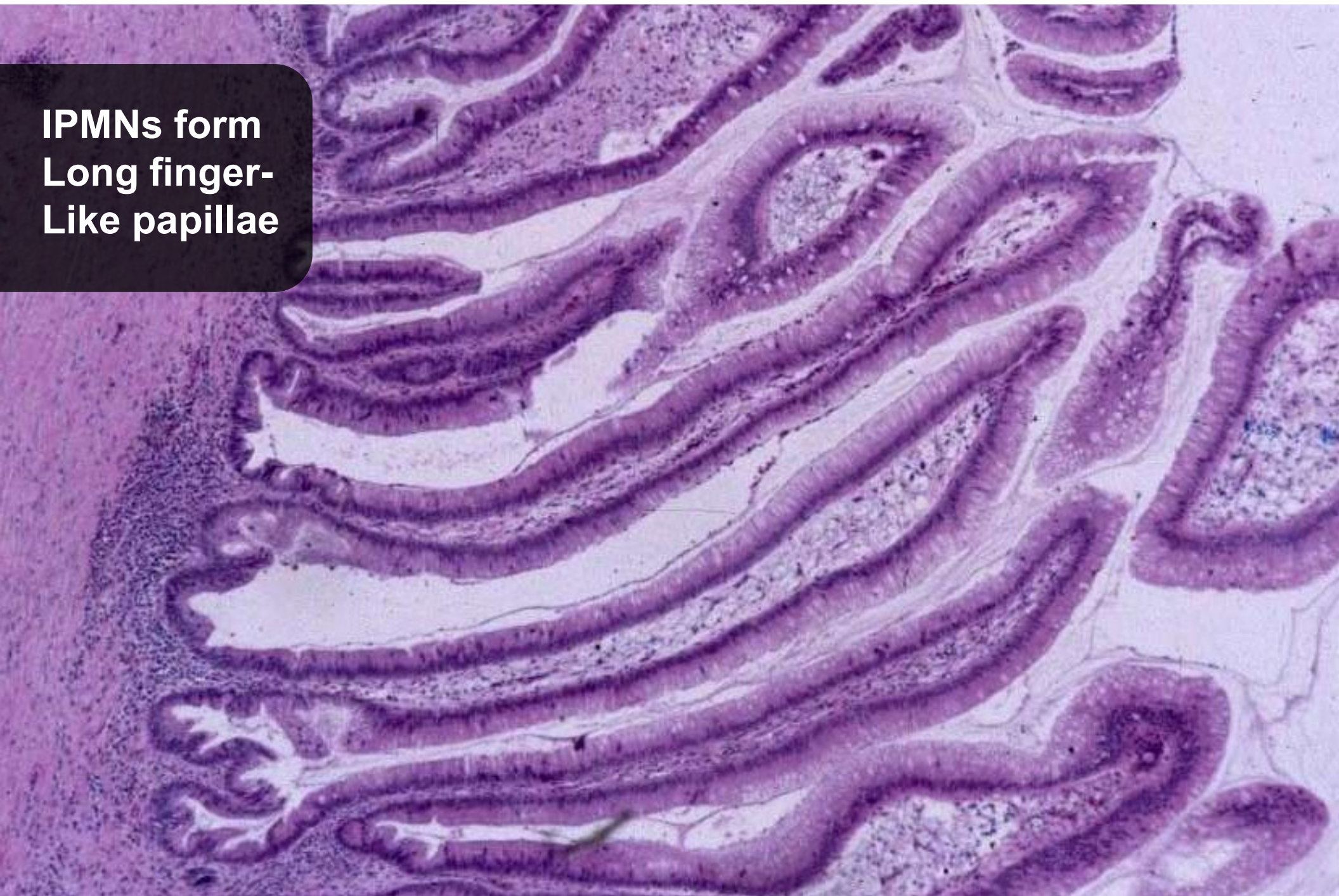
Because invasive carcinoma can be focal, failure to study an entire mucinous cystic neoplasm may result in the miscategorization of a malignant tumor as benign.



Based on AFIP Fascicle, 4th Edition

Intraductal Papillary Mucinous Neoplasm

**IPMNs form
Long finger-
Like papillae**



Intraductal Papillary Neoplasms

- Long history of symptoms
- Incidence in men equals that in women
- Head > Tail
- Mucin oozing from the ampulla of Vater

FOV 33.0cm
STND/P

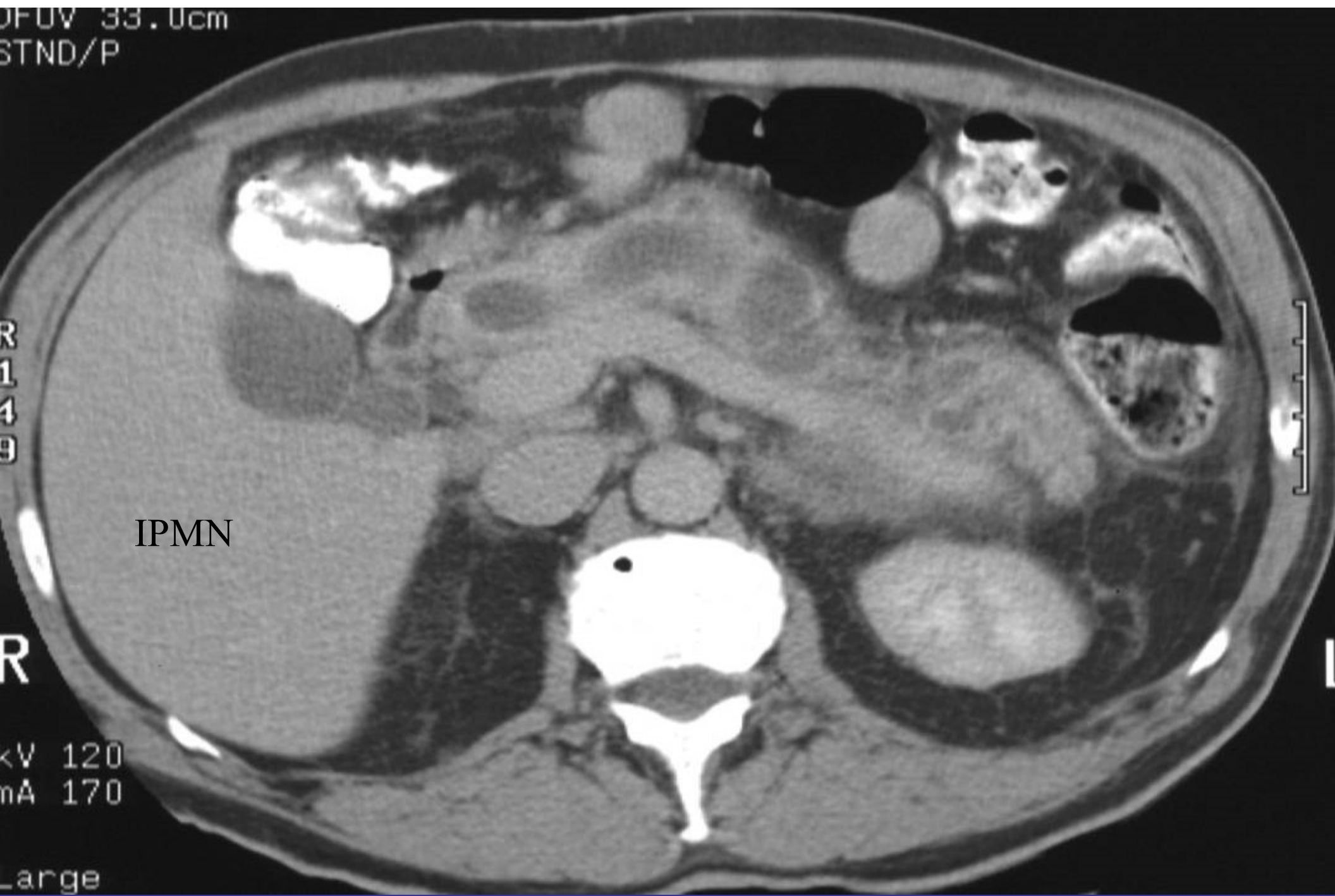R
1
4
9

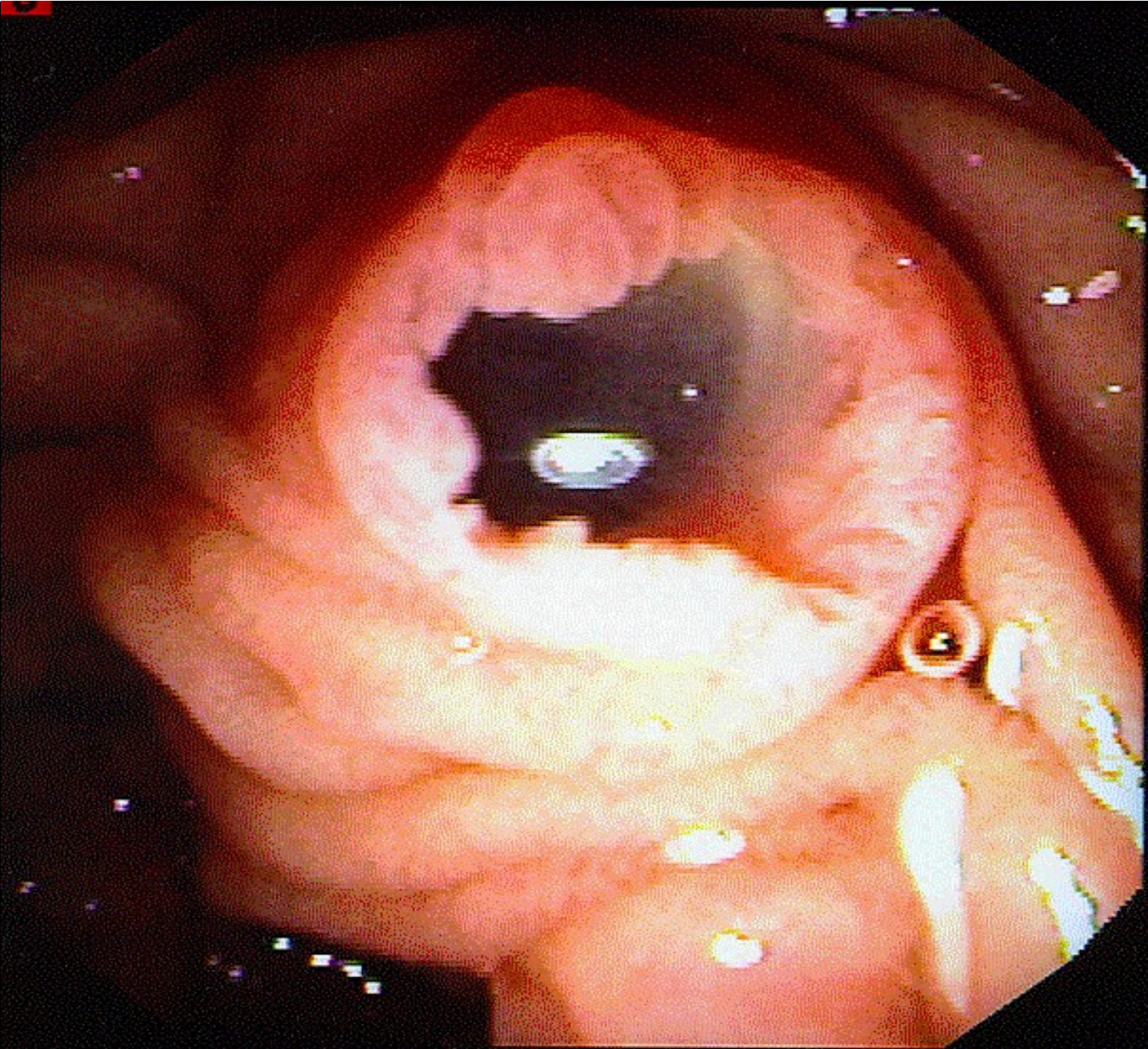
IPMN

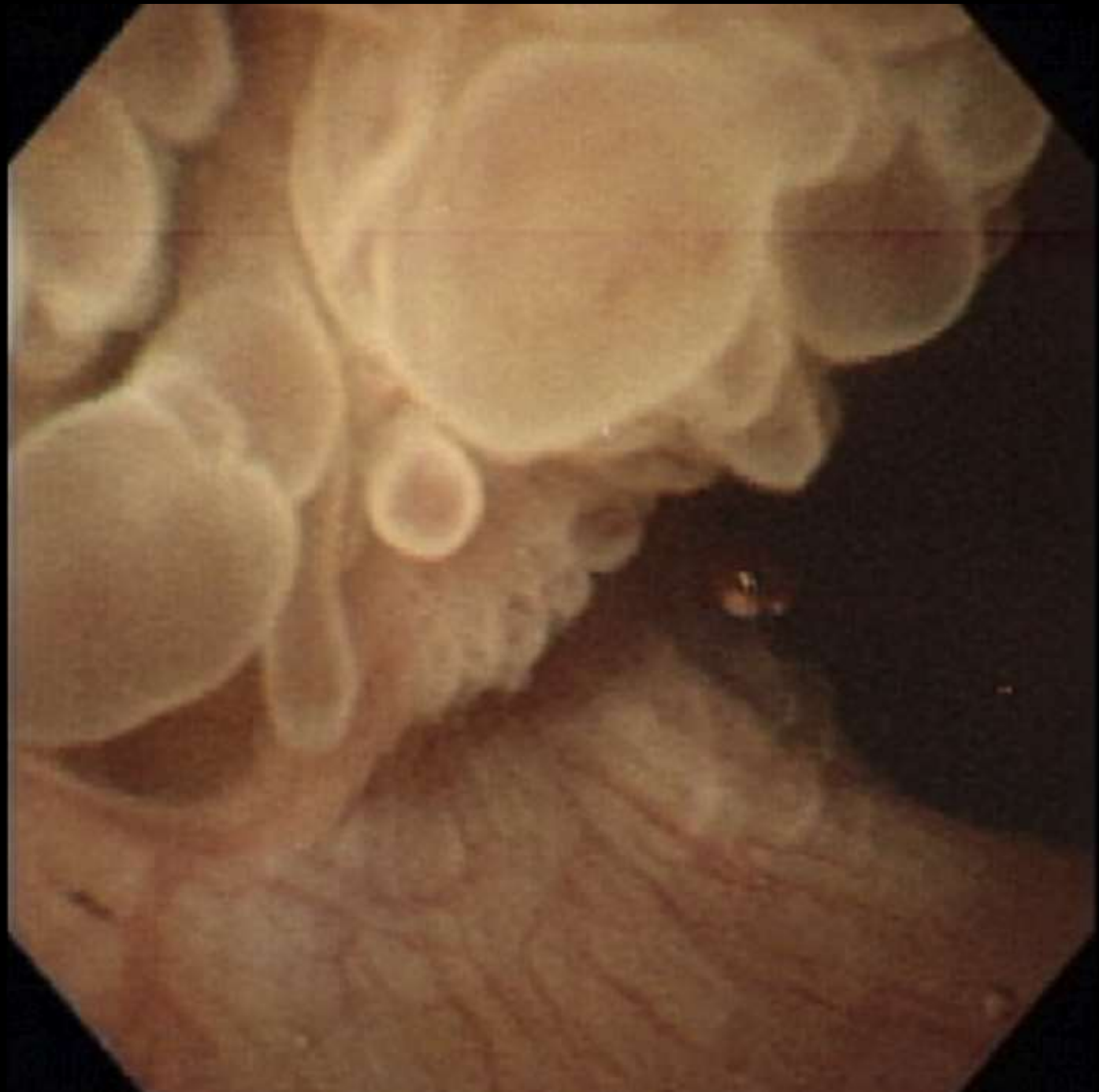
R

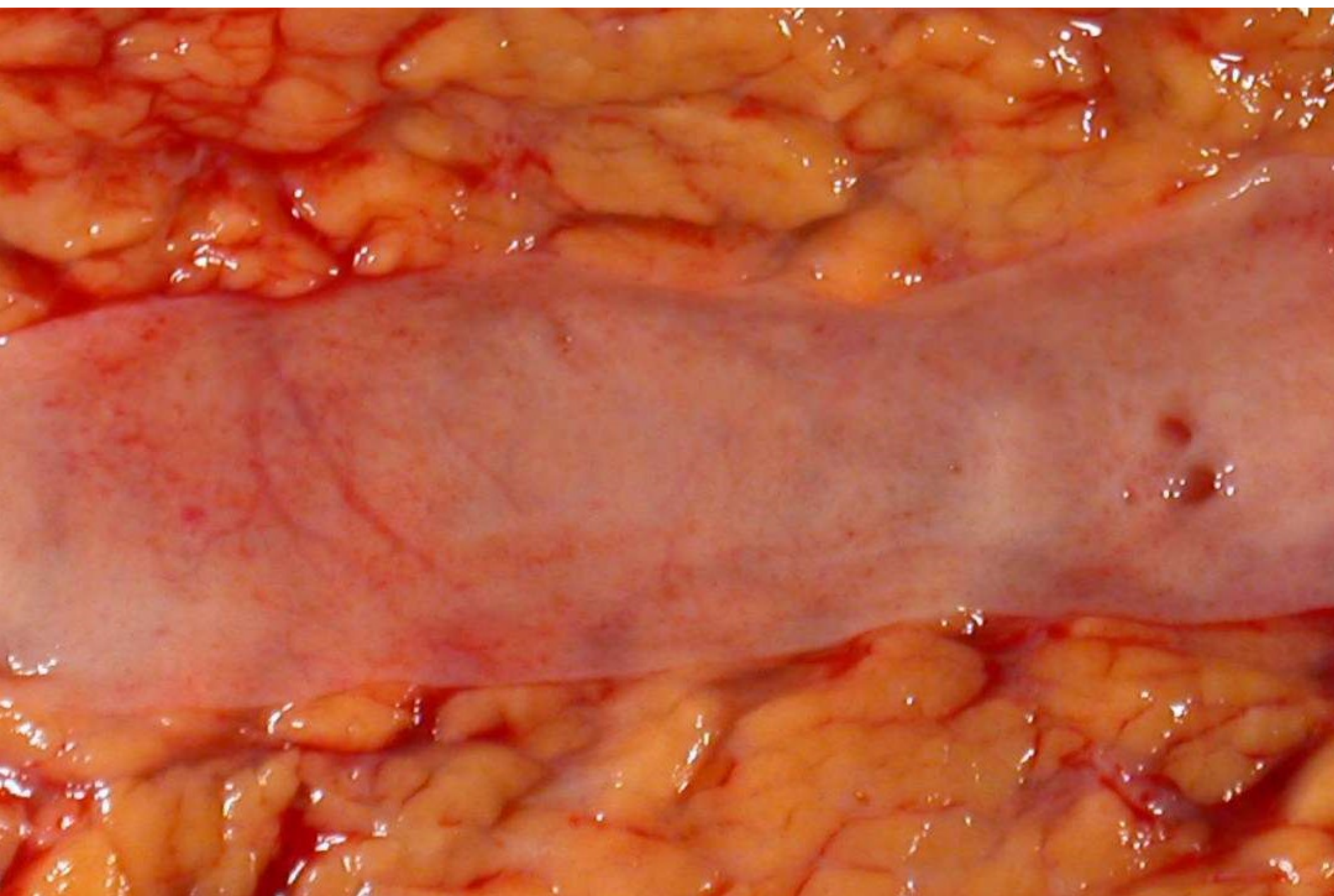
kV 120
mA 170

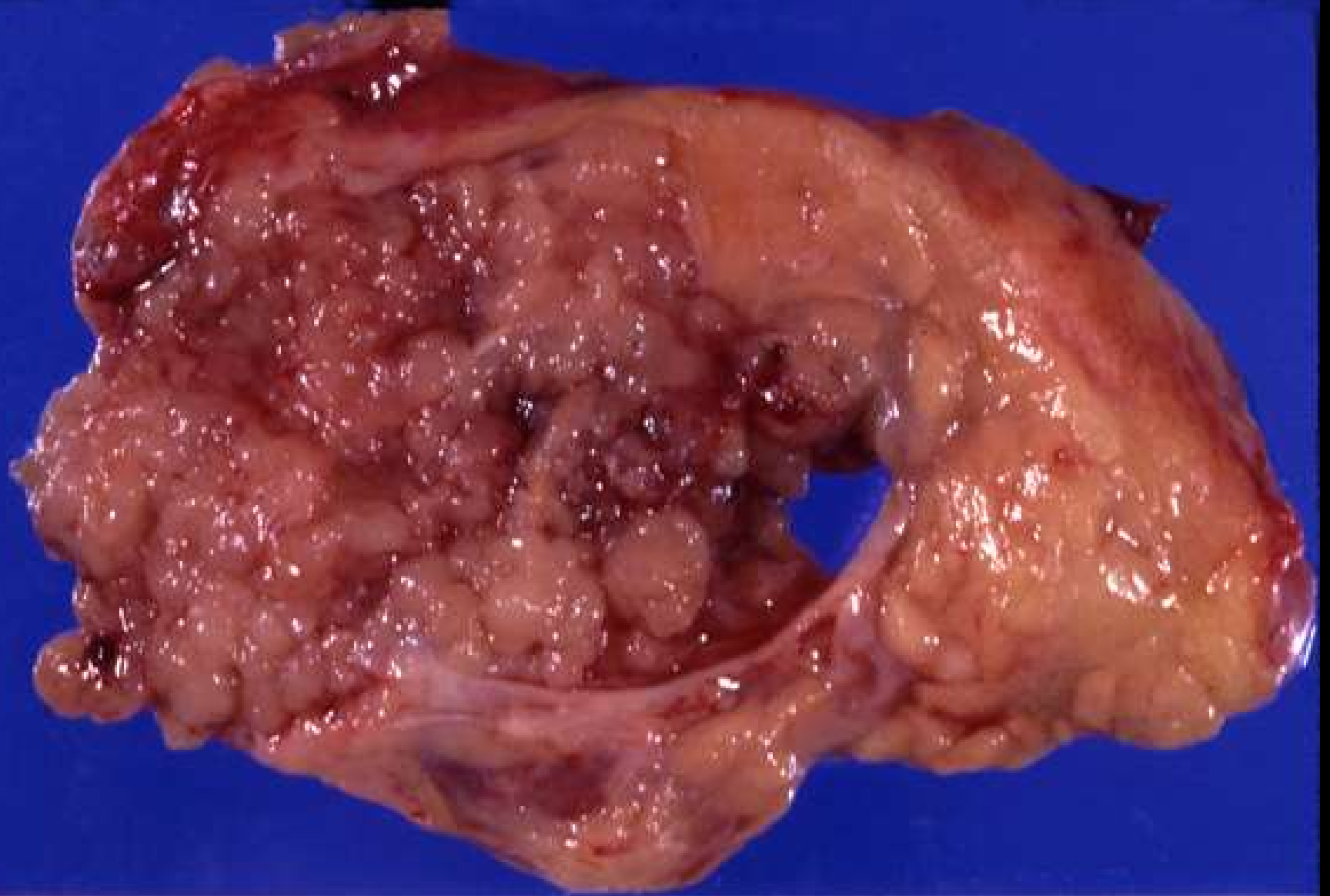
Large











cm

1

2

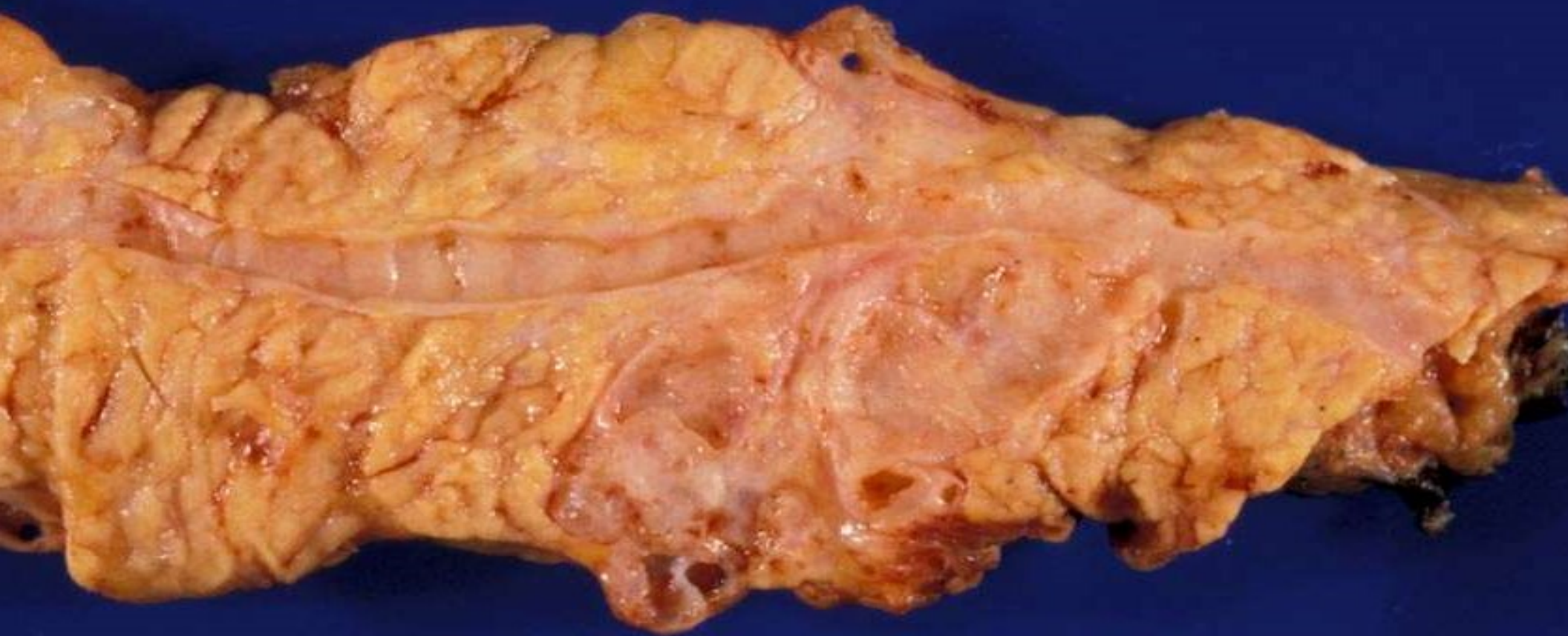3

4

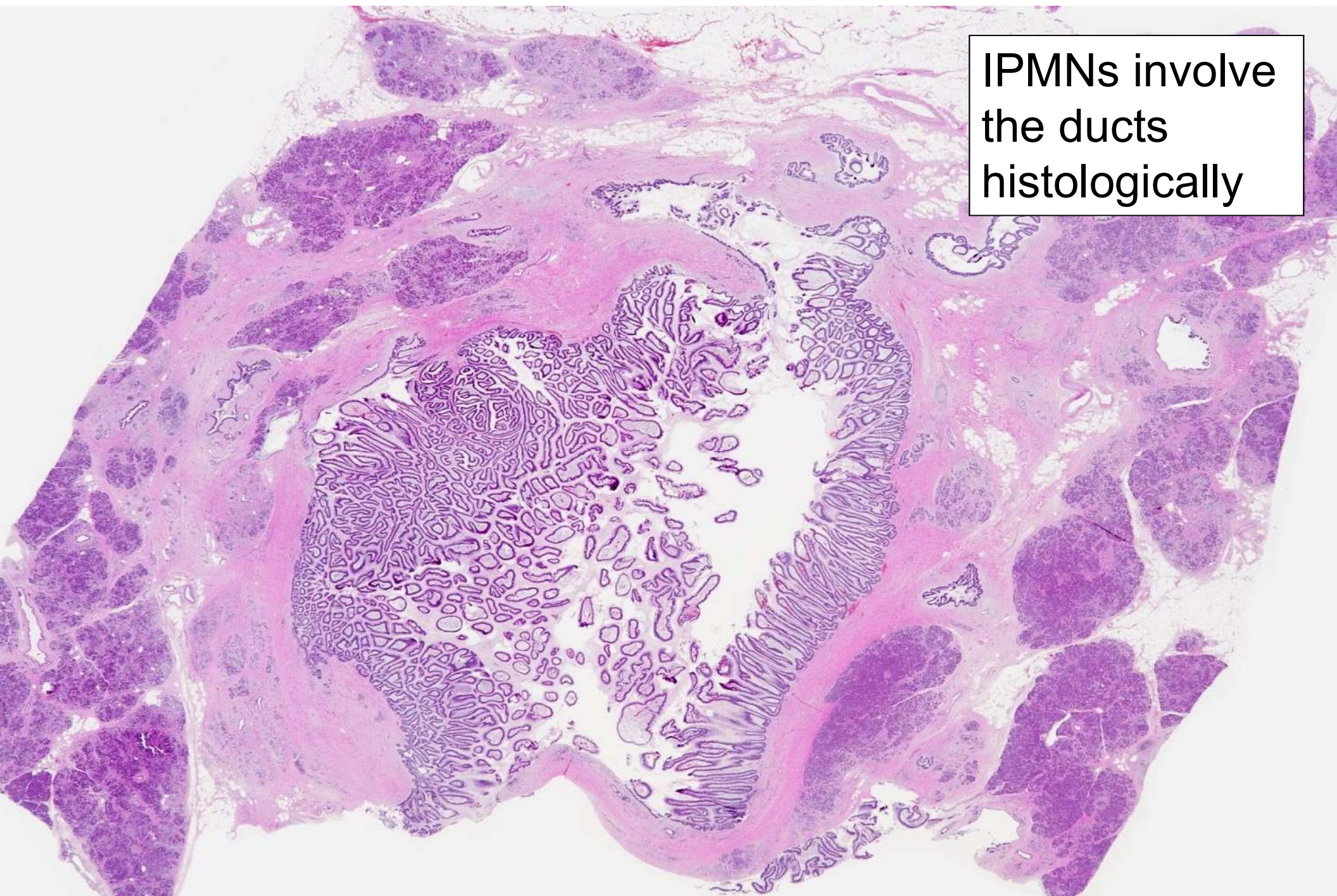
5

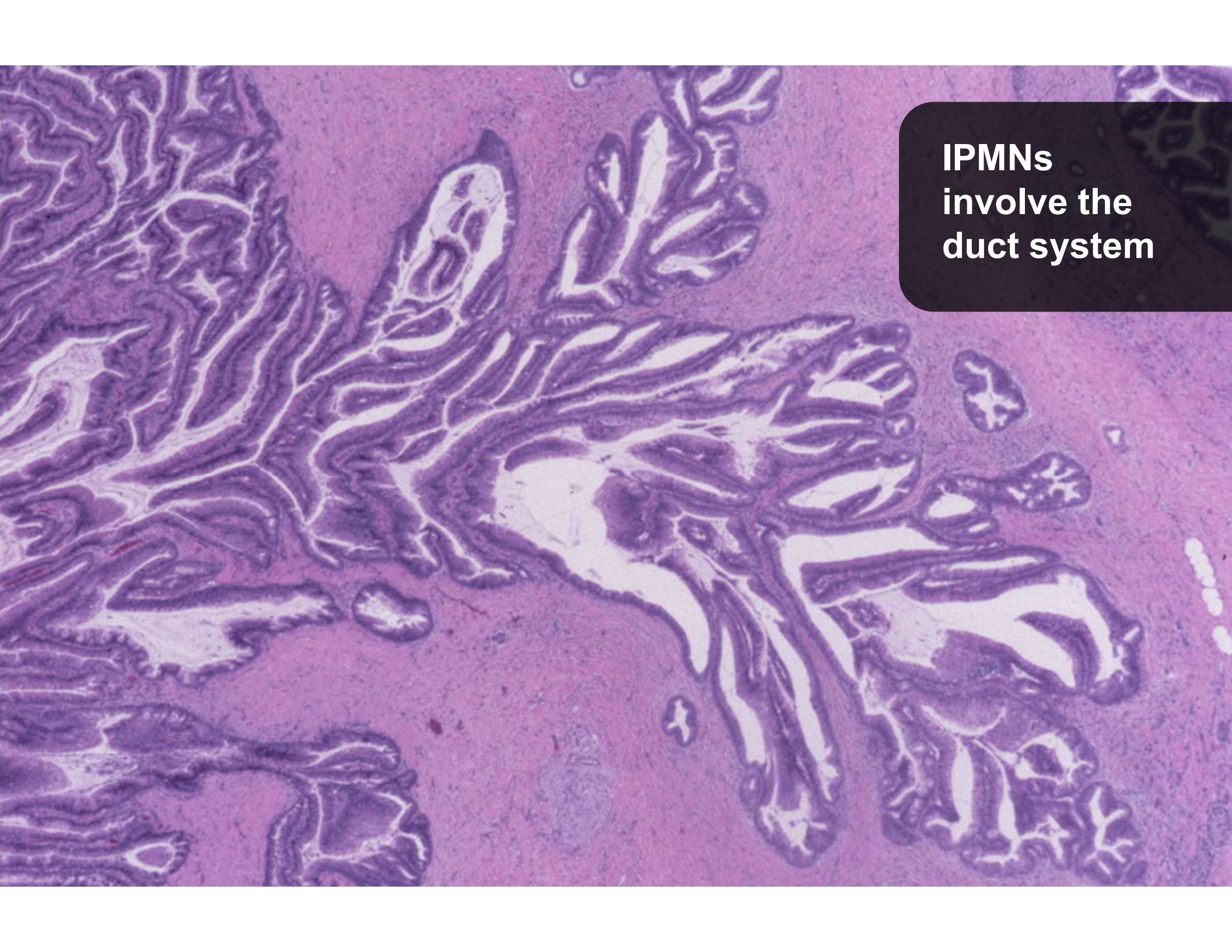
6

Branch Duct IPMN

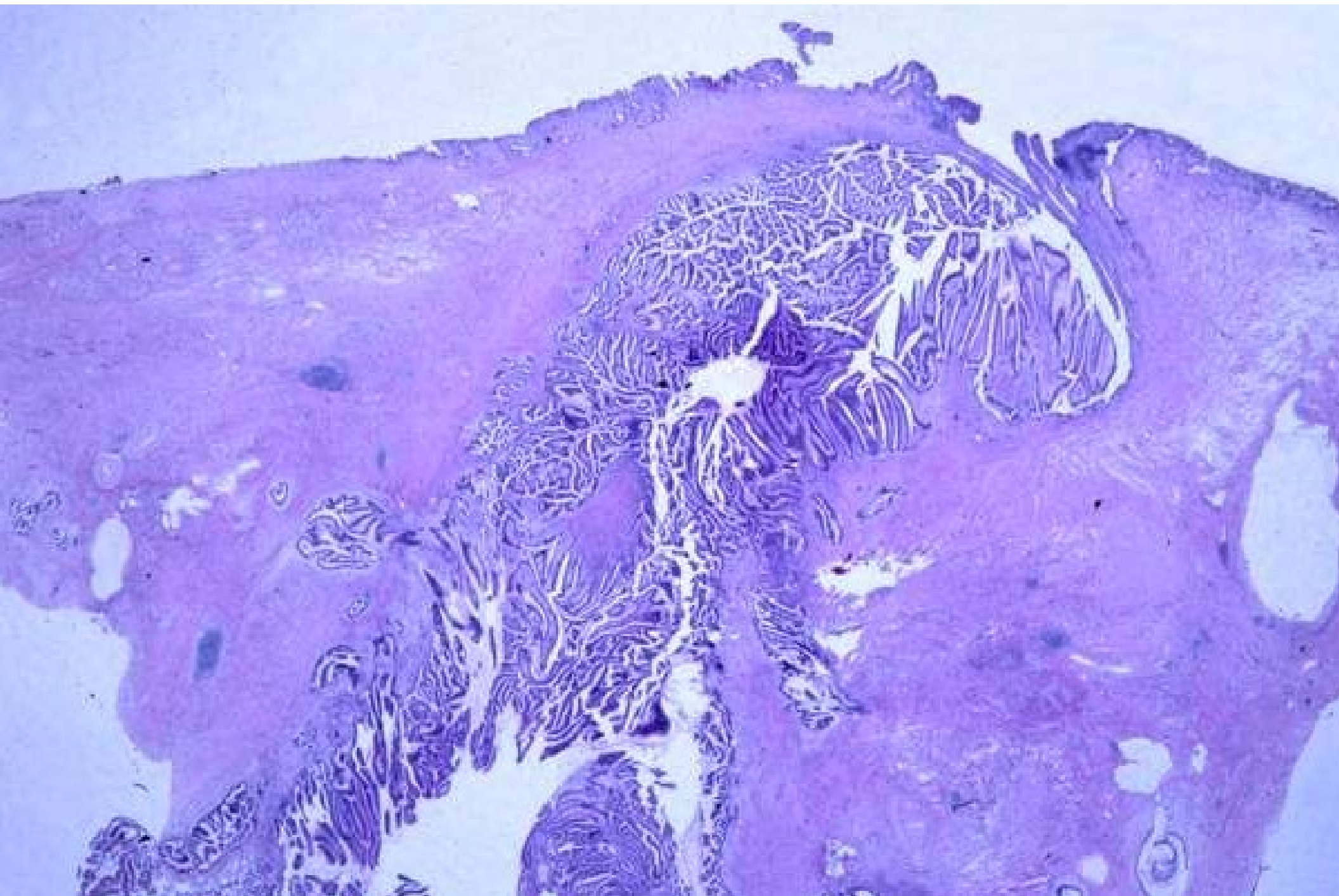


IPMNs involve
the ducts
histologically



A histological slide stained with hematoxylin and eosin (H&E) showing an Intraductal Papillary Mucinous Neoplasm (IPMN). The image displays a complex network of glandular structures with a papillary or villous appearance, characteristic of this type of pancreatic lesion. The glands are lined by a single layer of columnar epithelial cells with apical mucin production. The overall architecture is highly convoluted and branching, filling the ductal system. The surrounding stroma is composed of fibrous connective tissue.

**IPMNs
involve the
duct system**

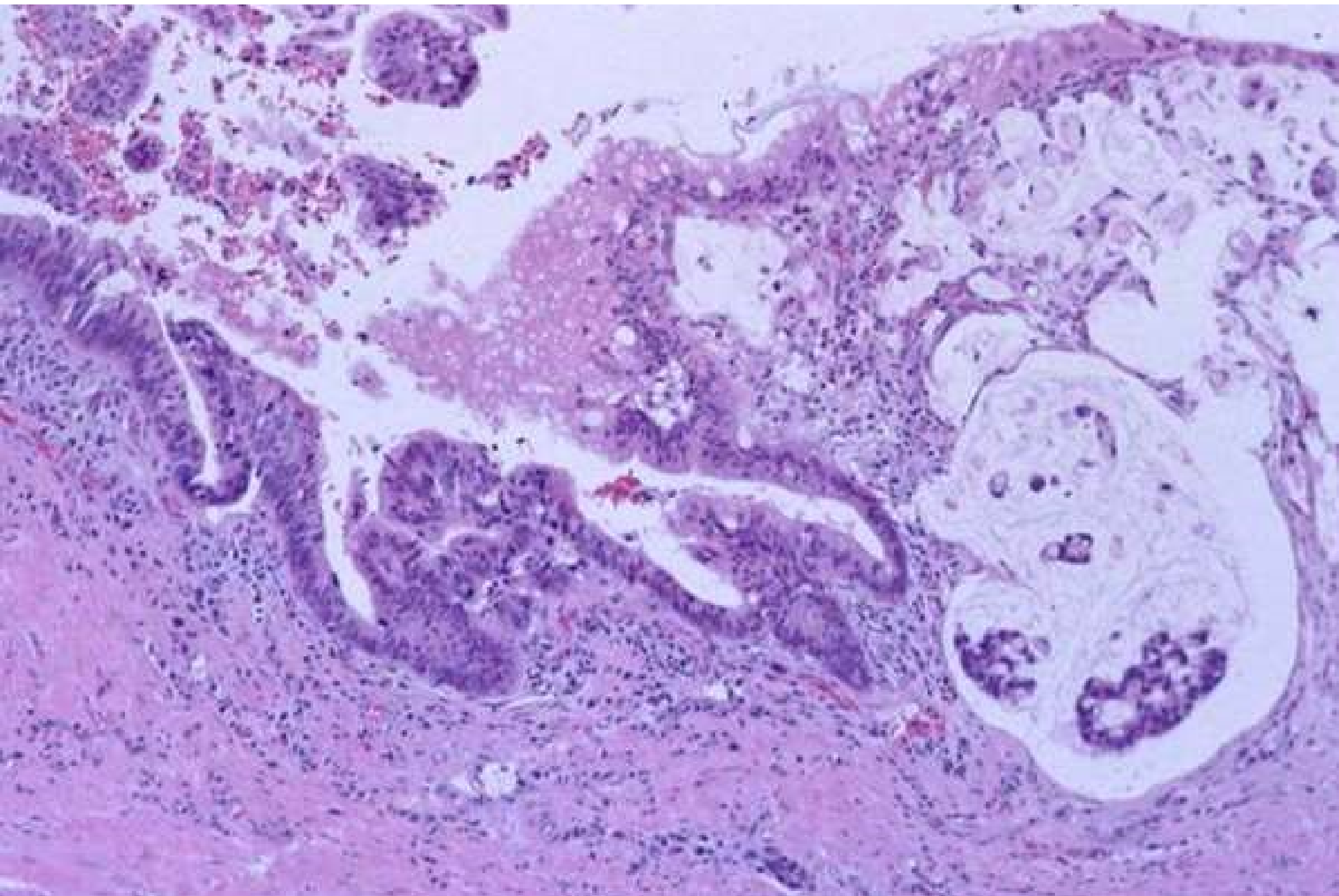


Intraductal Papillary Neoplasms

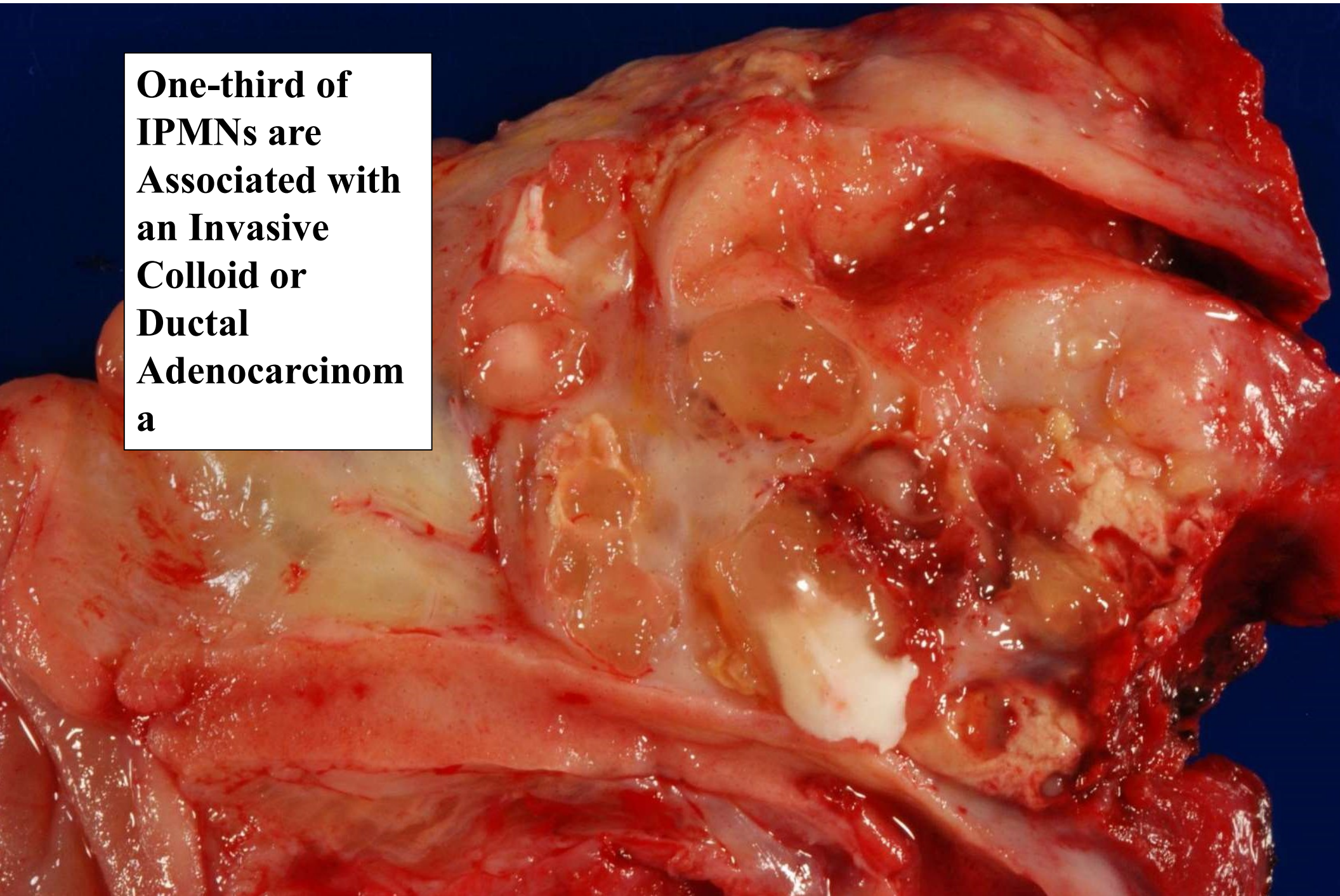
- IPMN with low-grade dysplasia
- IPMN with intermediate dysplasia
- IPMN with high-grade dysplasia
- IPMN with an invasive carcinoma
 - Colloid
 - Tubular/ductal

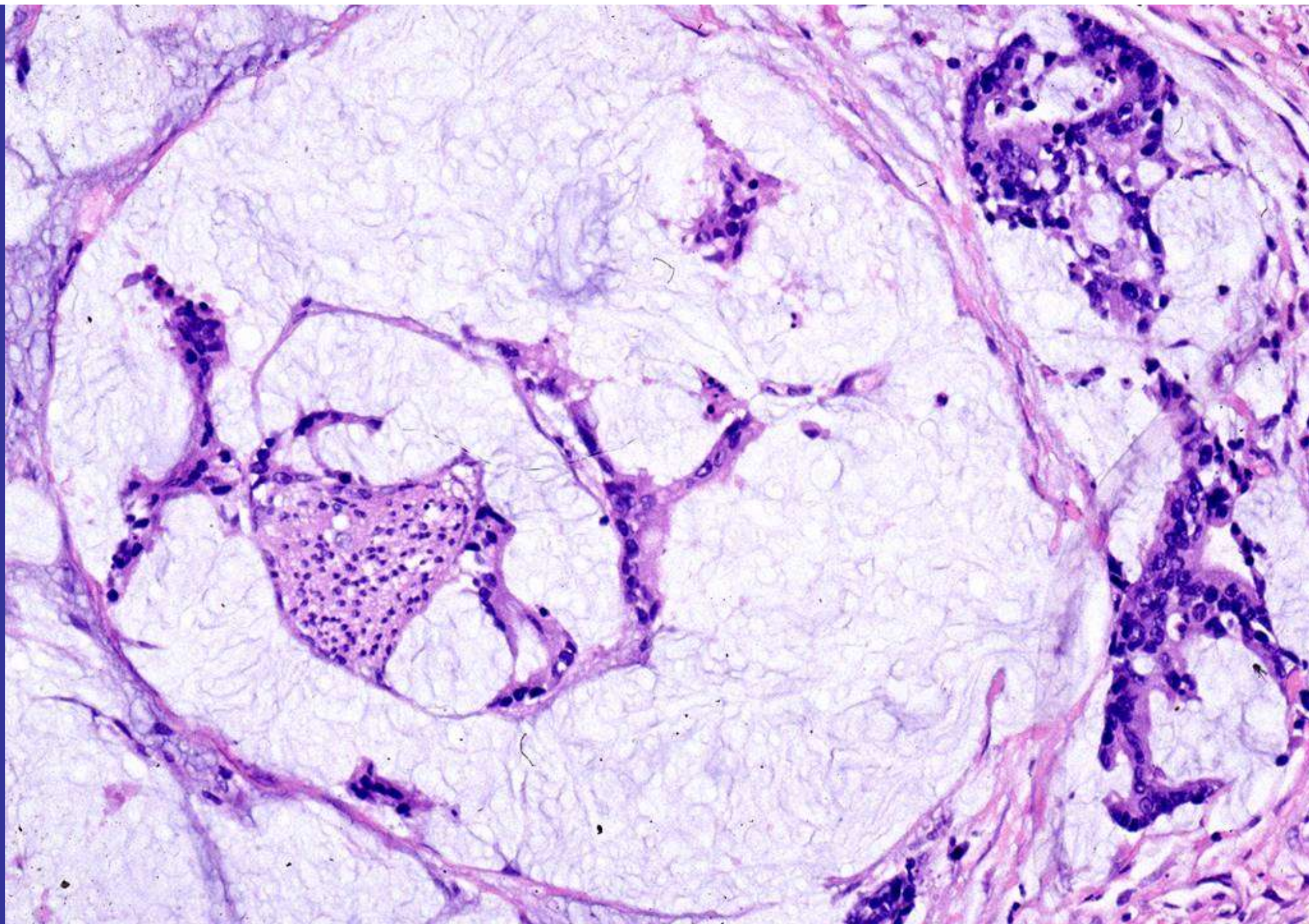
Intraductal Papillary Neoplasms Proposed

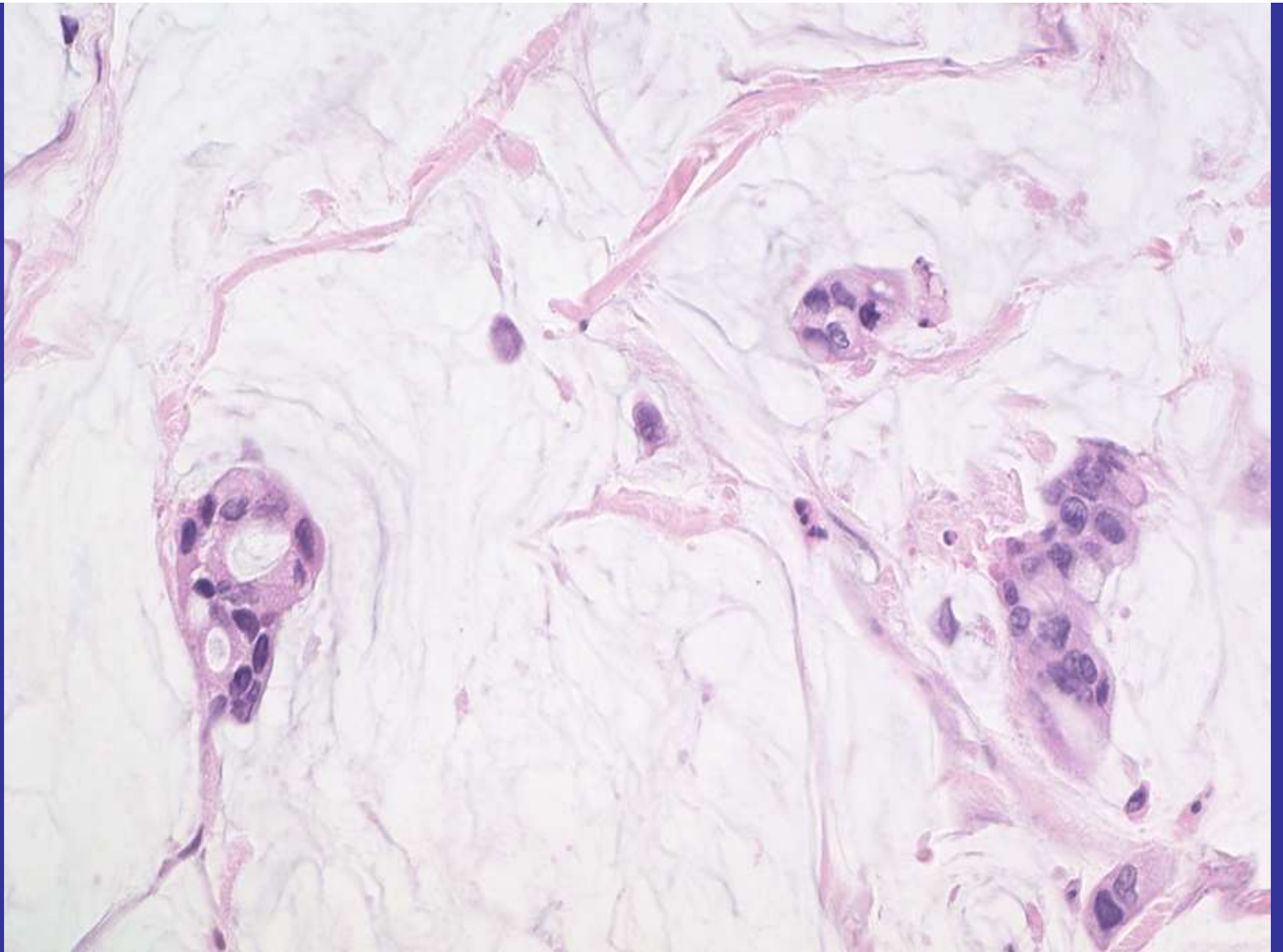
- IPMN with low-grade dysplasia
- IPMN with high-grade dysplasia
- IPMN with an invasive carcinoma
 - Colloid
 - Tubular/ductal



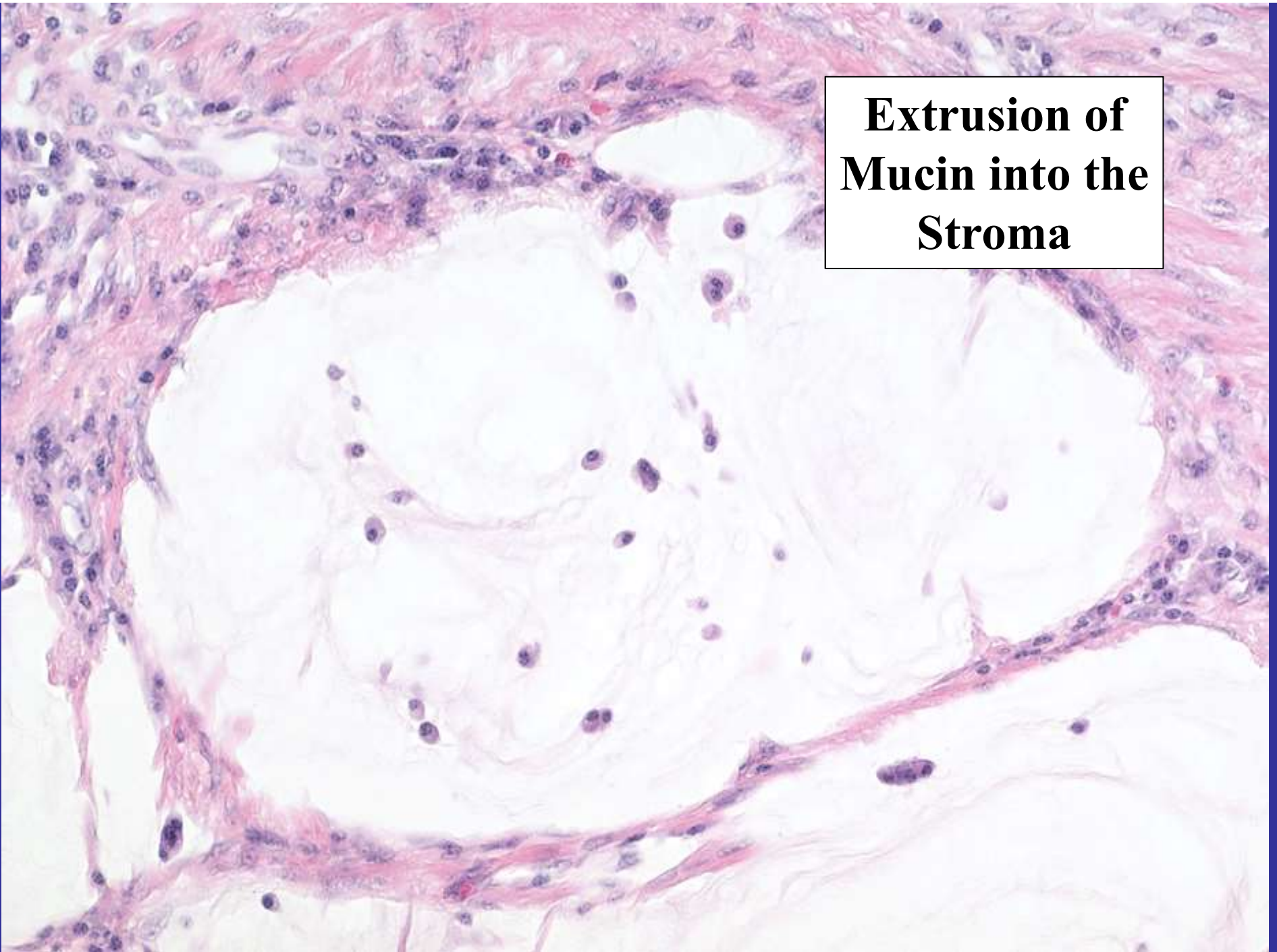
**One-third of
IPMNs are
Associated with
an Invasive
Colloid or
Ductal
Adenocarcinoma
a**



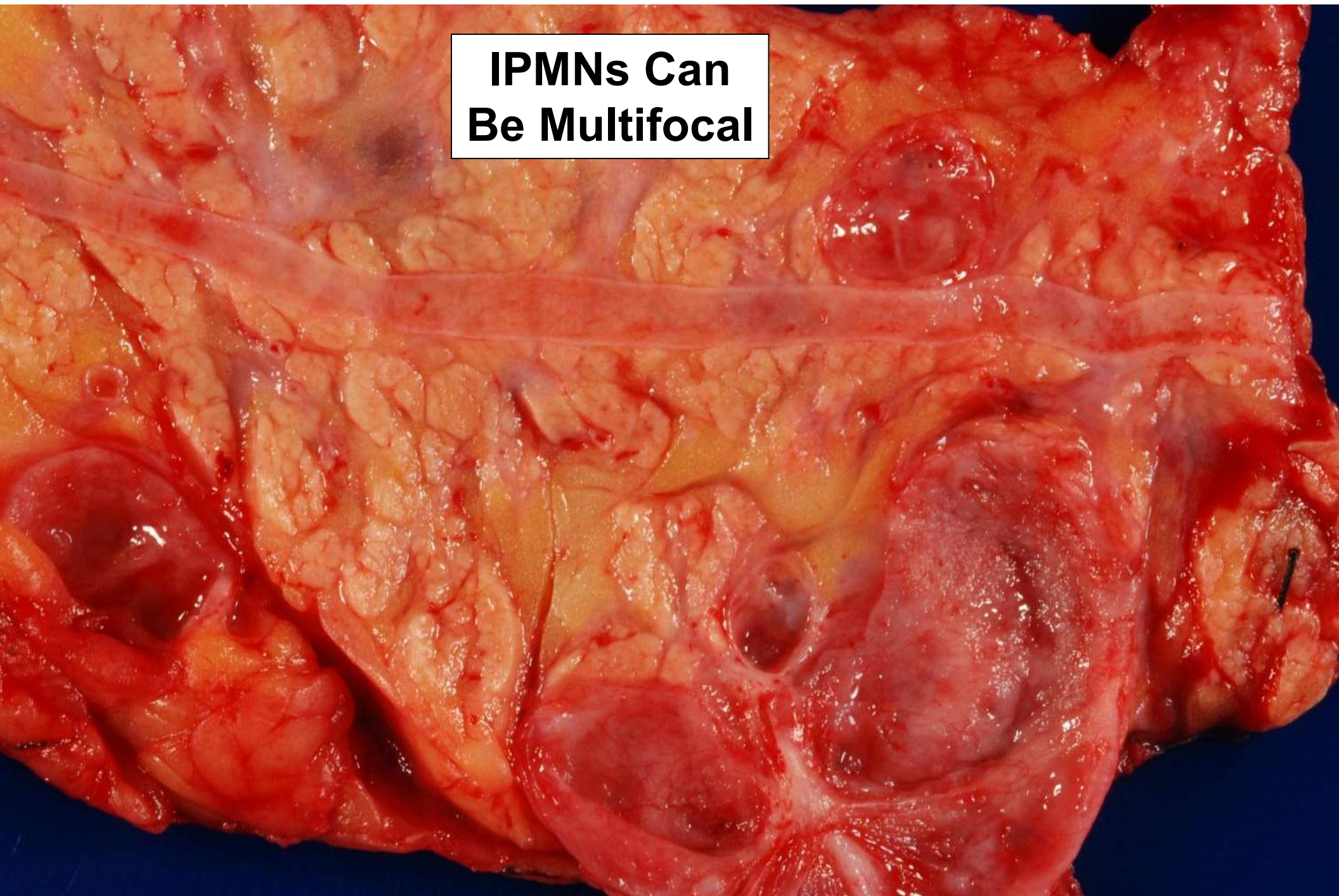




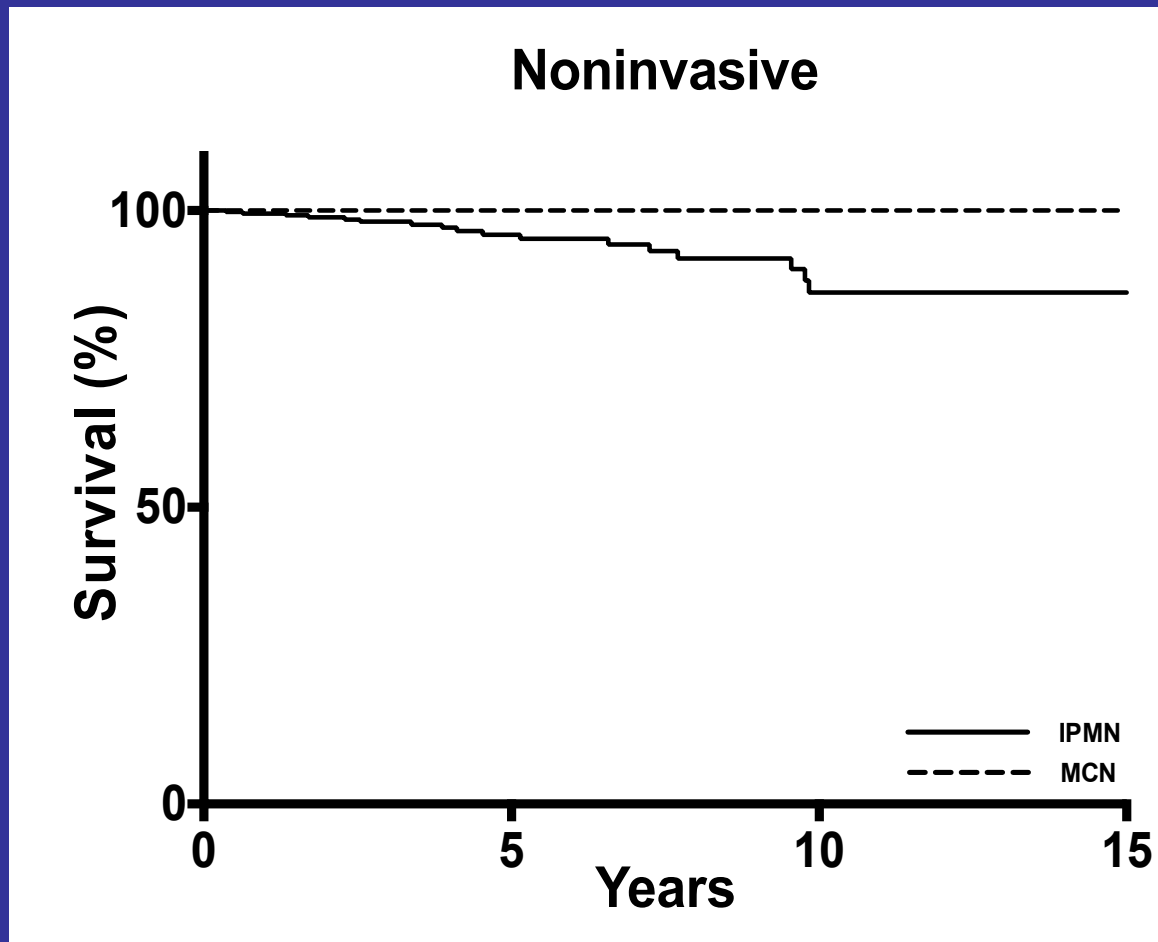
**Extrusion of
Mucin into the
Stroma**



**IPMNs Can
Be Multifocal**

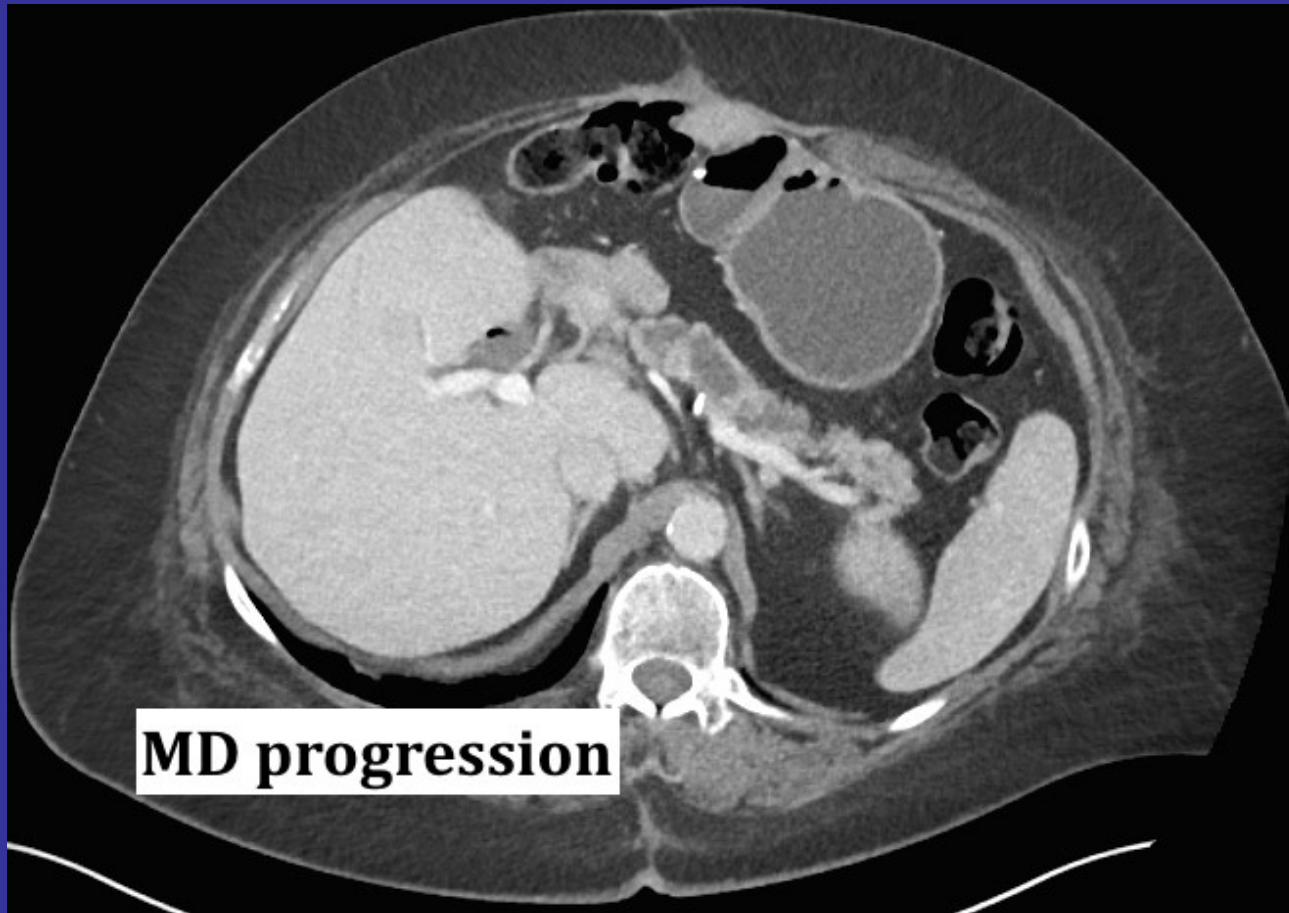

Multifocality is Clinically Important Kaplan-Meier Survival



A. Pea, Annals of
Surgery, 2016

Recurrence of Disease in the Remnant Pancreas is a Big Problem for Patients with an IPMN

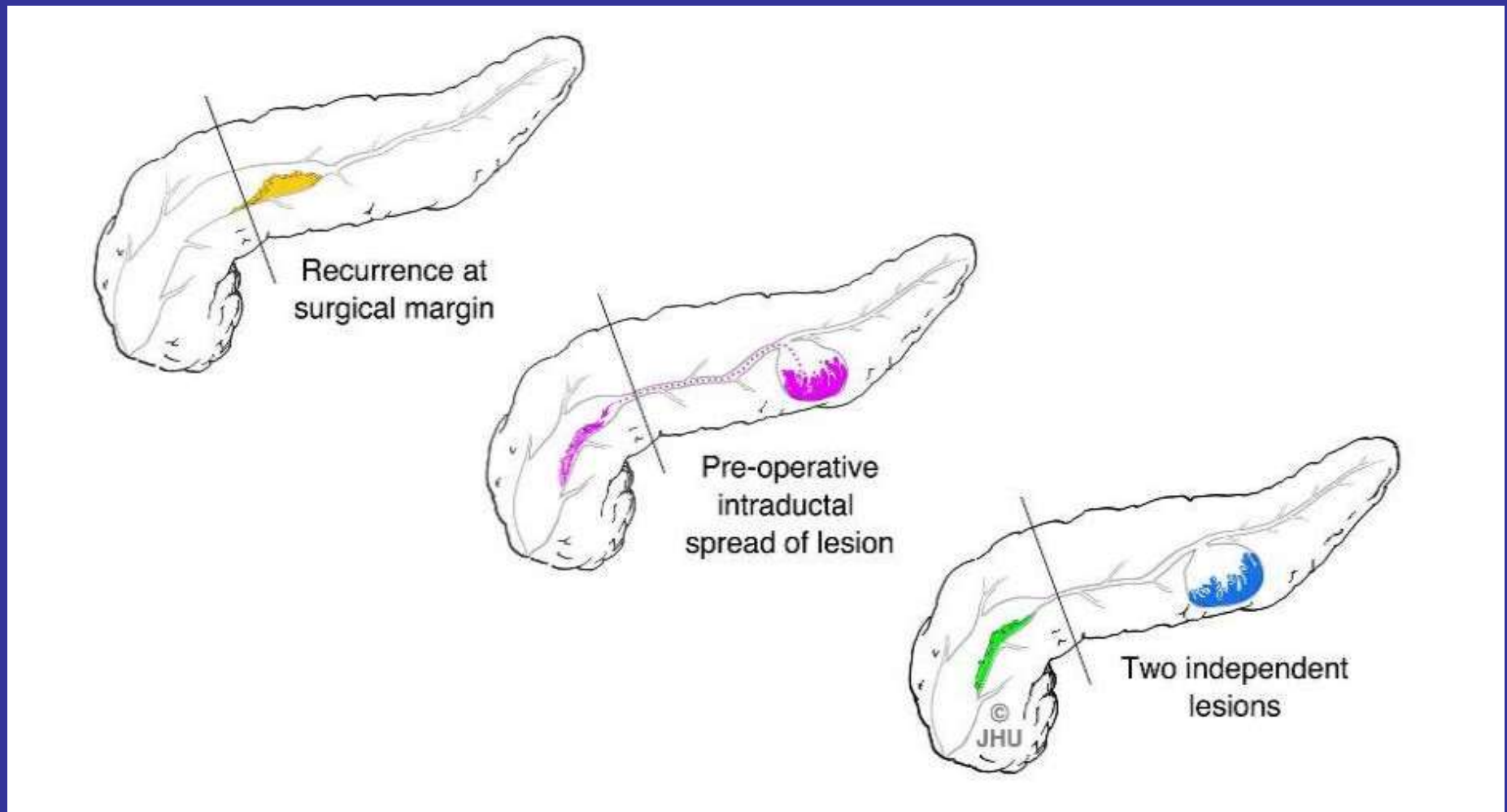


A. Pea, Annals of

Intraductal Papillary Mucinous Neoplasms

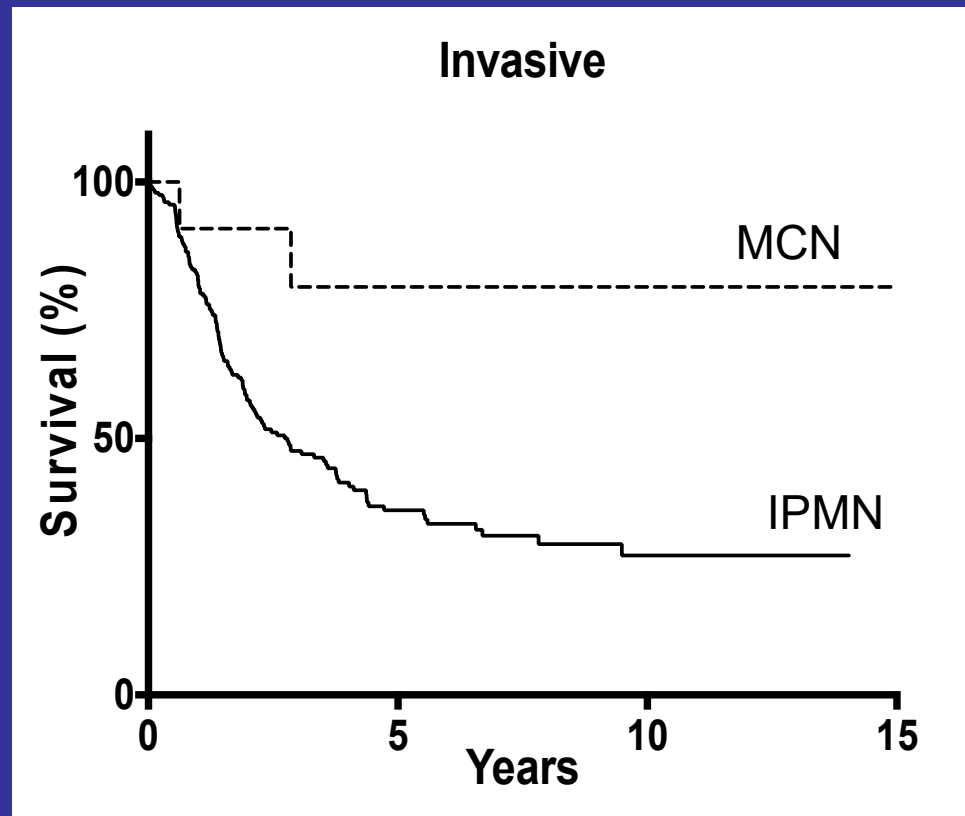
Surgically resected non-invasive IPMNs have a 90% 5-year survival rate. Most of the recurrences in patients with non-invasive IPMNs appear to be from multi-focal disease, because patients who undergo total pancreatectomy for a non-invasive IPMN have a close to 100% 5-year disease free survival

Clinical Implications



A. Pea, Annals of

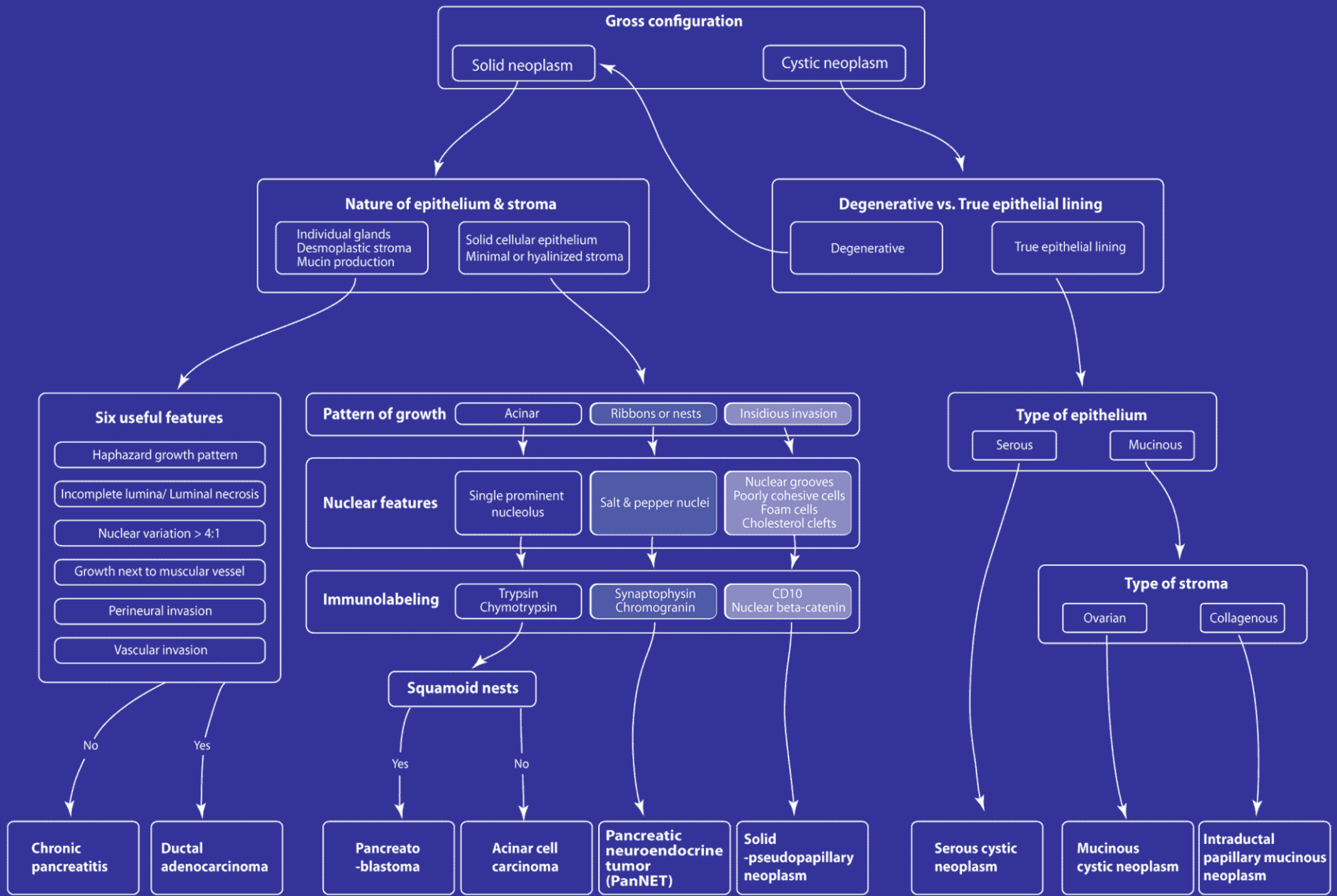
Invasive Carcinoma Arising in IPMN vs. MCN



A. Pea, Annals of
Surgery, 2016

| | Mucinous Cystic Neoplasm | Intraductal Papillary Mucinous Neoplasm |
|-----------------------------|--------------------------|---|
| Age | 40-50 years | 60's |
| Gender | Female>>male | Male>female |
| Head vs. body/tail | Body/tail | Head |
| Connectivity to large ducts | Usually not | Always |
| Cyst Contents | Mucoid | Mucoid |
| Mucin oozing from ampulla | No | Yes |
| Stroma | Ovarian-type | Collagen |
| Multifocal disease | Very rare | 20-30% |





Based on AFIP Fascicle, 4th Edition



The Johns Hopkins Atlas of Pancreatic Pathology

Introduction

Diagnoses Albums

Feature Albums

My Albums

Teaching Algorithm

Quiz Me

Flashcards

Introduction

Welcome to the Johns Hopkins Atlas of Pancreatic Pathology. This “app” is designed to teach residents, fellows, and practicing pathologists advanced pancreatic pathology.

The app is composed of three modules: an interactive teaching algorithm, a searchable image atlas, and an image-based quiz. Viewing multiple examples of the same entity or feature from this large, rich image atlas will strengthen your diagnostic skills.

Teaching Algorithm. The teaching algorithm is a tool to aid in the diagnosis of the most common neoplasms of the pancreas. The algorithm consists of a series of usually dichotomous decision points, starting with determining if the tumor is solid or cystic, which end in specific diagnoses. Gross and microscopic photographs, together with didactic illustrations created by medical illustrator Bona Kim, support the instructional design of the algorithm. The algorithm was adapted with permission from R.H. Hruban, M.B. Pitman, and D.S. Klimstra, *Tumors of the Pancreas*. Washington, D.C.: American Registry of Pathology; 2007.



The Johns Hopkins Atlas of Pancreatic Cytopathology

Introduction

Diagnoses Albums

Feature Albums

My Albums

Teaching Algorithm

Quiz Me

Flashcards

Flashcards

Use your custom albums as flashcard decks and quiz yourself.



Launch Flashcard Module

Table of Contents

Invasive ductal adenocarcinoma

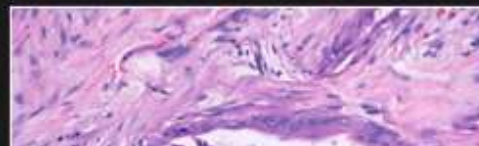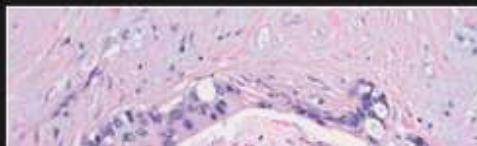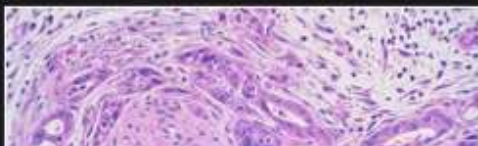
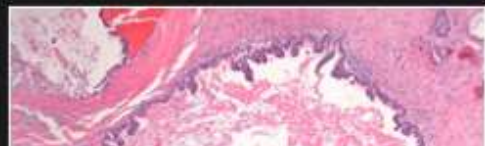
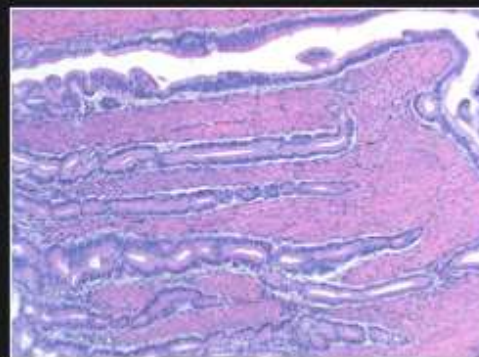
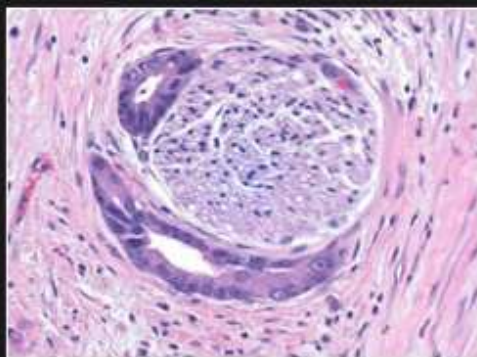
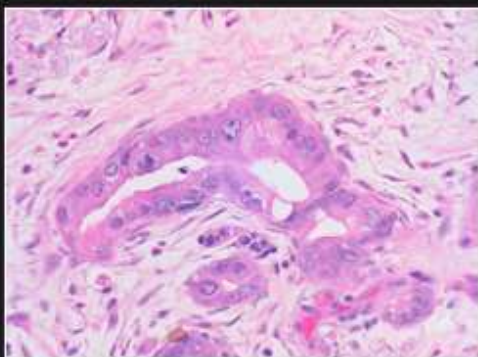
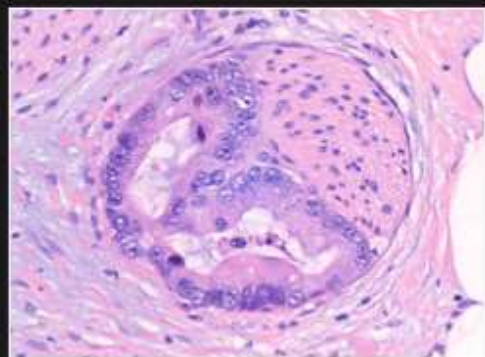
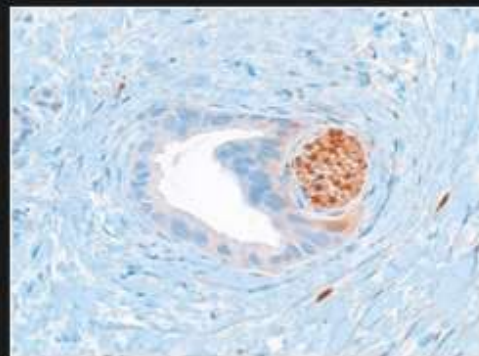
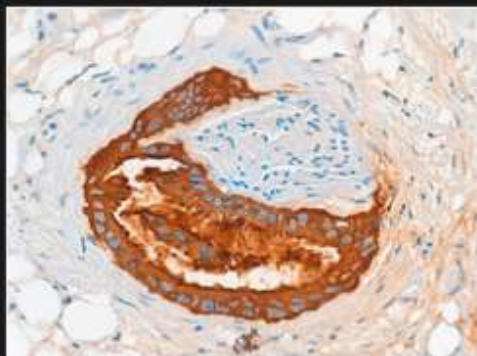
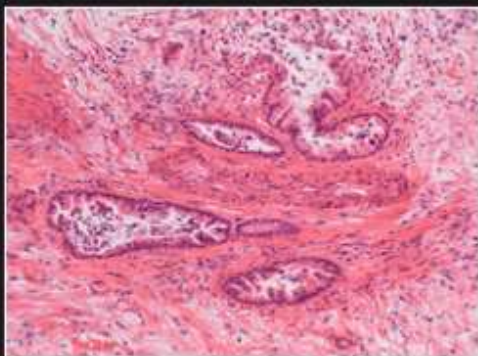
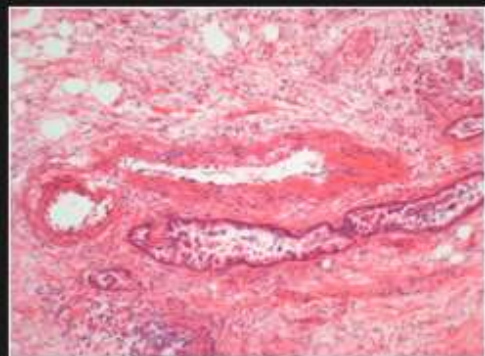
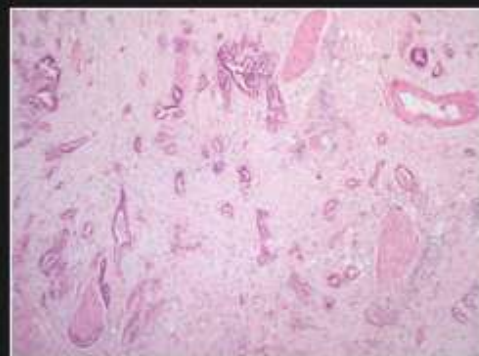
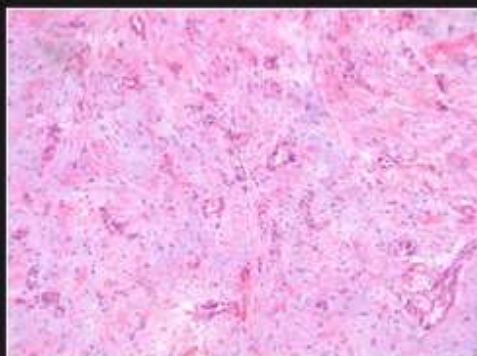
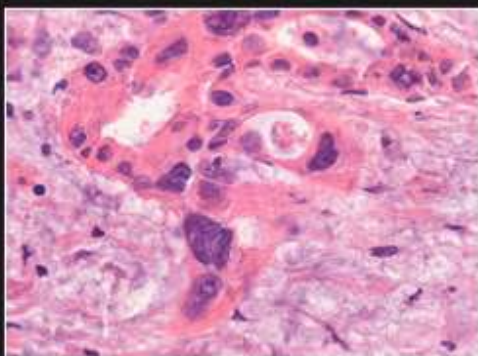
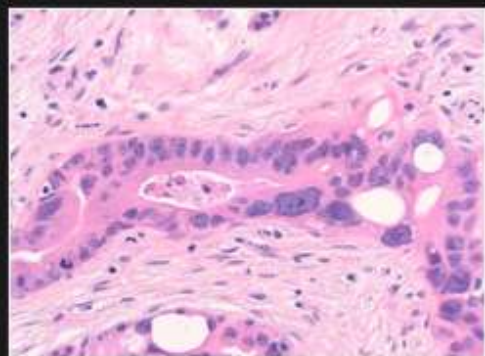
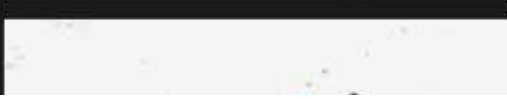
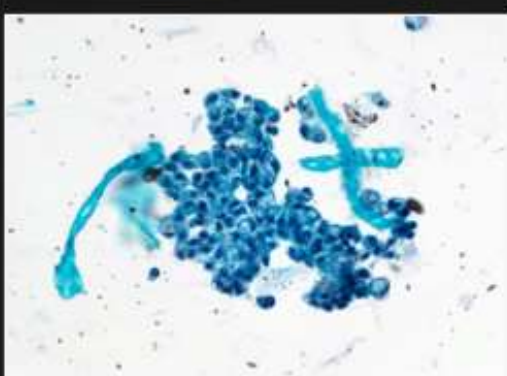
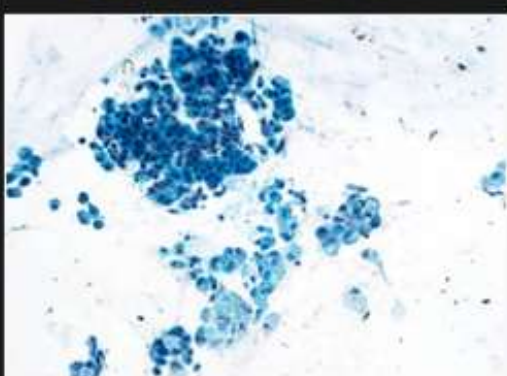
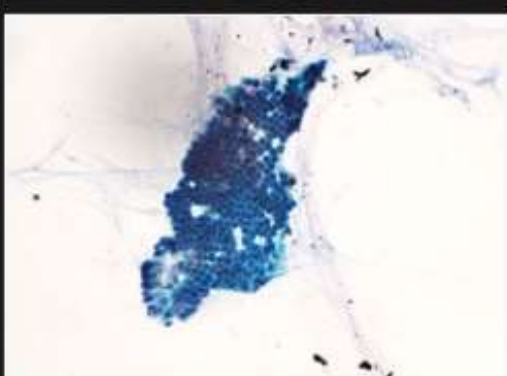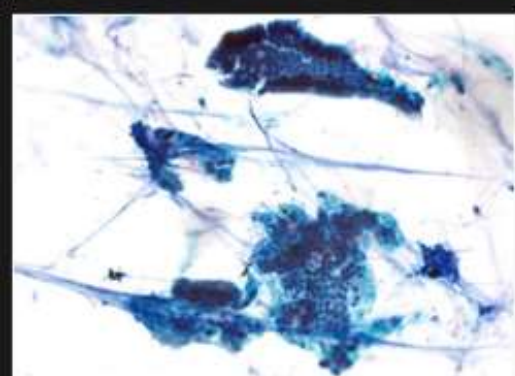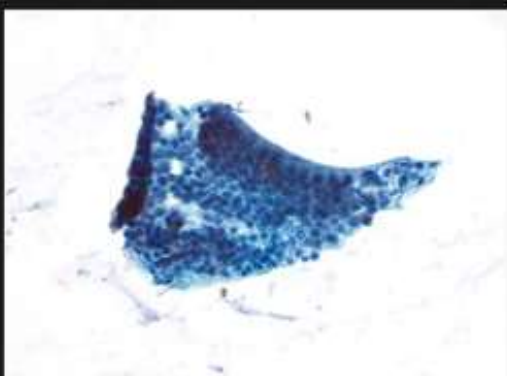
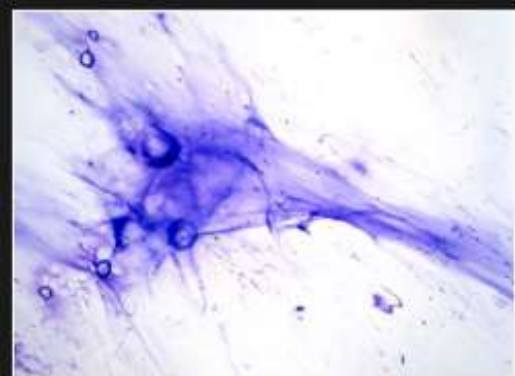
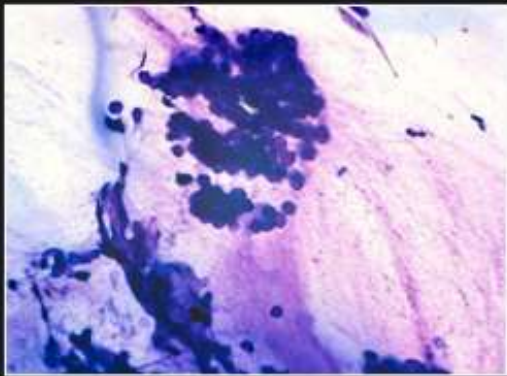
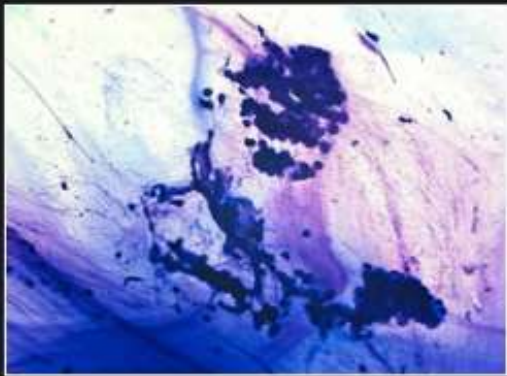
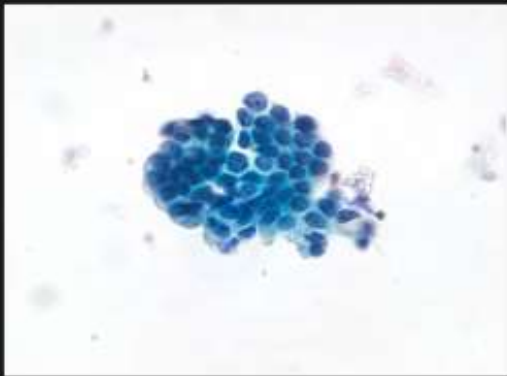
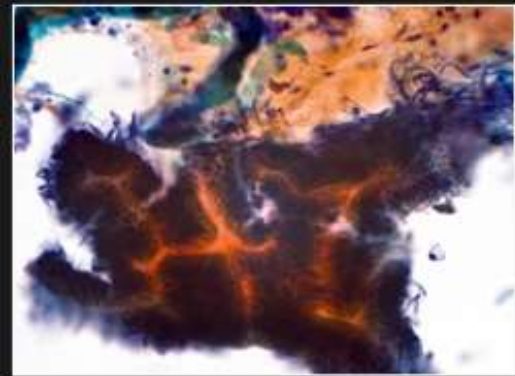
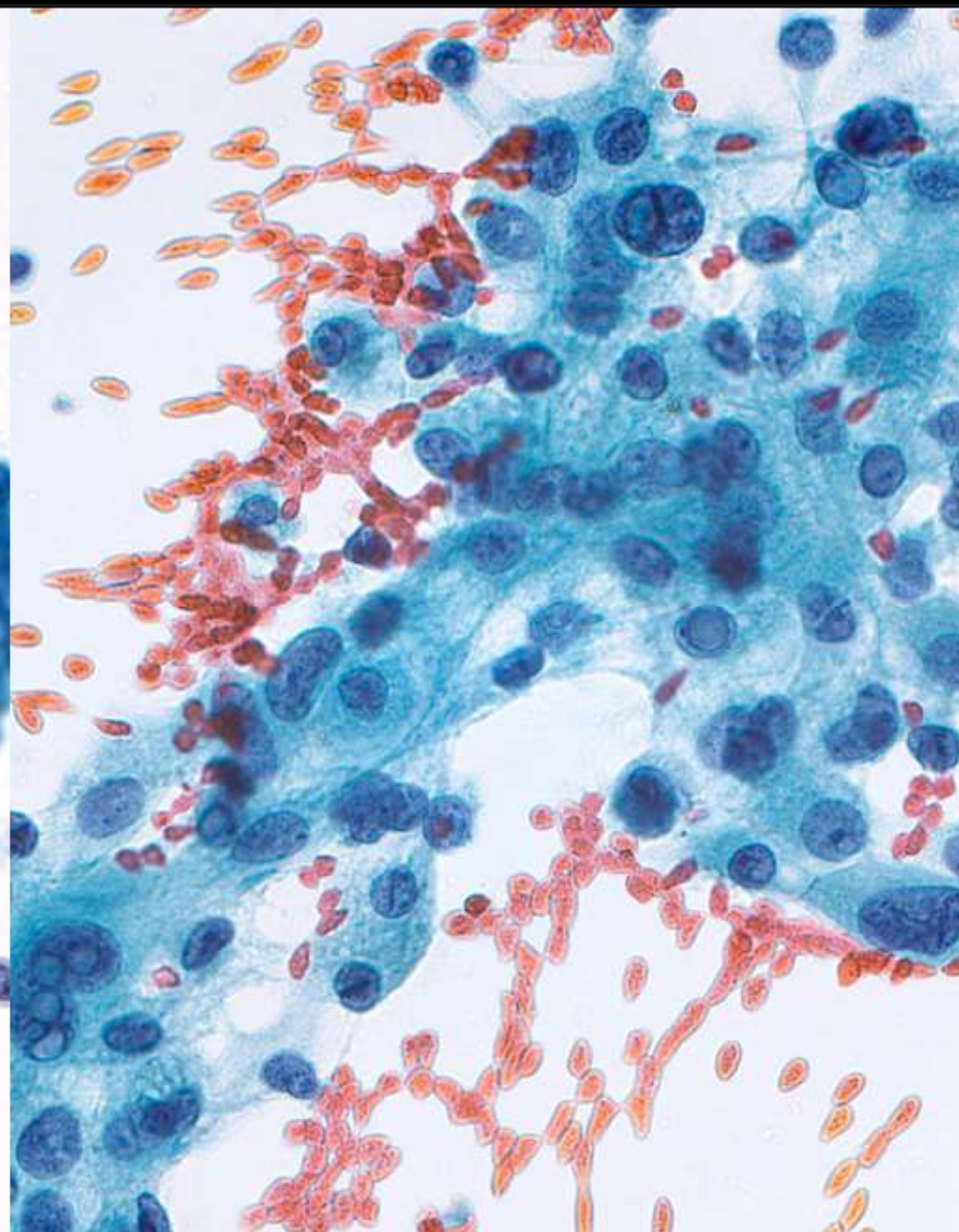
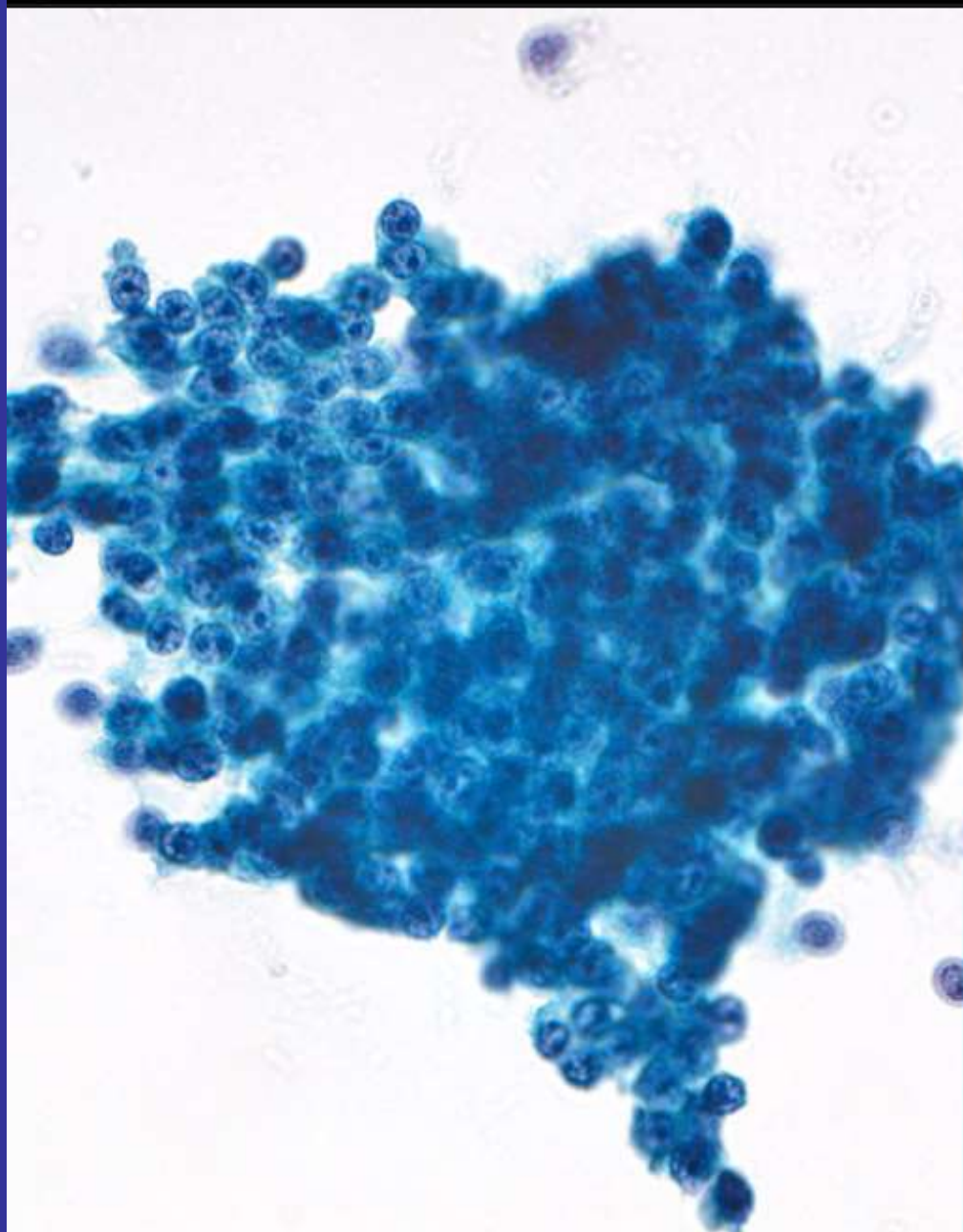


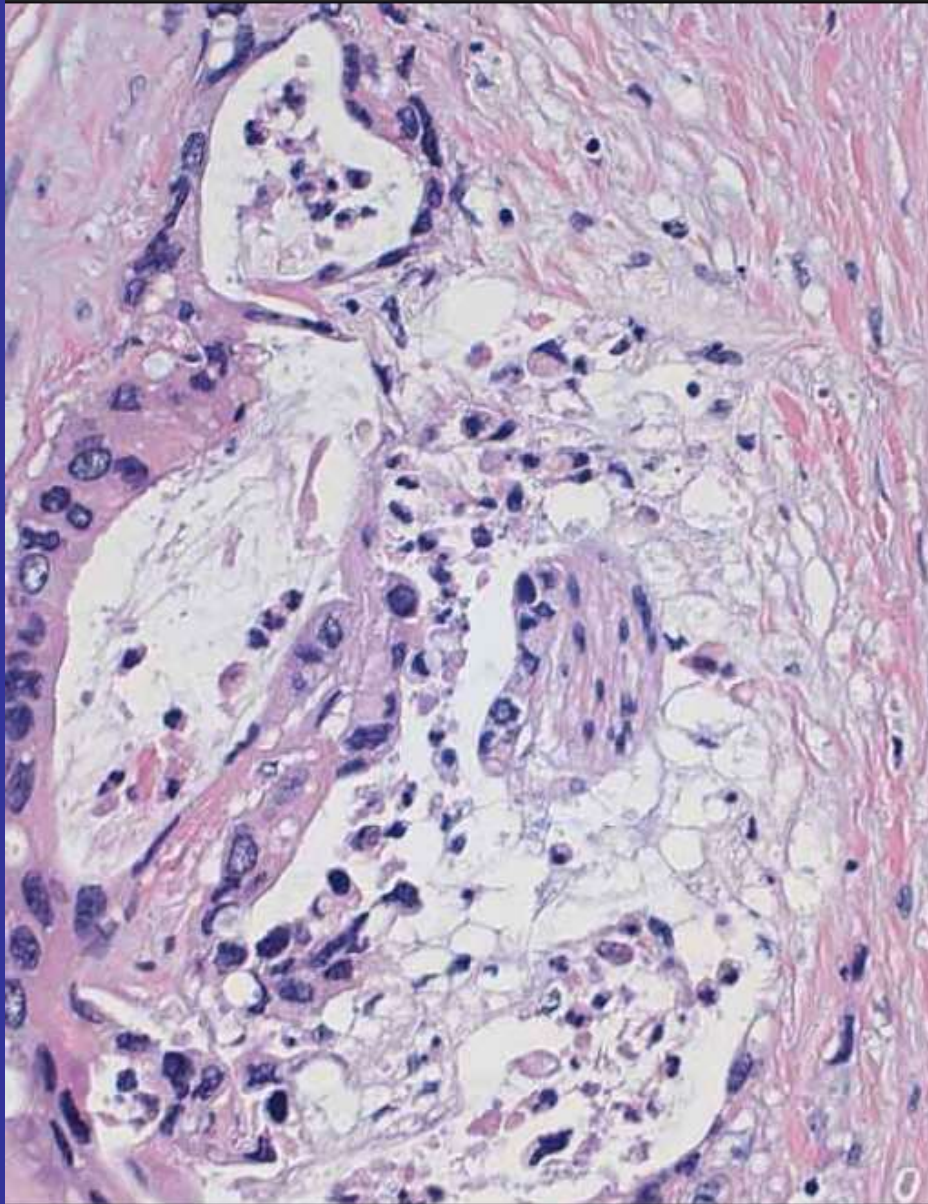
Table of Contents

Intraductal papillary mucinous neoplasm

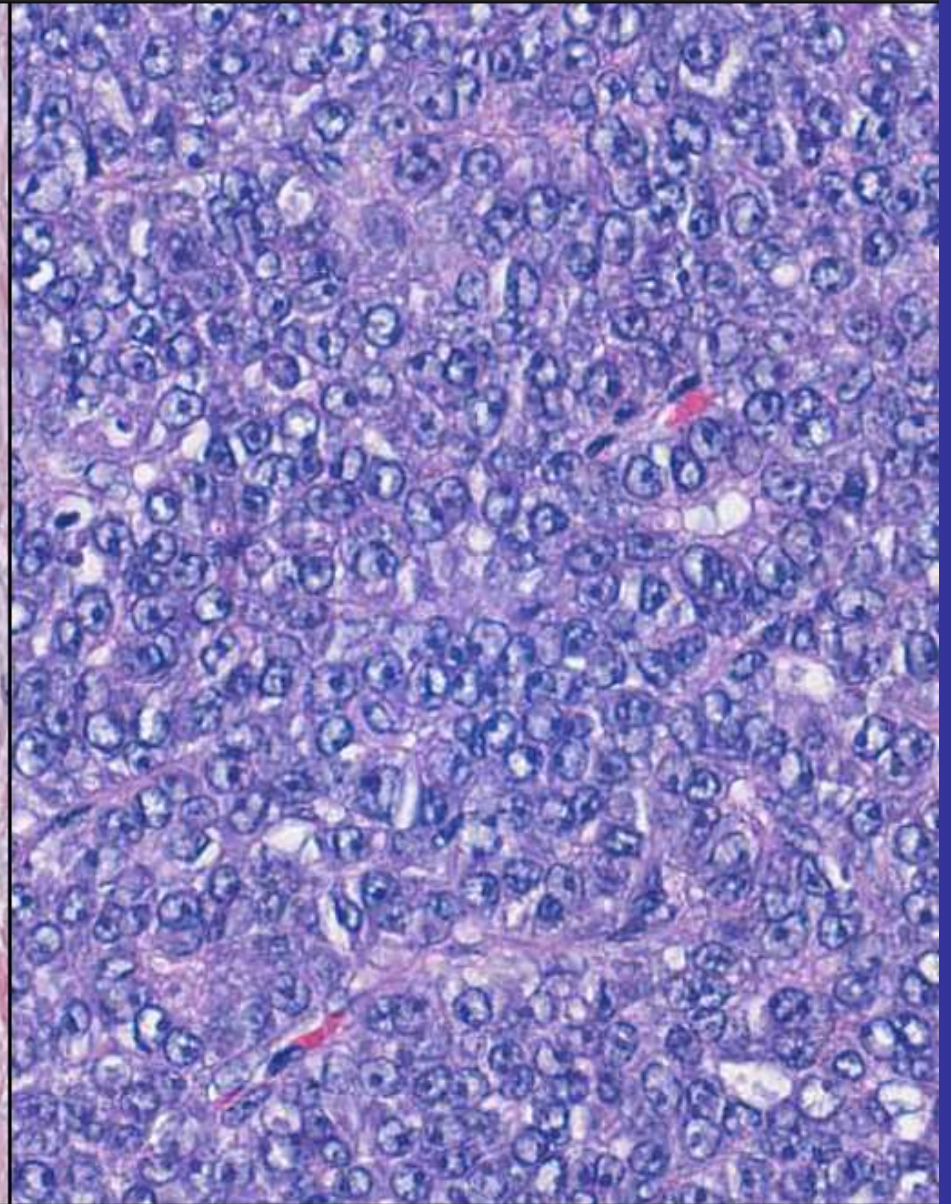


Comparing Albums





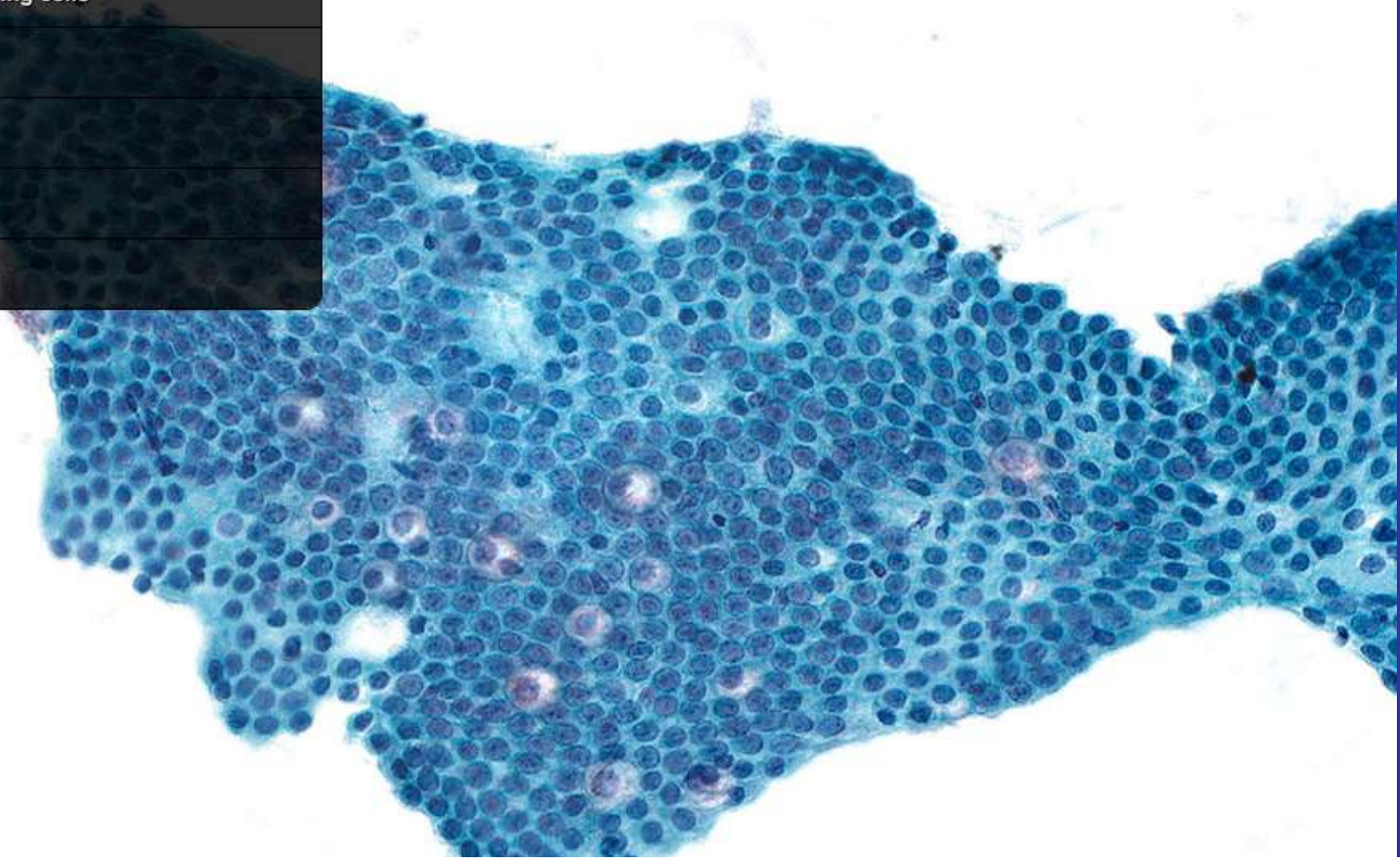
Hypocellular with mucin (1 of 12)



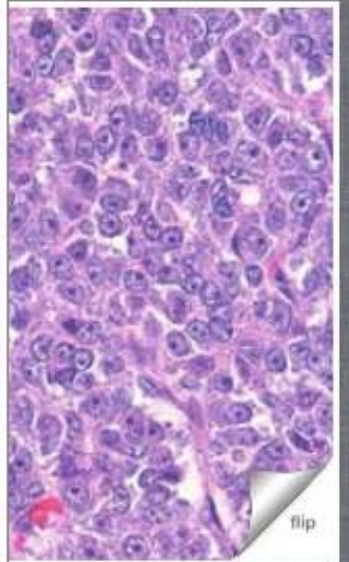
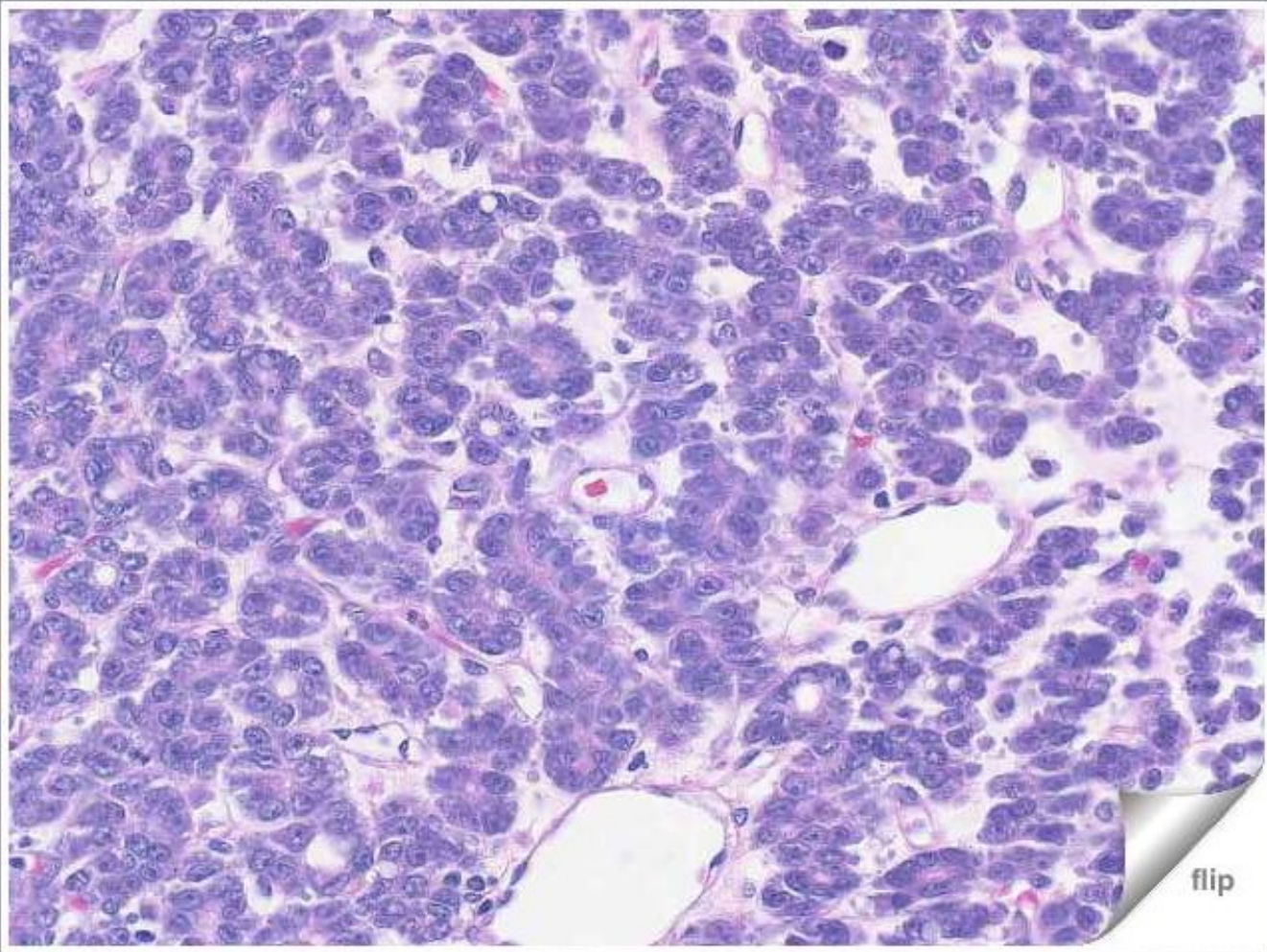
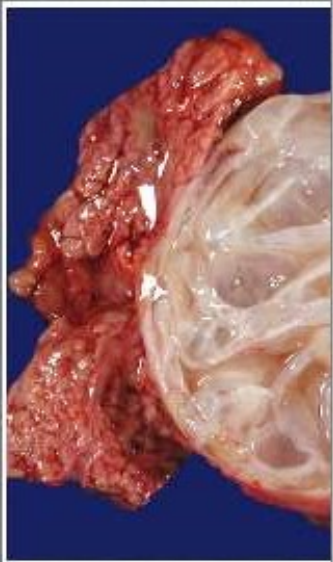Cellular minimal stroma (1 of 16)

The light pink areas shown here represent:

- Malignant signet ring cells
- Islet cells
- Goblet cells
- Fat vacuoles
- Artifact



Stain: Hematoxylin and eosin



Card 2 of 6
(0 removed)

Follow us on Twitter- @Hopkins_GI_Path

